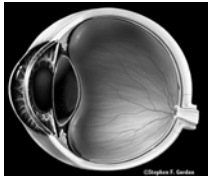

## Ocular Anatomy & Physiology: Getting Down to the Basics



Kristin C. Bains, M.D.  
October 24, 2009

---

---

---

---

---

---

---

---

## The Bony Orbit

- The “eye socket”
- Offers protection for the globe
- Comprised of 7 bones
  - Frontal
  - Zygomatic
  - Maxillary
  - Ethmoid
  - Sphenoid
  - Lacrimal
  - Palatine

---

---

---

---

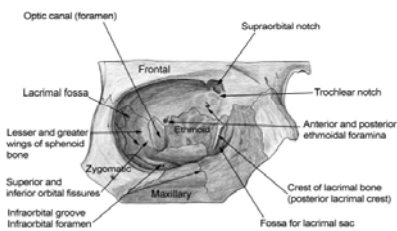
---

---

---

---

## The Bony Orbit



---

---

---

---

---

---

---

---

### The Bony Orbit

- Globe takes up 1/5 volume of orbit
- Also present in the orbit:
  - Extraocular muscles
  - Fascia
  - Orbital fat
  - Blood vessels
  - Nerves
  - Lacrimal gland

---

---

---

---

---

---

---

---

### Orbital Compartment Syndrome

- Can lead to vision loss within minutes
- Mechanical tamponade, CRAO, Optic nerve compression

---

---

---

---

---

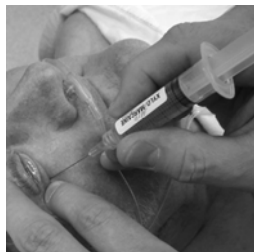---

---

---

### Orbital Compartment Syndrome

- Retrobulbar Hemorrhage
  - Intraoperatively from RBB
  - Secondary to trauma



---

---

---

---

---

---

---

---

### Extraocular Muscles

- 6 muscles
  - Medial rectus: moves eye in toward nose (adduction)
  - Lateral rectus: moves eye out away from nose (abduction)
  - Superior rectus: moves eye up, in, intorts
  - Inferior rectus: moves eye down, in, extorts
  - Superior oblique: intorts, moves eye down
  - Inferior oblique: extorts, moves eye up

---

---

---

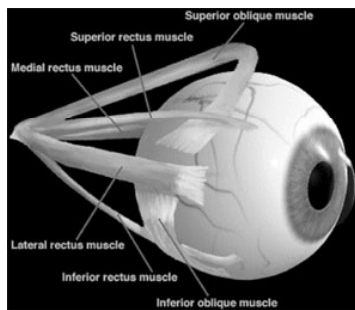
---

---

---

---

### Extraocular Muscles



---

---

---

---

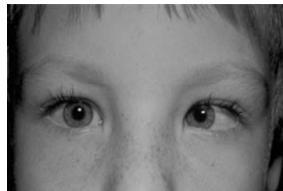---

---

---

### Extraocular Muscles

- Responsible for eye movements
- Maintain binocularity
- Misalignment = Strabismus
  - Esotropia
  - Exotropia
  - Hypertropia



Esotropia

---

---

---

---

---

---

---

## Eyelids

- Protect and cover the eyes
- Spread tear film across the cornea with blinking
- Blinking occurs approx. 5 times/minute
- Upper eyelid: upper lash line to eyebrow
- Lower eyelid: lower lash line to upper cheek

---

---

---

---

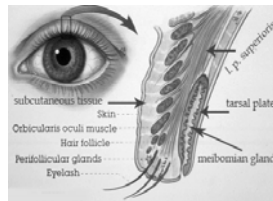
---

---

---

## Eyelids

- 8 layers
  - Skin
  - Orbicularis
  - Orbital septum
  - Orbital fat
  - Tarsus
  - Levator
  - Muller's muscle
  - Conjunctiva



---

---

---

---

---

---

---

## Eyelids

- Levator palpebrae superioris raises lid
- Levator innervated by Oculomotor nerve (CN III)
- Orbicularis oculi closes lids
- Orbicularis innervated by Facial nerve (CN VII)
- Ptosis- CN III palsy
- Bell's palsy- CN VII palsy

---

---

---

---

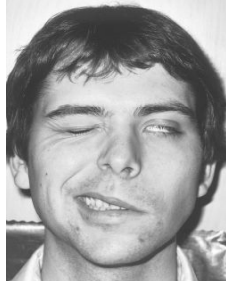
---

---

---

## Facial Nerve Palsy

- CN VII palsy
- Lagophthalmos
- Multiple causes
- Bell's palsy = idiopathic



---

---

---

---

---

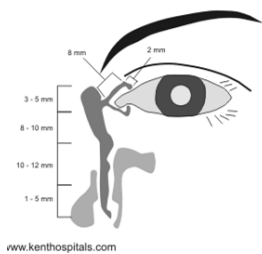
---

---

---

## Tear Production and Drainage

- Lacrimal gland:
  - Located superotemporal aspect of orbit
  - Produces aqueous component of tears
- Tears drain medially at the upper and lower punta, superior and inferior canaliculi, common canaliculus, lacrimal sac, nasolacrimal duct into nose



---

---

---

---

---

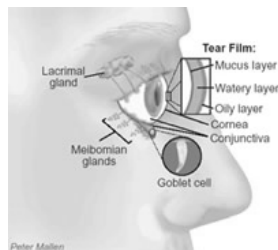
---

---

---

## Tear Film

- 3 components:
  - Lipid: from meibomian glands
  - Aqueous: from lacrimal gland
  - Mucin: from goblet cells of conjunctiva



---

---

---

---

---

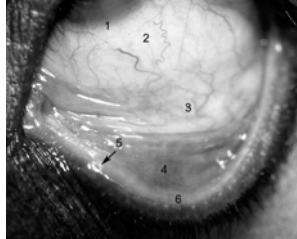
---

---

---

## Conjunctiva

- Mucous membrane lining the upper and lower eyelids
- Extends over sclera to corneal margin
- Goblet cells produce mucous
- Accessory lacrimal glands
- Meibomian glands
- Glands of Moll and Zeiss



---

---

---

---

---

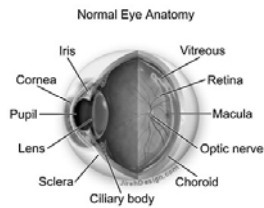
---

---

---

## Cornea

- Approx. 12 mm in diameter
- Most of eye's refractive power
- Clear, avascular
- Receives most of nutrition through tear film
- Healthy state cornea is dehydrated, maintained by endothelium



---

---

---

---

---

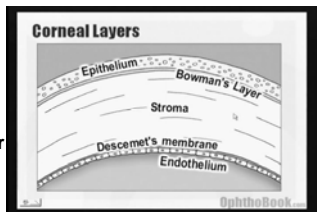
---

---

---

## Cornea

- 5 layers
  - Epithelium
  - Bowman's Layer
  - Stroma
  - Descemet's Membrane
  - Endothelium



---

---

---

---

---

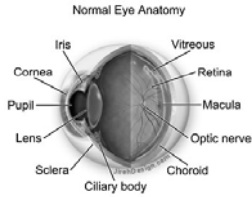
---

---

---

## Anterior Chamber

- Comprised of aqueous humor
  - Produced by ciliary body
  - Maintains intraocular pressure
  - Nourishes corneal endothelium and lens
  - Drains through trabecular meshwork, Sclemm's canal, to episcleral veins



---

---

---

---

---

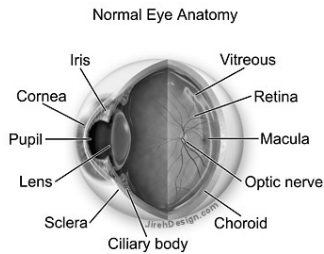
---

---

---

## Uveal Tract

- Iris
- Ciliary Body
- Choroid



---

---

---

---

---

---

---

---

## Iris

- Colored part of eye
- Center opening = pupil
- Sphincter pupillae- constriction
  - parasympathetic
- Dilator pupillae- dilation
  - sympathetic

---

---

---

---

---

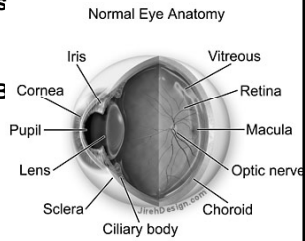
---

---

---

## Ciliary Body

- Continuous with iris
- Ciliary processes arise from here
- Zonules connect CE to lens
  - Zonular dehiscence post trauma
- Ciliary muscles- accommodation



---

---

---

---

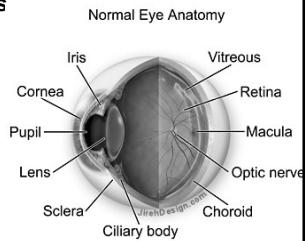
---

---

---

## Choroid

- Continuous with iris and ciliary body
- Vascular structure
- Nourishes retina



---

---

---

---

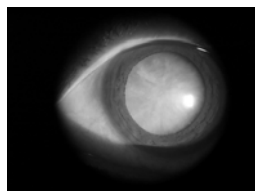
---

---

---

## Lens

- Approx 4mm thick
- Enclosed in a capsule
- Cortex
- Nucleus
- Nucleus adds layers, hardens with age
- Cataract



Mature cataract

---

---

---

---

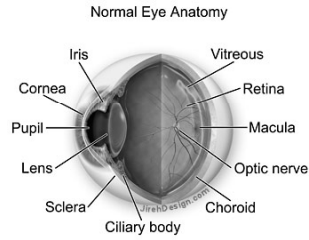
---

---

---

## Vitreous

- **Thick gel**
- **99% water, 1% collagen, hyaluronic acid**
- **Shapes eye**
- **Avascular**




---

---

---

---

---

---

---

---

## Retina

- **Inner layer of posterior segment**
- **Inner aspect nourished by central retinal artery**
- **Outer aspect nourished by choroid**
- **Contains photoreceptors**
  - Rods- none in macula
  - Cones- more in macula lutea, fovea

---

---

---

---

---

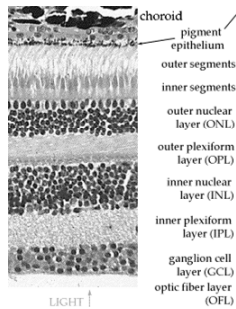
---

---

---

## Retina

- **9 layers**
  - ILM
  - Nerve fiber layer
  - Ganglion cell
  - IPL
  - INL
  - OPL
  - ONL
  - ELM
  - Photoreceptors
- **Retinal pigment epithelium**




---

---

---

---

---

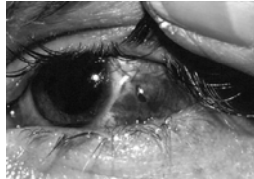
---

---

---

## Sclera

- Opaque
- Supportive structure
- Thinnest where muscles insert
  - Common rupture site



Scleral laceration

---

---

---

---

---

---

---

---

## Optic Nerve

- Transmits information from retina to brain
- One million nerve axons
- Corresponds to blind spot
- CN II

---

---

---

---

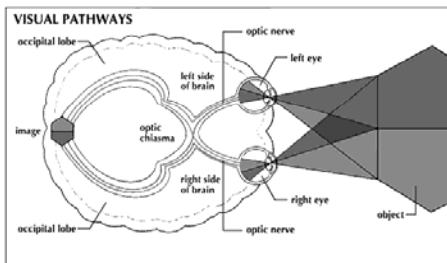
---

---

---

---

## Visual Pathways



---

---

---

---

---

---

---

---