

Multidisciplinary Treatment of Thyroid Orbitopathy

Don O. Kikkawa, M.D.

Chief, Division of Oculoplastics

UCSD Department of Ophthalmology

La Jolla, California

Which of the following is associated with Graves Disease?

- A. Female Gender
- B. Smoking
- C. Living in the Vice-President's Residence

Epidemiology - Graves

Female Gender

- Almost a 6:1 ratio
- Most autoimmune diseases show same predilection

Epidemiology - Graves
Smoking

- Causes a worsening of disease, but not typically causal

Epidemiology - Graves

- Living in the Vice-President's residence

1997

- UCSD Thyroid Eye Center

Orbit and Eyelid Specialist
Strabismus Specialist
Neuro-ophthalmologist
Endocrinology Fellows

Multidisciplinary approach

- Improves care via
 - Improved communication
 - Coordinated care
 - Easier for patient
 - Research

History

- First described by Caleb Hillier Parry, an English physician in the late 1700's. Noted an association between goiter, rapid heart rate, and cardiovascular involvement

History

- Robert James Graves, an Irish physician in 1830's noted eye involvement.

History

- Karl Adolph von Basedow, a German physician further characterized the disease, weight loss, nervousness.

Nomenclature

- Graves Eye Disease
- Graves Orbitopathy
- Graves Ophthalmopathy
- Basedow's Syndrome (Europe)
- Thyroid Eye Disease
- Thyroid Related Orbitopathy
- Thyroid Associated Ophthalmopathy

Thyroid Orbitopathy - Signs

- Eyelid retraction
- Exophthalmos
- Dry eye
- EOM Enlargement
- Optic nerve Dysfunction

Time Course – Rundle's
Curve

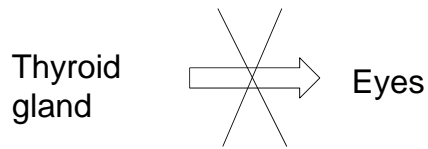
Thyroid Eye Disease
Clinical Spectrum of
Disease

- Type I - fat infiltration

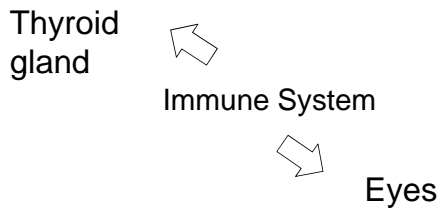
Thyroid Eye Disease
Clinical Spectrum of Disease

- Type II - extraocular muscle involvement

What Thyroid Eye Disease is not



Simplified Pathophysiology



Complex Pathophysiology

Eye Involvement

- 10-20% Precede Hyperthyroid
- 40% Concurrent
- 30% < 6 months after Dx
- 10-20% > 6 months after Dx

Overall Approach

- 5 Step Plan
 - 1- Medical Treatment
 - 2- Botox / Prism if needed
 - 3- Orbit (unless Neuropathy)
 - 4- Strabismus Repair
 - 5- Lid Repair

TRO Medical Management

- Lubricants
- Botulinum toxin
- Steroids
 - Oral, iv, retrobulbar, topical
- Radiation

Is there a role of steroids and radiation in thyroid related orbitopathy

Main question

Do steroids and/or radiation therapy really alter the endpoint of the disease?

OR

Do they only hasten resolution of the inflammatory phase?

Grading classifications

- Disease Activity versus Disease Severity
- Clinical Activity Score (CAS) - most cited
- NOSPECS - 1969 - problematic
- VISA - reported in 2006

Clinical Activity Score 10 points total

- Pain on or behind globe = 1 point
- Pain on eye movement = 1 point
- Redness of eyelid = 1 point
- Diffuse redness of conjunctiva = 1 point
- Eyelid swelling = 1 point
- Chemosis = 1 point
- Swelling of caruncle - 1 point
- Proptosis increase > 2 mm = 1 point
- Decrease eye movements > 5 degrees = 1 point
- Decrease visual acuity > 1 line

CAS = 8

- Chemosis
- Conj redness
- Lid redness
- Proptosis
- Caruncle edema
- Lid swelling
- Pain on globe
- Pain on movement

Classes of drugs for autoimmune diseases

- Non steroidal
 - ibuprofen, naproxen
- Steroidal
 - prednisolone, solumedrol
- Cytotoxic agents
 - antimetabolic (methotrexate, azathioprine)
- Biologic response modifiers
 - genetically engineered from human genes

27

Steroids

- Classes
 - Sex Hormones (testosterone, estrogens)
 - Anabolic
 - Corticosteroids
 - Glucocorticoids
 - Mineralocorticoids

28

Steroids - How do they work?

- Multiple effects
- Activate receptors to regulate expression of certain genes
- Inhibit release of pro-inflammatory mediators from cells
- Stimulate water and sodium absorption

Steroids - Routes of administration

- Oral
- IV
- Local Injections (periocular)

30

Steroids
Long Term Side Effects

- Weight gain
- Diabetes
- Osteoporosis
- Hypertension
- Cataracts
- Glaucoma
- Acne
- Gastric
Ulcers

Who should get steroids

- Inflammatory, active orbitopathy
- Moderate to severe CAS score > 3
- Not for mild disease!!

32

Oral Steroids

- Short term use only
- Consider use as a therapeutic trial
- No role for long term use

33

IV Steroids

- IV pulsed steroids more efficacious with less side effects than oral steroids
- Varying protocols
 - 1 gm methylprednisolone daily X 3
 - 500 mg weekly X 6 weeks
- Causes dose dependent liver toxicity
- Case reports of liver failure

34

Site Specific Therapy Steroid injections

- Periocular

Steroid injections - Periocular

- Ebner R, et al.
- BJO 2004;88:1380-1386

Steroid injections - Periocular

- 20 mg triamcinolone given in the inferior lateral quadrant q weekly times 4
- Randomized: control group- no treatment
- All patients had active disease and restrictive strabismus (main outcome measure)



Steroid injections - Periocular

- Statistically significant improvement in muscle function
 - Greater area of binocular diplopia fields
 - Lessening of muscle diameter on CT

Steroid injections - Periocular Conclusion

- Peribulbar injections are a useful adjunct
- Must be in active phase
- Side effects minimal
- No difference in IOP between groups
- I have found it useful in cases of optic neuropathy in non-surgical candidates with diabetes (serum glucose stable)

Steroids and RAI

- Controversial
- Premise: RAI causes worsening of orbitopathy in certain patients
- Bartalena 1997 NEJM showed worsening of eye findings in patients treated with RAI. Effect was counteracted by steroids
- Many studies show opposite findings, i.e. no worsening with RAI ⁴⁰

Consider steroids in high risk patients undergoing RAI

- Smokers
- Pre-existing moderate to severe disease
- Post RAI hypothyroidism

41

How much to take?

- Oral prednisone 0.5 mg per kg per day for 4 weeks then 8 week taper

42

Other medical therapy on the horizon

- Targeted therapy B cell therapy
Rituximab

Rituximab

- Monoclonal anti-CD20 antibody
- Targets B cell activation and differentiation
- Main use in lymphoma
- Fever, rigors, chills main side effect

Rituximab

- Salvi M, et al
- Euro J Endocrin 2007; 156:33-40

Rituximab

- Studied in 9 patients with active TED
- Compared to 20 patients who had IV methylprednisolone
- “Clinical response with rituximab more pronounced and earlier than with steroids”

Rituximab Conclusions

- Non-randomized
- Non-masked
- Costly
- Does it alter natural course? Or just expedite
- Larger randomized studies needed

Radiation

Radiation

- External beam radiation therapy
 - Unlike radioactive iodine which is injected IV

49

Radiation

- Different sources
 - Electromagnetic radiation - gamma (photons)
 - Particle beams - proton, neutron

Effects on cells

- Damages DNA
- Affects most rapidly multiplying cells
- In theory could cause DNA mutation if cells do not die

51

What are target cells in thyroid orbitopathy?

- Lymphocytes
- Monocytes
- Fibroblasts

52

Radiation Dosage

- Measure in units - Gray (Gy)
- Equal one joule of radiation energy absorbed by one kilogram of matter
- For thyroid orbitopathy - 20 Gy
- For cancerous tumors - 50 Gy

53

Radiation Side Effects

- Directly related to dosage
- Relatively low risk with 20 Gy
- Side effects:
 - Dry eyes, cataracts, retinopathy
- Should not be used in diabetics due to

Radiation for Thyroid Related Orbitopathy

- Controversial
- Some studies show benefit; others not
- Has been used for :
 - Optic neuropathy
 - Inflammatory disease
 - Strabismus
- Dosage 20 Gy

55

European Group On Graves Orbitopathy (EUGOGO) Consensus Paper

- Bartalena, Thyroid, 2008
- Radiation should be considered in:
 - Patients with diplopia or restricted motility
- Contraindicated in:
 - Patients younger than 35
 - Diabetics
 - Severe hypertension
- May be more effective with IV steroids

Orbital Radiation for Graves Orbitopathy (ORGO) Study

- Gorman, Mayo Clinic, 2001
- 43 patients
- “No benefit to radiation therapy”
- Criticisms:
 - Included patients beyond inflammatory phase
 - 19 of 42 treated with steroids before XRT
 - Did not include patients with optic neuropathy

57

**Answer to Question:
Zoumalan et al, J Neuro
Ophth 2007**

We conclude that there is inadequate case-based evidence to ascertain reliably whether medical therapy with corticosteroids or XRT shortens the active phase of disease or improves long-term disfigurement and disability in patients with moderate to severe

Conclusions

- Both steroids and XRT may have a role, but unclear
- Randomized clinical trials necessary to answer the above questions
- Newer targeted medical therapy may hold more promise

59

What have we learned?

- Psychological Disturbance Study
- Graded Decompression Study
 - Role for Botulinum A Toxin
 - Botox/Decompression Study

Mood Disturbance

Mood Disturbance Questions

- Does mood disturbance exist in TED?
- Is it related to the thyroid abnormality?
- Is it more related to functional disability or appearance?

Methods

CLINICAL SCIENCES

Psychological Disturbance in Graves Ophthalmopathy

- Depression Study - 2 groups
- Severe/Moderate eye signs versus Mild/None
- POMS survey (Profile of Mood States)
 - 65 item self inventory (6 subcategories)
 - Tension, Anger, Depression Vigor, Confusion, Fatigue

Results

CLINICAL SCIENCES

Psychological Disturbance in Graves Ophthalmopathy

- Significant depression Severe/Moderate compared to Non-ophthalmic Graves (control group)
- More associated with Disfigurement than Diplopia
- Magnitude of mood disturbance rivaled scores seen with cancer

What have we learned?

CLINICAL SCIENCES

Psychological Disturbance in Graves Ophthalmopathy

CONCLUSIONS

- Psychological burden should be considered
- Prompt referral to mental health professional

Does cutting cure a psychological problem?

Future Studies

- Repeat POMS before and after surgical intervention
- Would a lower threshold for surgical intervention might have a significant benefit in quality of life?

Orbital Decompression

- Indications
 - Optic Neuropathy
 - Corneal Exposure
 - Disfigurement
 - Pain/pressure

Orbital Decompression: Questions

- Possible to quantify results?
 - More predictability?
 - Tailor to each patient

Methods

Graded Orbital Decompression Based on Severity of Proptosis

- Divided into 3 grades of severity (Kalmann)
 - Grade I < 22 mm
 - Grade II 22-25 mm
 - Grade III > 25 mm

Grade I < 22 mm

Graded Orbital Decompression Based on Severity of Proptosis

- Lateral Wall
 - Greater wing of sphenoid
 - Lacrimal gland fossa
 - Inferior orbital fissure
- Fat Removal
 - Intraconal

Video

22 mm < Grade II < 25 mm

Graded Orbital Decompression Based on Severity of Proptosis

Grade II

- Lateral Wall
- Fat Removal
- Medial Wall

Area of dissection

**Transcaruncular
medial wall decompression -
procedure**

- Incision
 - Post-caruncular only versus combined with transconjunctival
- Disinsert inferior oblique if transconjunctival

Transcaruncular
medial wall decompression -
procedure

- Blunt dissection

Transcaruncular
medial wall decompression -
procedure

- Identify posterior lacrimal crest

Transcaruncular
medial wall decompression -
procedure

- Subperiosteal dissection

**Transcaruncular
medial wall decompression -
procedure**

- Identify anterior and posterior ethmoidal vessels
- Stay below frontoethmoidal suture line
 - Ethmoidal vessels are landmarks

Video - Low Magnification

**Video - Medial
Decompression**

22 mm < Grade II < 25 mm

Graded Orbital Decompression Based on Severity of Proptosis

Grade III > 25 mm

Graded Orbital Decompression Based on Severity of Proptosis

- Lateral Wall and Fat
 - Medial Wall
 - Posterior Floor
- Lateral Rim Advancement
- Primary recession of lower lid retractors if indicated

Grade I < 22 mm

- Lateral Wall and Fat

Grade II

- Lateral Wall and Fat
 - Medial Wall

Grade III

Study Shortcomings

- Looks at absolute proptosis and not the change
- Bony and fat removal must be comparable
- Does not look at orbital elasticity and compliance (type I versus type II)

Complications

Botulinum Toxin

Botulinum A Toxin

- First FDA approval for strabismus
- Described for use in thyroid orbitopathy by Scott in 1984

Botulinum A Toxin

Questions

- Is there any role in decompression?
 - Could incidence of strabismus be lessened?
 - Could pre-existing strabismus be improved

Role for Botulinum A Toxin? Adjunct to orbital decompression

- Type II patients with large muscles or strabismus in primary gaze undergoing decompression

Adjunct to orbital decompression

- Presented at ASOPRS Dallas, October 2000
 - Series of 8 patients with pre-existing strabismus or at high risk (large muscles)
- 10-15 units of botox to MR, IR under direct visualization
 - No patient had worsening of pre-existing strabismus
 - No patient without diplopia developed it post-op

Unilateral 2 wall decompression
LIR Botox A, No muscle surgery

PRE POST

UPGAZE

PRE POST

DOWNGAZE

PRE POST

Botulinum A toxin - Intraop

Conclusions

- Adjunct to decompression
 - Lack of controls
 - ? Inflammation
- Increased myofibril contraction
- Release of EOM may cause stretching effect
 - Lessen amount of EOM surgery

Thyroid Eye Disease: Clinical Challenges

- Severe unilateral disease
 - Involvement of opposite side
 - Worse after surgery
 - (sympathetic orbitopathy?)
- Immune therapy/prevention of disease
 - Disease predictors

Thyroid Eye Disease: Clinical Challenges Severe unilateral disease

Thyroid Eye Disease:
Clinical Challenges
Severe unilateral disease

Thank you for your attention!
