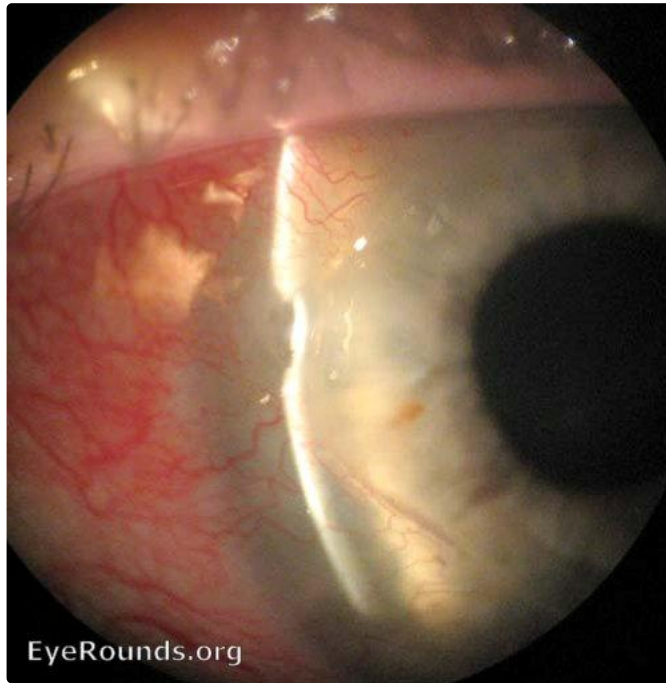


Peripheral ulcerative keratitis (PUK) in rheumatoid arthritis

Category(ies): Cornea

Contributor: [Andrew Doan, MD, PhD](#)



Peripheral corneal melt associated with inflammation.

[Enlarge](#) [Download](#)

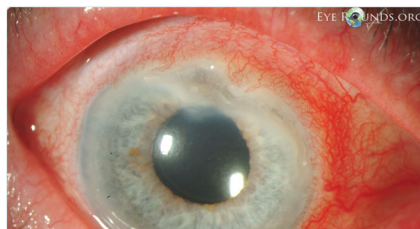
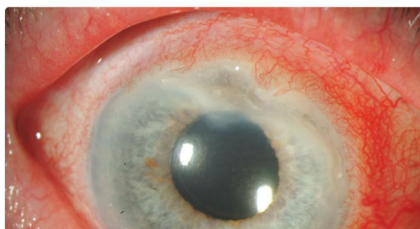
Image Permissions:

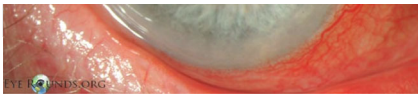


Ophthalmic Atlas Images by [EyeRounds.org](#), [The University of Iowa](#) are licensed under a [Creative Commons Attribution-NonCommercial-NoDerivs 3.0 Unported License](#).

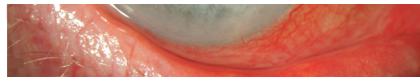


Related Articles





[Related Atlas Entry: Peripheral ulcerative keratitis \(PUK\)](#)



[Related Case Entry: Peripheral ulcerative keratitis \(PUK\)](#)

Address

University of Iowa
Roy J. and Lucille A. Carver College
of Medicine
Department of Ophthalmology and
Visual Sciences
200 Hawkins Drive
Iowa City, IA 52242

[Support Us](#)

Legal

Copyright © 2019 The University of
Iowa. All Rights Reserved
[Report an issue with this page](#)
[Web Privacy Policy |](#)
[Nondiscrimination Statement](#)

Related Links

[Cataract Surgery for Greenhorns](#)
[EyeTransillumination](#)
[Gonioscopy.org](#)
[Iowa Glaucoma Curriculum](#)
[Iowa Wet Lab](#)
[Patient Information](#)
[Stone Rounds](#)
[The Best Hits Bookshelf](#)

EyeRounds Social Media

Follow



Receive notification of new cases,
[sign up here](#)
[Contact Us](#)
[Submit a Suggestion](#)