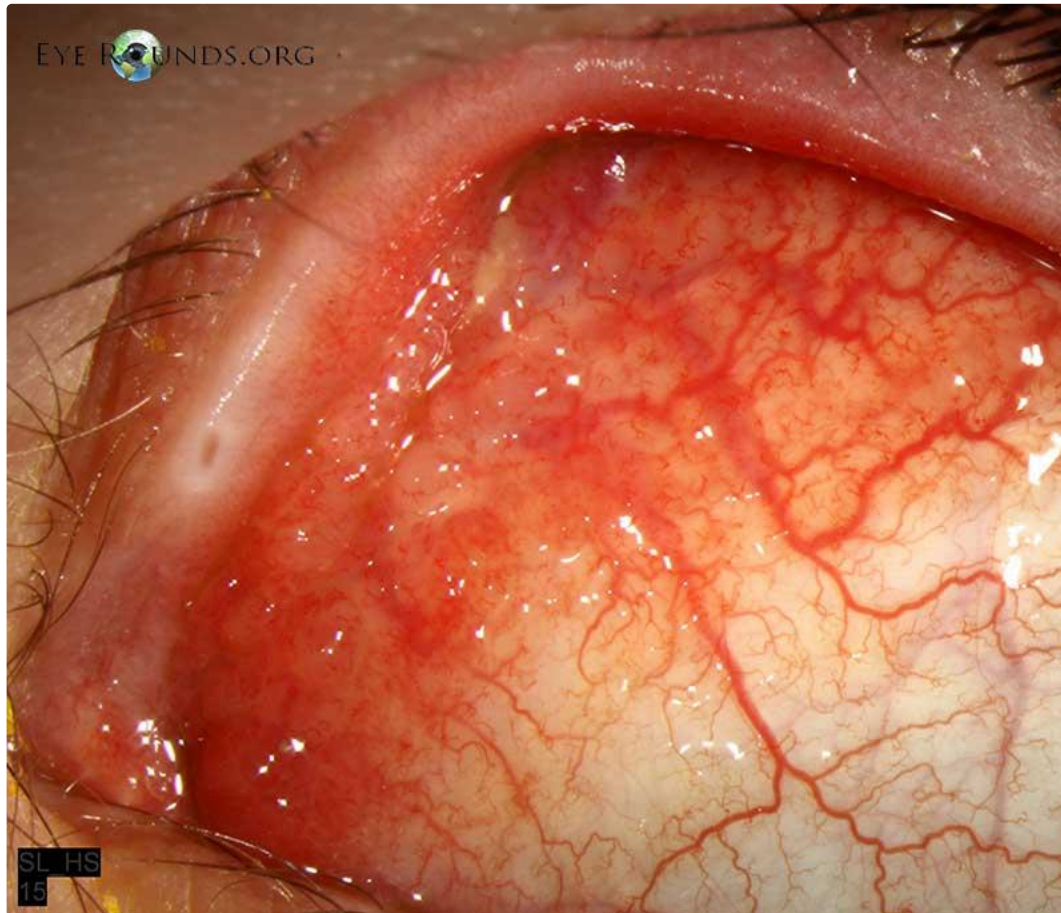


Chlamydia Trachomatis Infection

Category(ies): External Disease

Contributor: [Elizabeth Gauger, MD](#)

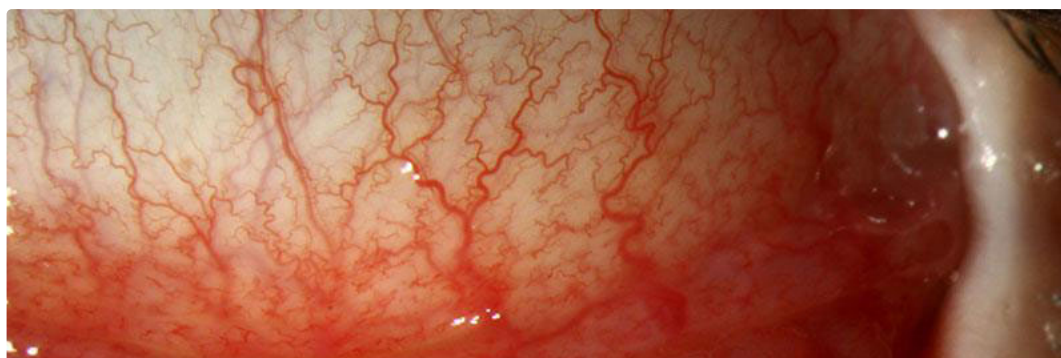Photographer: D. Brice Critser, CRA

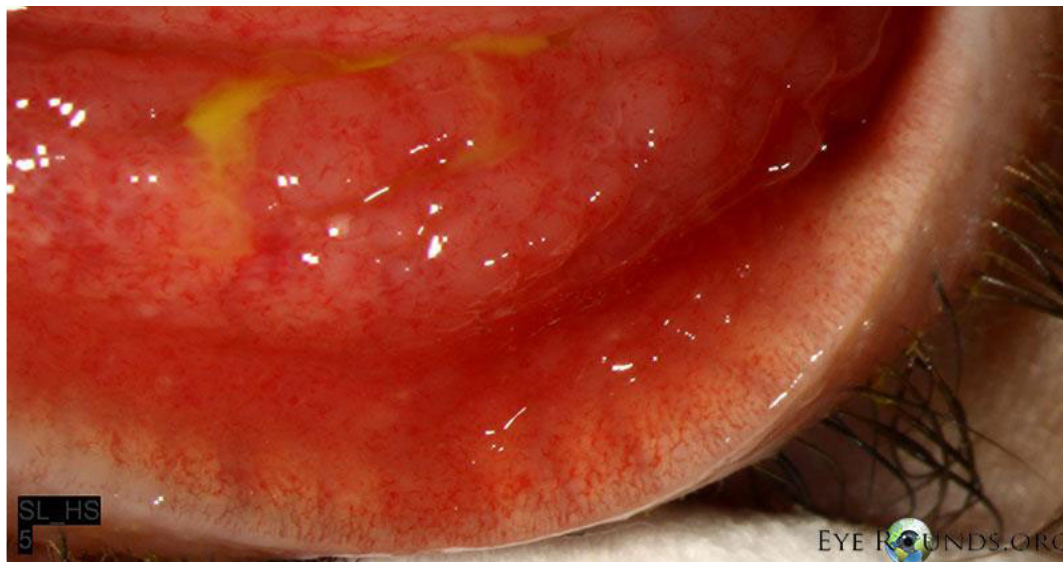

Follicles on the bulbar conjunctiva, characteristic of *Chlamydia trachomatis* infection

[Enlarge](#)

[Download](#)





Note the follicles in the inferior fornix

[Enlarge](#) [Download](#)

Reference:

Krachmer, Jay H., Mark J. Mannis, Edward J. Holland. Cornea. St. Louis: Mosby, 2011.

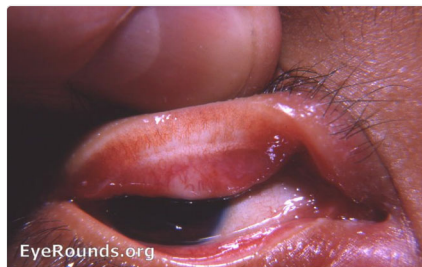Image Permissions:



Ophthalmic Atlas Images by EyeRounds.org, The University of Iowa are licensed under a Creative Commons Attribution-NonCommercial-NoDerivs 3.0 Unported License.



Related Articles



[Related Atlas Etnry: Trachoma](#)

Address

University of Iowa
Roy J. and Lucille A. Carver College
of Medicine

Legal

Copyright © 2019 The University of
Iowa. All Rights Reserved
[Report an issue with this page](#)

Related Links

[Cataract Surgery for Greenhorns](#)
[EyeTransillumination](#)
[Gonioscopy.org](#)

EyeRounds Social Media

[Follow](#)

Department of Ophthalmology and
Visual Sciences
200 Hawkins Drive
Iowa City, IA 52242

[Support Us](#)

[Web Privacy Policy |
Nondiscrimination Statement](#)

[Iowa Glaucoma Curriculum](#)
[Iowa Wet Lab](#)
[Patient Information](#)
[Stone Rounds](#)
[The Best Hits Bookshelf](#)



[Receive notification of new cases,
sign up here](#)
[Contact Us](#)
[Submit a Suggestion](#)