

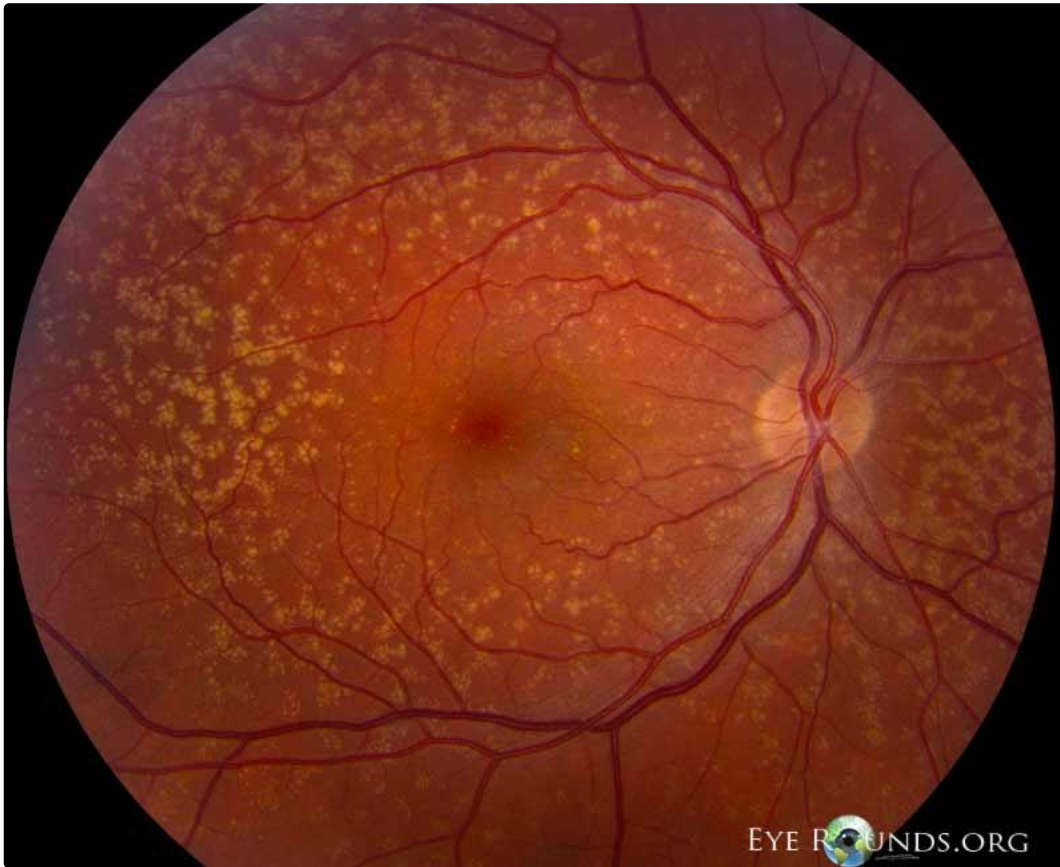
## Cuticular Drusen

Category(ies): [Retina](#), [Genetics](#)

Contributor: [Jesse Vislisel, MD](#)

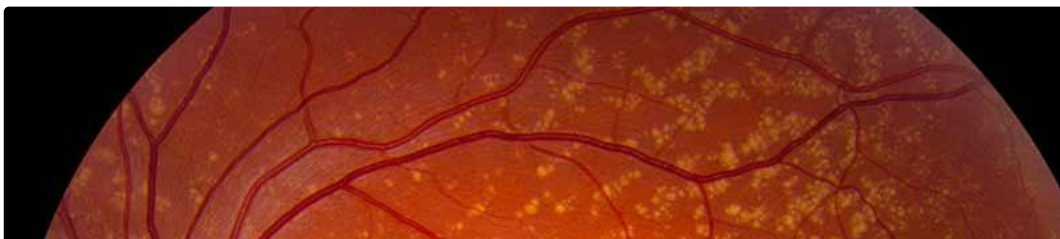


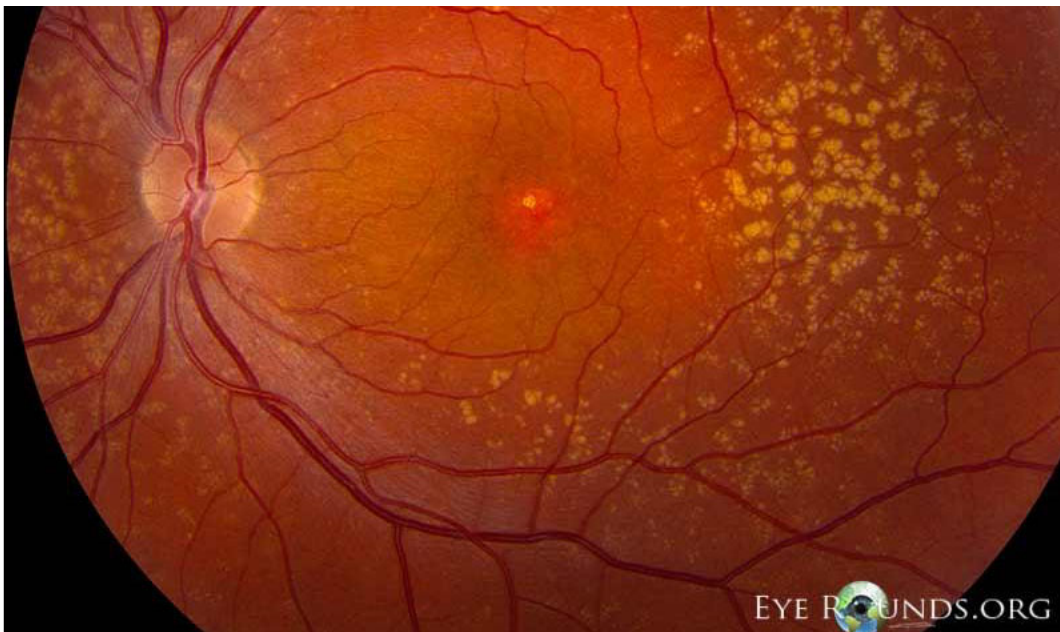Cuticular drusen, also known as basal laminar drusen, are a type of familial drusen characterized by many clumps of tiny, extramacular drusen. They are strongly associated with the Tyr402His variant of the complement factor H (CFH) gene. Acuity often remains good as long as the drusen remain outside of the fovea.



OD

[Enlarge](#) [Download](#)

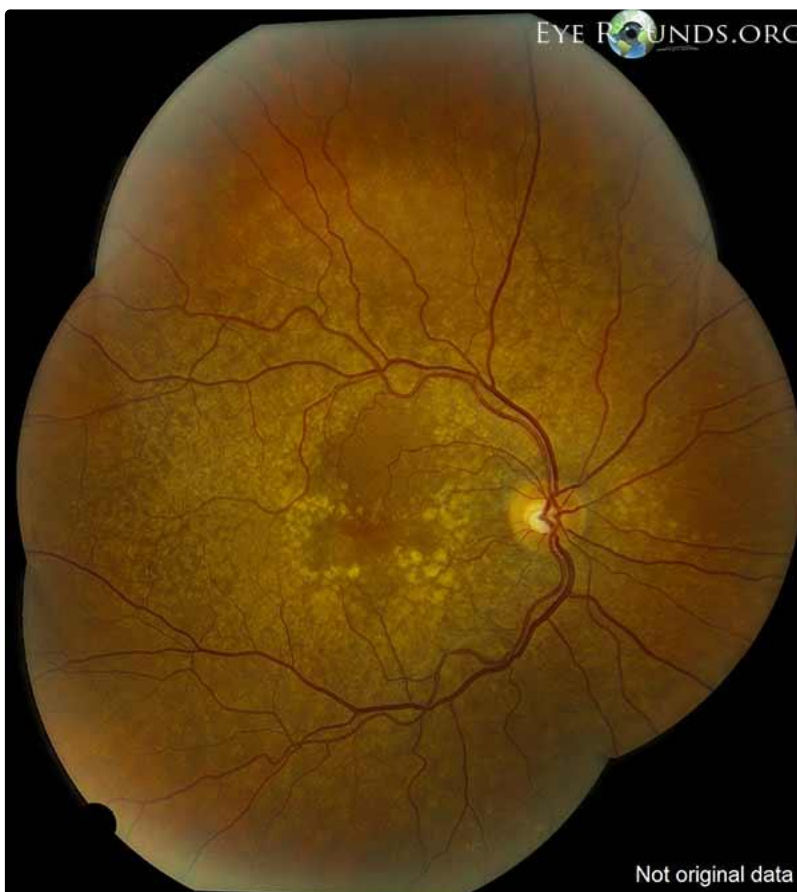




OS

[Enlarge](#)

[Download](#)

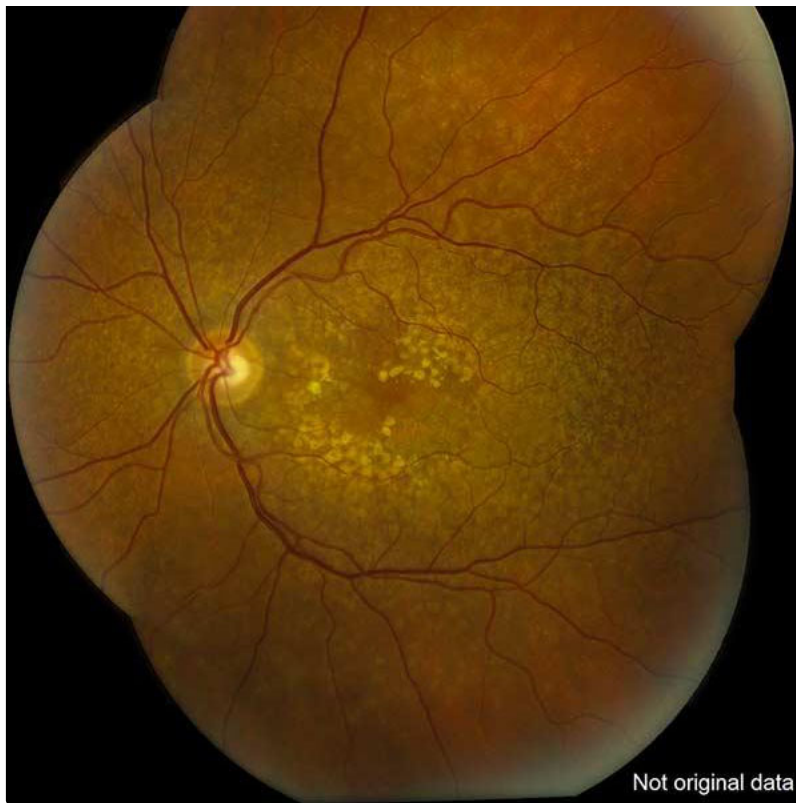


OD

[Enlarge](#)

[Download](#)





OS

 [Enlarge](#)

 [Download](#)

### Image Permissions:



Ophthalmic Atlas Images by [EyeRounds.org](http://EyeRounds.org), [The University of Iowa](http://The University of Iowa) are licensed under a [Creative Commons Attribution-NonCommercial-NoDerivs 3.0 Unported License](https://creativecommons.org/licenses/by-nc-nd/3.0/).

### Address

University of Iowa  
Roy J. and Lucille A. Carver College  
of Medicine  
Department of Ophthalmology and  
Visual Sciences  
200 Hawkins Drive  
Iowa City, IA 52242

[Support Us](#)

### Legal

Copyright © 2019 The University of  
Iowa. All Rights Reserved  
[Report an issue with this page](#)  
[Web Privacy Policy](#) |  
[Nondiscrimination Statement](#)

### Related Links

[Cataract Surgery for Greenhorns](#)  
[EyeTransillumination](#)  
[Gonioscopy.org](http://Gonioscopy.org)  
[Iowa Glaucoma Curriculum](#)  
[Iowa Wet Lab](#)  
[Patient Information](#)  
[Stone Rounds](#)  
[The Best Hits Bookshelf](#)

### EyeRounds Social Media

Follow



Receive notification of new cases,  
[sign up here](#)  
[Contact Us](#)  
[Submit a Suggestion](#)