

Epiretinal membrane

Category(ies): Retina, Vitreous

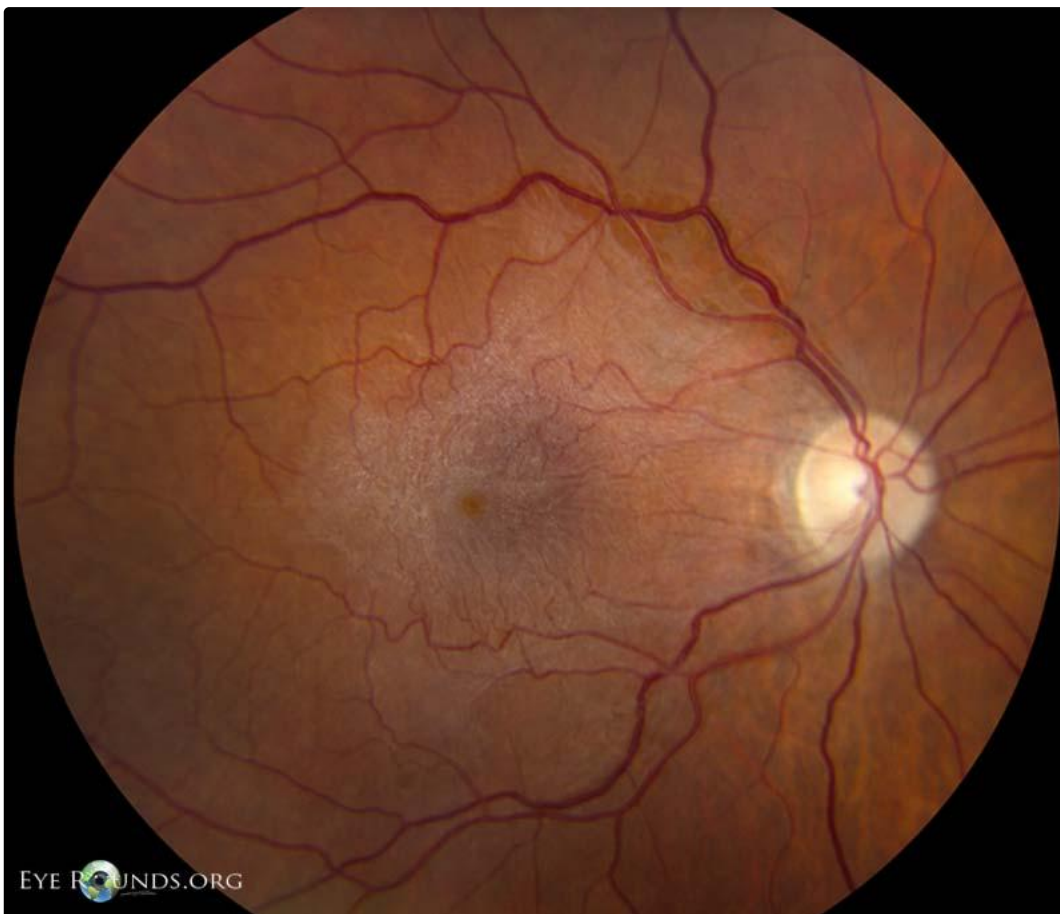Contributor: [Eric Chin, MD](#)

Photographer: Randy Verdick, FOPS



A 66-year-old pseudophakic female presented with worsening blurry vision and metamorphopsia, right eye more than left eye. She also complained of monocular diplopia in the right eye. She denied pain or irritation.

Her visual acuity was 20/60 in the right eye and 20/50-2 in the left eye, with no improvement with pinholes in either eye.



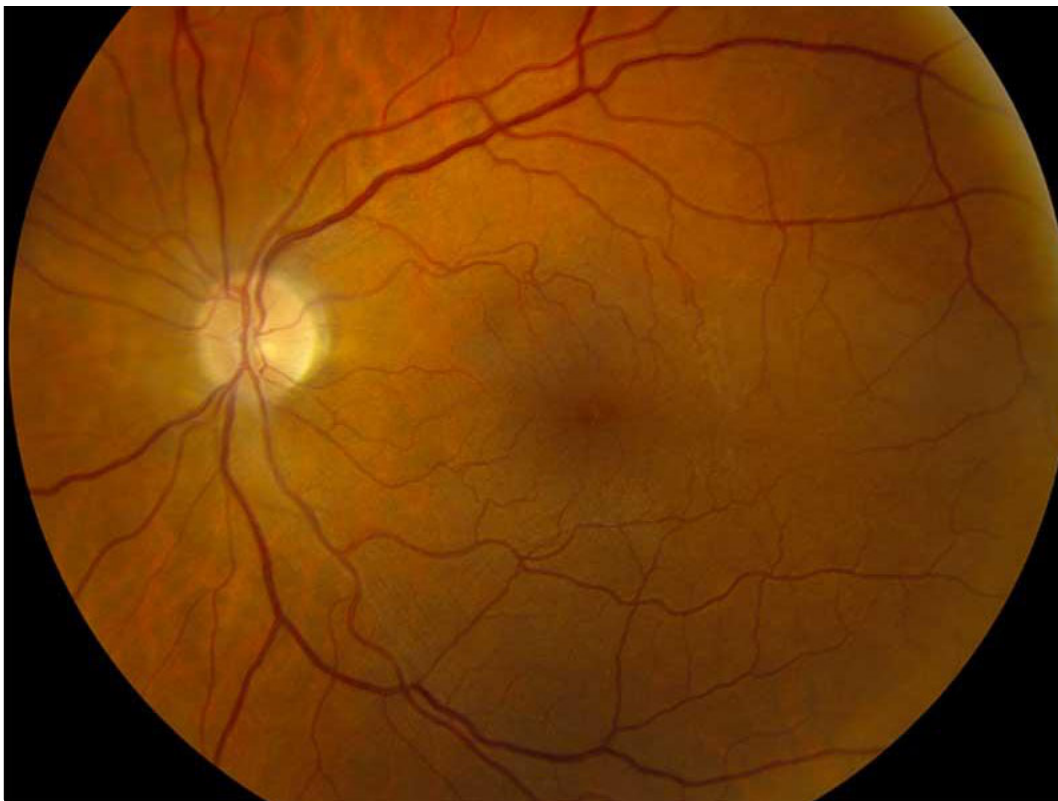EYE ROUNDS.ORG

1. Right eye: diffuse dense epiretinal membrane/macular pucker

[Enlarge](#) [Download](#)



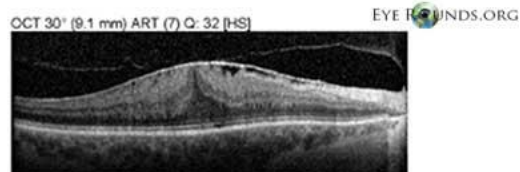
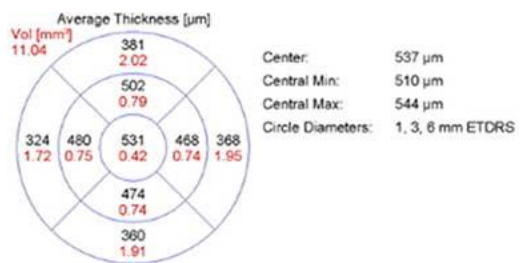
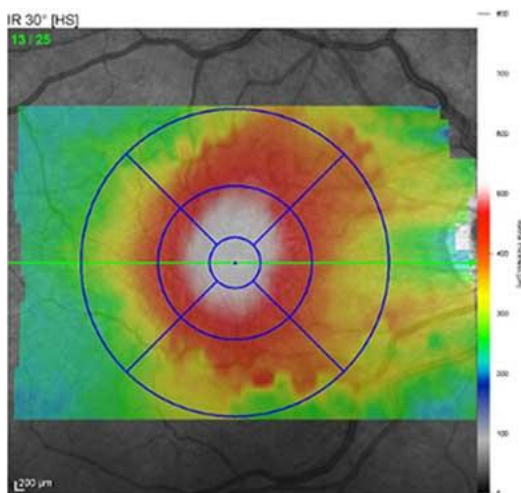
EYE ROUNDS.ORG



Left eye: trace epiretinal membrane

[Enlarge](#)


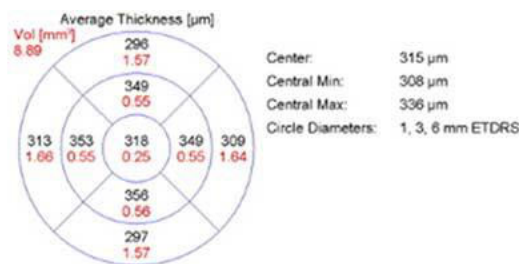
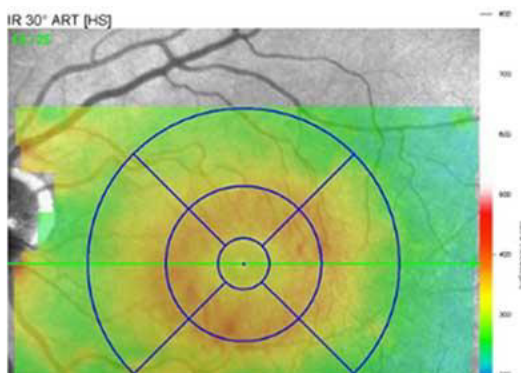
[Download](#)

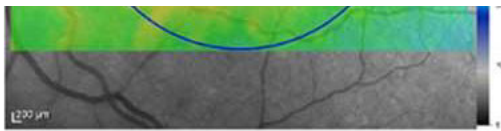


3 Optical coherence tomography of the right eye reveals an epiretinal membrane and diffuse retinal thickening of the macula.

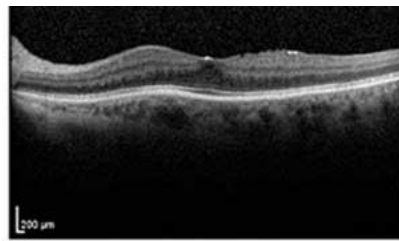
[Enlarge](#)

[Download](#)





EYE ROUNDS.ORG



Optical coherence tomography of the left eye reveals trace retinal thickening and epiretinal membrane

[Enlarge](#) [Download](#)

Epiretinal Membranes

- An epiretinal membrane (ERM) is a semi-translucent, avascular, fibrocellular membrane on the inner retinal surface along the internal limiting membrane of the retina.
- ERMs may be idiopathic, or secondary to a variety of conditions such as retinal vascular occlusions, uveitis, trauma, intraocular surgery, and retinal breaks.
- Contracture of ERMs produces distortion and wrinkling of the inner surface of the retina. It is also called “cellophane maculopathy” or “pre-retinal macular fibrosis” when mild; “surface wrinkling retinopathy” or “retinal striae” when moderate; or “macular pucker” when severe.

Image Permissions:



Ophthalmic Atlas Images by [EyeRounds.org](https://www.eyerounds.org), [The University of Iowa](https://www.theuniversityofiowa.edu) are licensed under a [Creative Commons Attribution-NonCommercial-NoDerivs 3.0 Unported License](https://creativecommons.org/licenses/by-nc-nd/3.0/).

Address

University of Iowa
Roy J. and Lucille A. Carver College
of Medicine
Department of Ophthalmology and
Visual Sciences
200 Hawkins Drive
Iowa City, IA 52242

[Support Us](#)

Legal

Copyright © 2019 The University of
Iowa. All Rights Reserved
[Report an issue with this page](#)
[Web Privacy Policy](#) |
[Nondiscrimination Statement](#)

Related Links

[Cataract Surgery for Greenhorns](#)
[EyeTransillumination](#)
[Gonioscopy.org](#)
[Iowa Glaucoma Curriculum](#)
[Iowa Wet Lab](#)
[Patient Information](#)
[Stone Rounds](#)
[The Best Hits Bookshelf](#)

EyeRounds Social Media

Follow



Receive notification of new cases,
[sign up here](#)
[Contact Us](#)
[Submit a Suggestion](#)