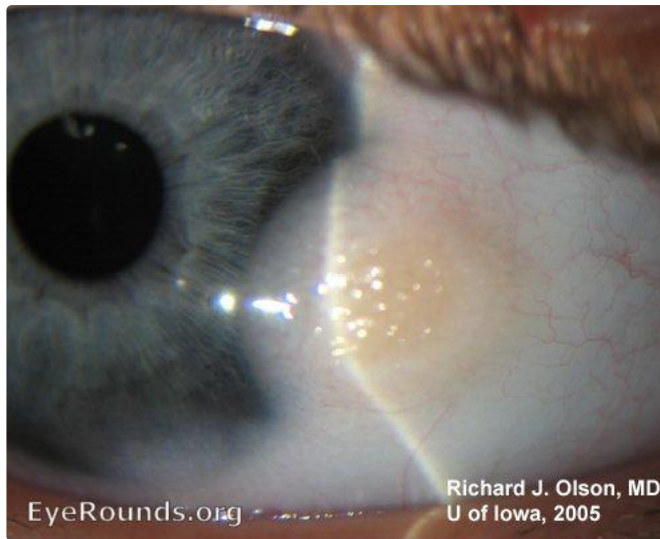


## Goldenhar's Syndrome

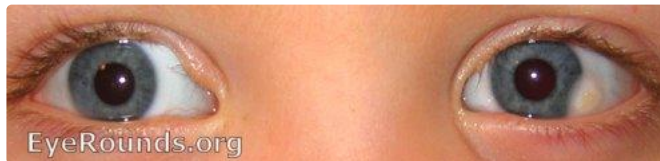Category(ies): Pediatrics

Contributor: Richard J. Olson, MD



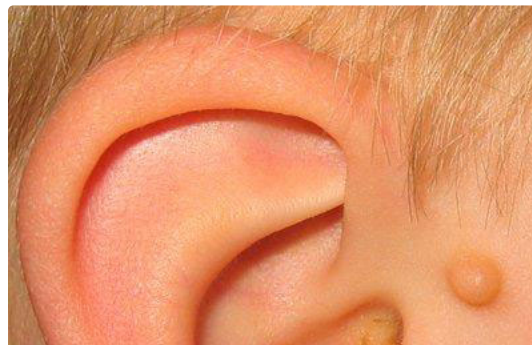A classic limbal dermoid of Goldenhar's syndrome in a 4-year-old boy.

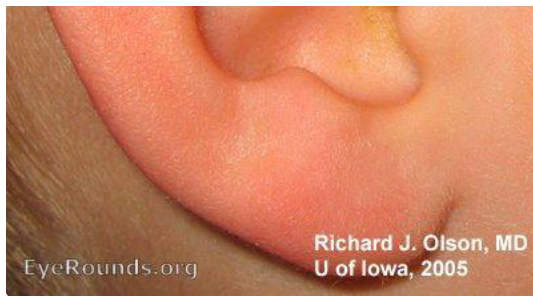[Enlarge](#) [Download](#)



This view of both eyes shows a partial lid coloboma of the right upper lid.

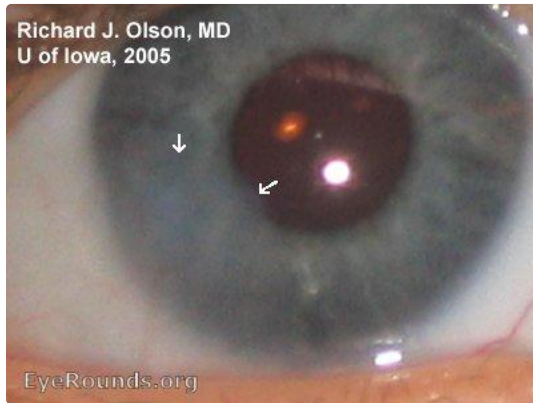[Enlarge](#) [Download](#)





Preauricular skin tag

[Enlarge](#) [Download](#)



A faint scar can be appreciated on the cornea of the right eye where a larger dermoid was excised 2 years ago.

[Enlarge](#) [Download](#)

### Image Permissions:



Ophthalmic Atlas Images by [EyeRounds.org](http://EyeRounds.org), [The University of Iowa](http://The University of Iowa) are licensed under a [Creative Commons Attribution-NonCommercial-NoDerivs 3.0 Unported License](http://Creative Commons Attribution-NonCommercial-NoDerivs 3.0 Unported License).

### Address

University of Iowa  
Roy J. and Lucille A. Carver College  
of Medicine  
Department of Ophthalmology and  
Visual Sciences  
200 Hawkins Drive  
Iowa City, IA 52242

[Support Us](#)

### Legal

Copyright © 2019 The University of  
Iowa. All Rights Reserved  
[Report an issue with this page](#)  
[Web Privacy Policy](#) |  
[Nondiscrimination Statement](#)

### Related Links

[Cataract Surgery for Greenhorns](#)  
[EyeTransillumination](#)  
[Gonioscopy.org](#)  
[Iowa Glaucoma Curriculum](#)  
[Iowa Wet Lab](#)  
[Patient Information](#)  
[Stone Rounds](#)  
[The Best Hits Bookshelf](#)

### EyeRounds Social Media

Follow



Receive notification of new cases,  
[sign up here](#)  
[Contact Us](#)  
[Submit a Suggestion](#)