

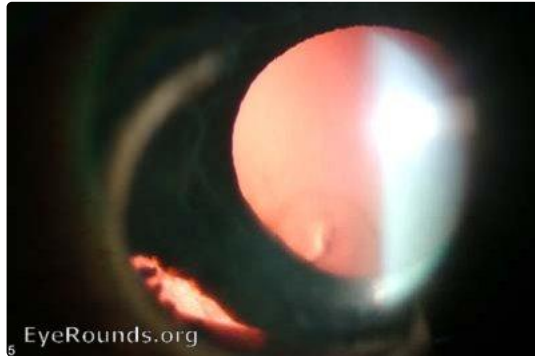EyeRounds.org

Iridodialysis

Category(ies): Trauma, Iris

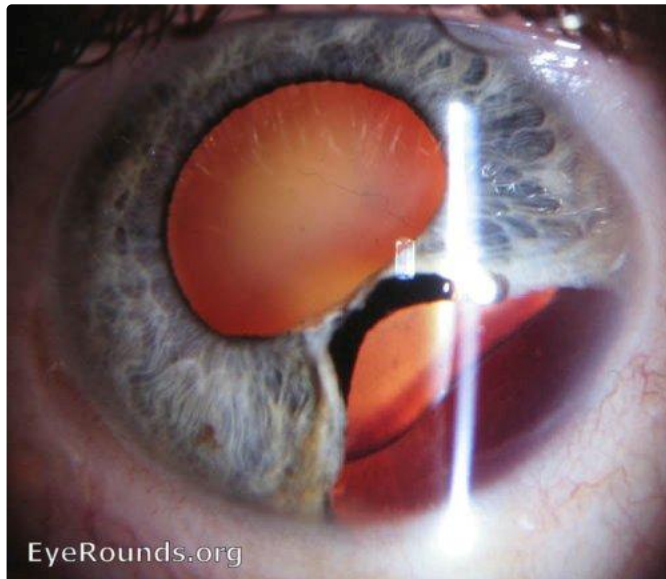
Contributor: [Andrew Doan, MD, PhD](#)

Photographer: Brice Critser, CRA



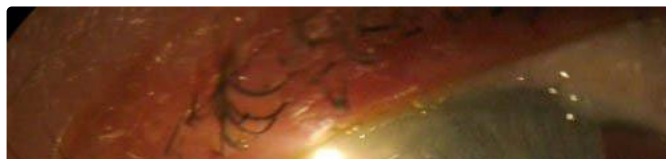retroillumination - Iridodialysis from BB gun injury

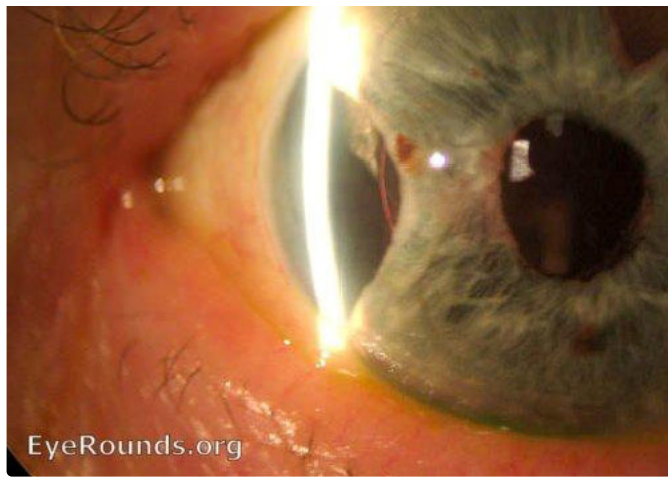
[Enlarge](#) [Download](#)



Patient with blunt trauma resulting in tear of the iris.

[Enlarge](#) [Download](#)



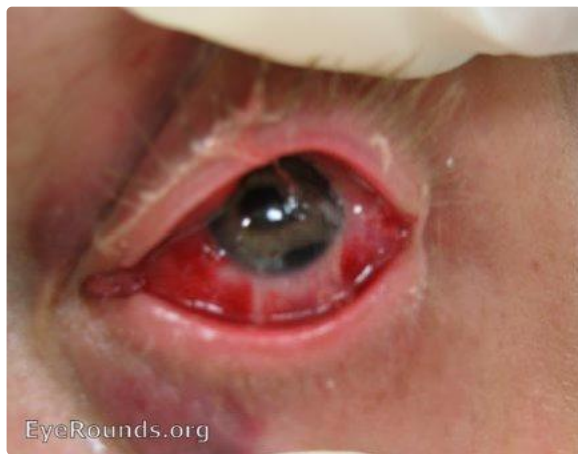

EyeRounds.org

Patient with blunt trauma resulting in tear of the iris.

[Enlarge](#)

[Download](#)

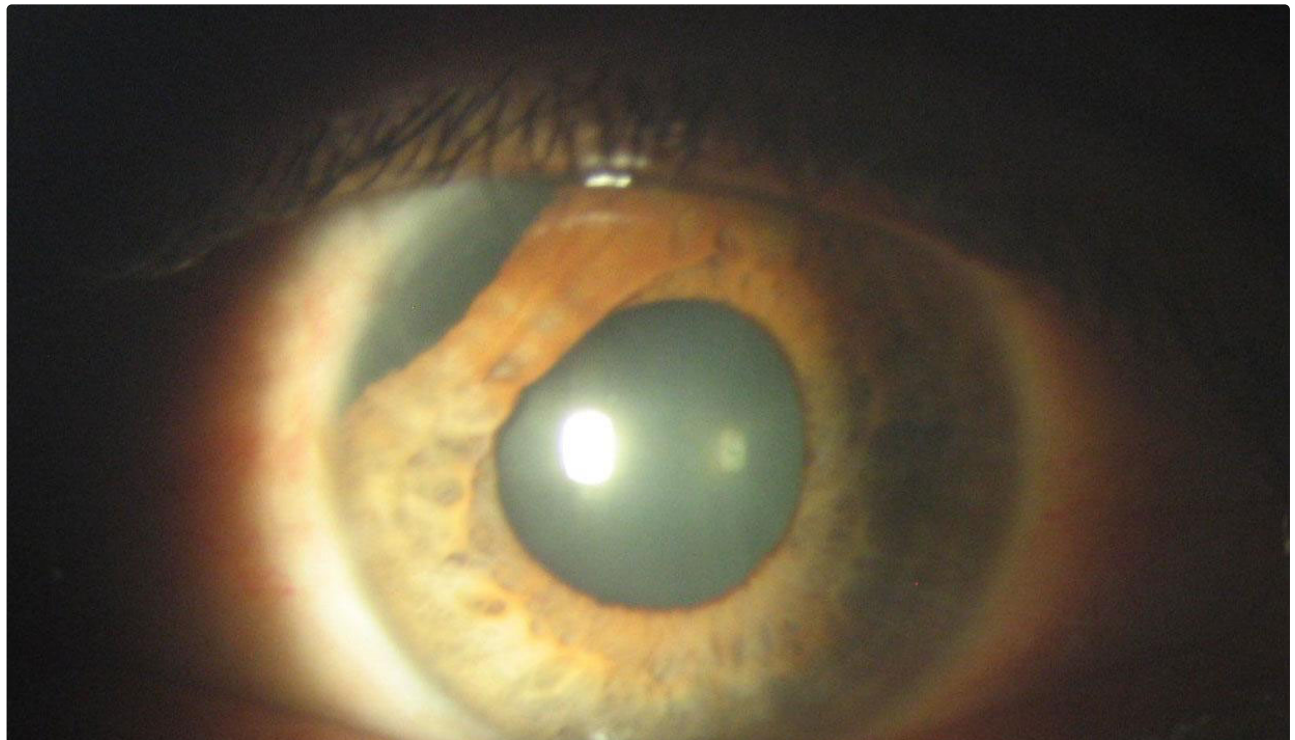


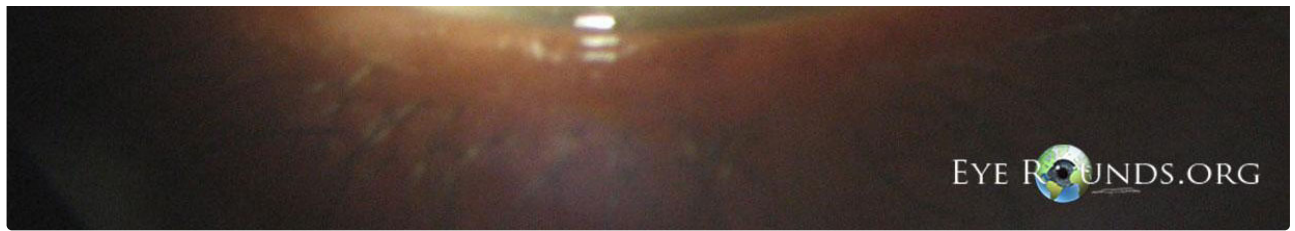EyeRounds.org

Patient was hit with a paintball.

[Enlarge](#)

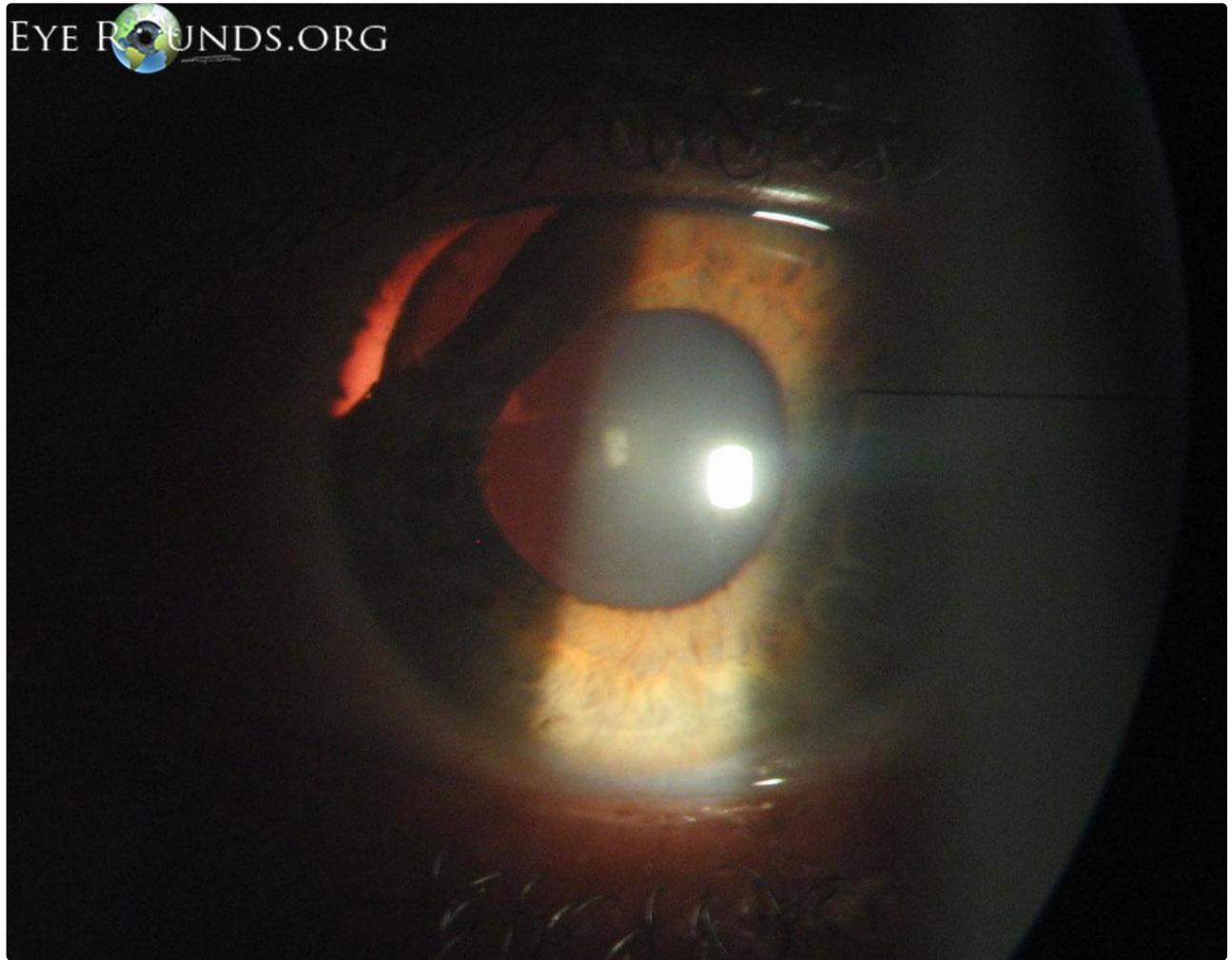
[Download](#)





38-year-old Afghani male was struck in the head with a stick 2 months prior to this photograph. Examination reveals an asymptomatic supero-nasal idiodialysis of the left eye.

[Enlarge](#) [Download](#)



Note that in this retro-illumination view, one can even see the shadow from a few zonules.

[Enlarge](#) [Download](#)

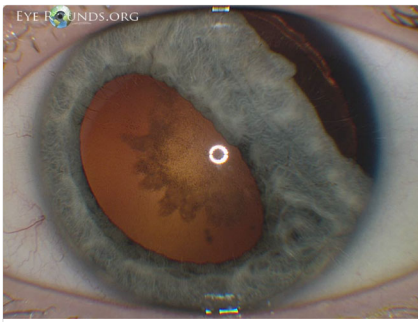
Image Permissions:



Ophthalmic Atlas Images by EyeRounds.org, The University of Iowa are licensed under a Creative Commons Attribution-NonCommercial-NoDerivs 3.0 Unported License.



Related Articles



[Related Atlas Entry: Iridodialysis and traumatic cataract after firecracker injury](#)

Address

University of Iowa
Roy J. and Lucille A. Carver College
of Medicine
Department of Ophthalmology and
Visual Sciences
200 Hawkins Drive
Iowa City, IA 52242

[Support Us](#)

Legal

Copyright © 2019 The University of
Iowa. All Rights Reserved
[Report an issue with this page](#)
[Web Privacy Policy](#) |
[Nondiscrimination Statement](#)

Related Links

[Cataract Surgery for Greenhorns](#)
[EyeTransillumination](#)
[Gonioscopy.org](#)
[Iowa Glaucoma Curriculum](#)
[Iowa Wet Lab](#)
[Patient Information](#)
[Stone Rounds](#)
[The Best Hits Bookshelf](#)

EyeRounds Social Media

Follow



Receive notification of new cases,
[sign up here](#)
[Contact Us](#)
[Submit a Suggestion](#)