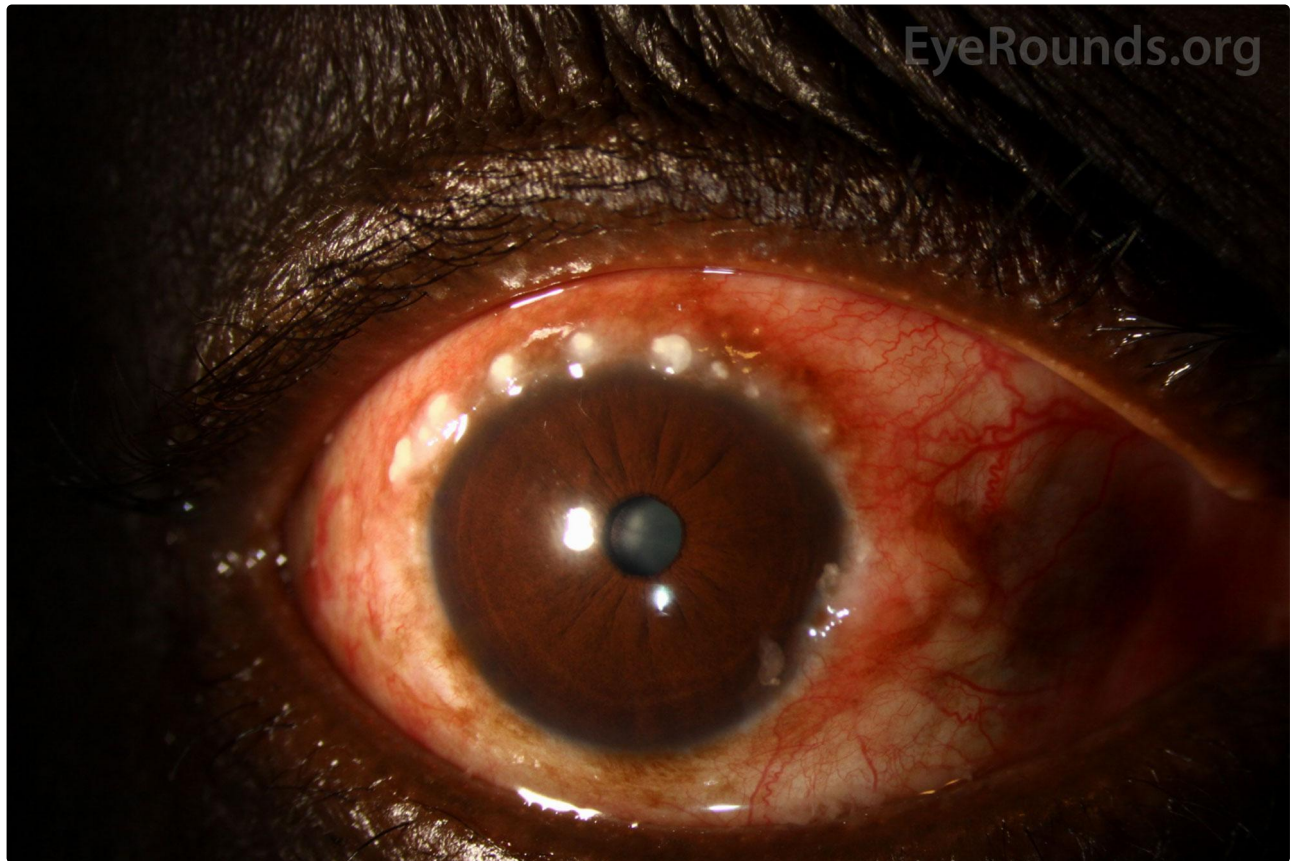


Limbal vernal keratoconjunctivitis (VKC)

Category(ies): Cornea, External Disease

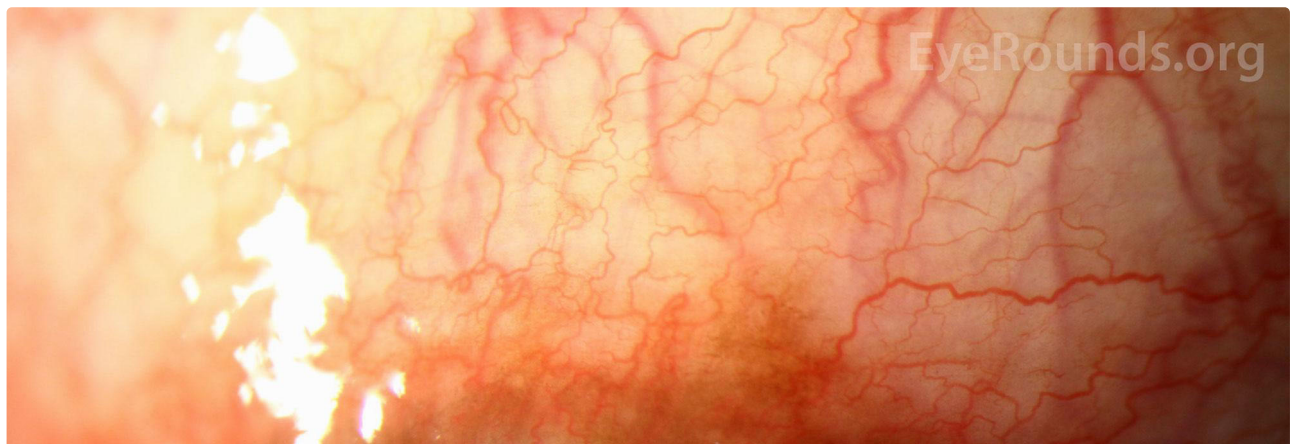
Contributor: Zachary Q. Mortensen, MD; [Anthony T. Chung, MD](#); [A. Tim Johnson, MD](#)

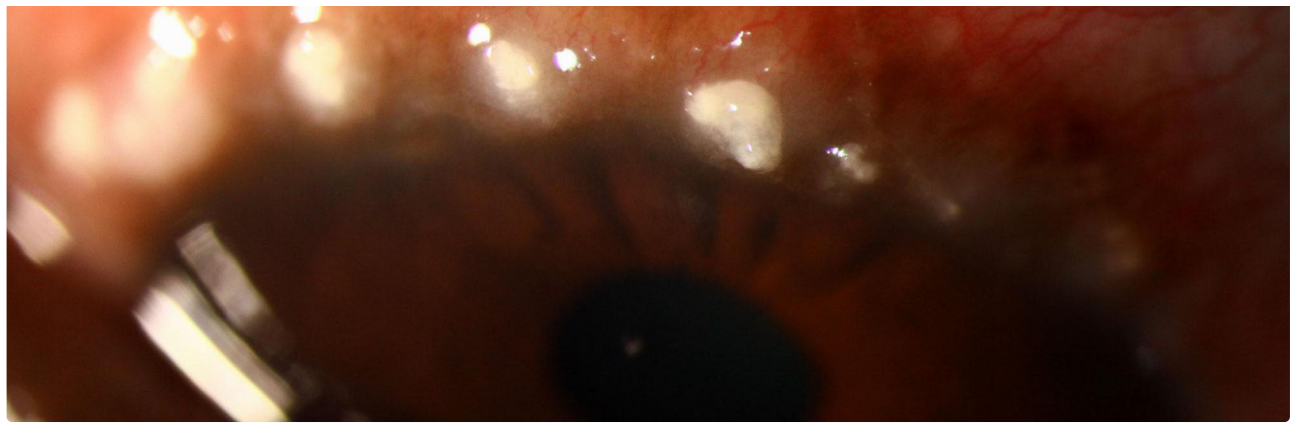
Photographer: D. Brice Critser, CRA, OCT-C



Severe VKC in a 17-year-old Afghani Male. Note the very large "cobblestone" papillae of the superior tarsal conjunctiva in both lids.

[Enlarge](#) [Download](#)



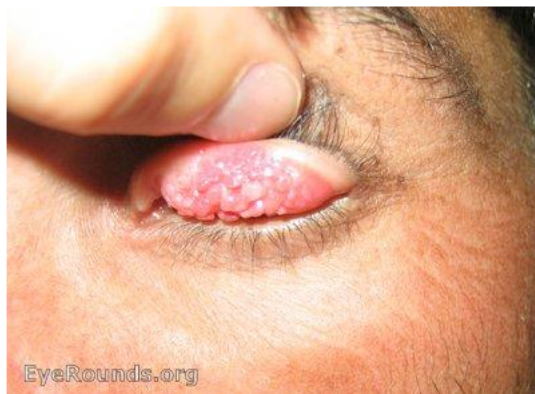

[Enlarge](#) [Download](#)

Limbal vernal keratoconjunctivitis (VKC)

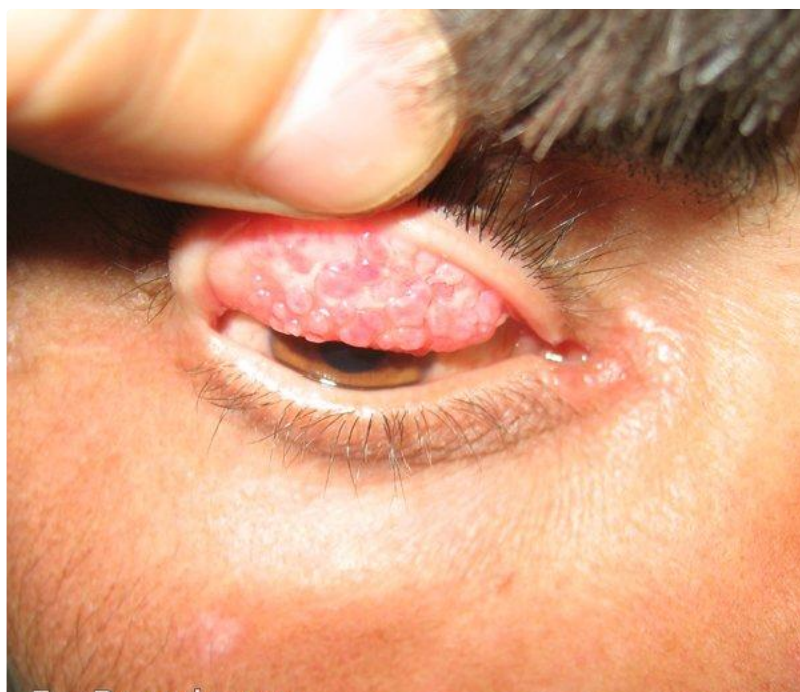Category(ies): External Disease

Contributor: David W Hayes, DO, US Military Flight Surgeon



Severe VKC in a 17-year-old Afghani Male. Note the very large "cobblestone" papillae of the superior tarsal conjunctiva in both lids.

[Enlarge](#) [Download](#)



In this image, the concurrent bulbar conjunctival injection and limbal conjunctivitis is evident beneath the lid (see related EyeRounds case <http://EyeRounds.org/cases/70-Vernal-Keratoconjunctivitis-Atopic-Asthma.htm>).

[Enlarge](#) [Download](#)

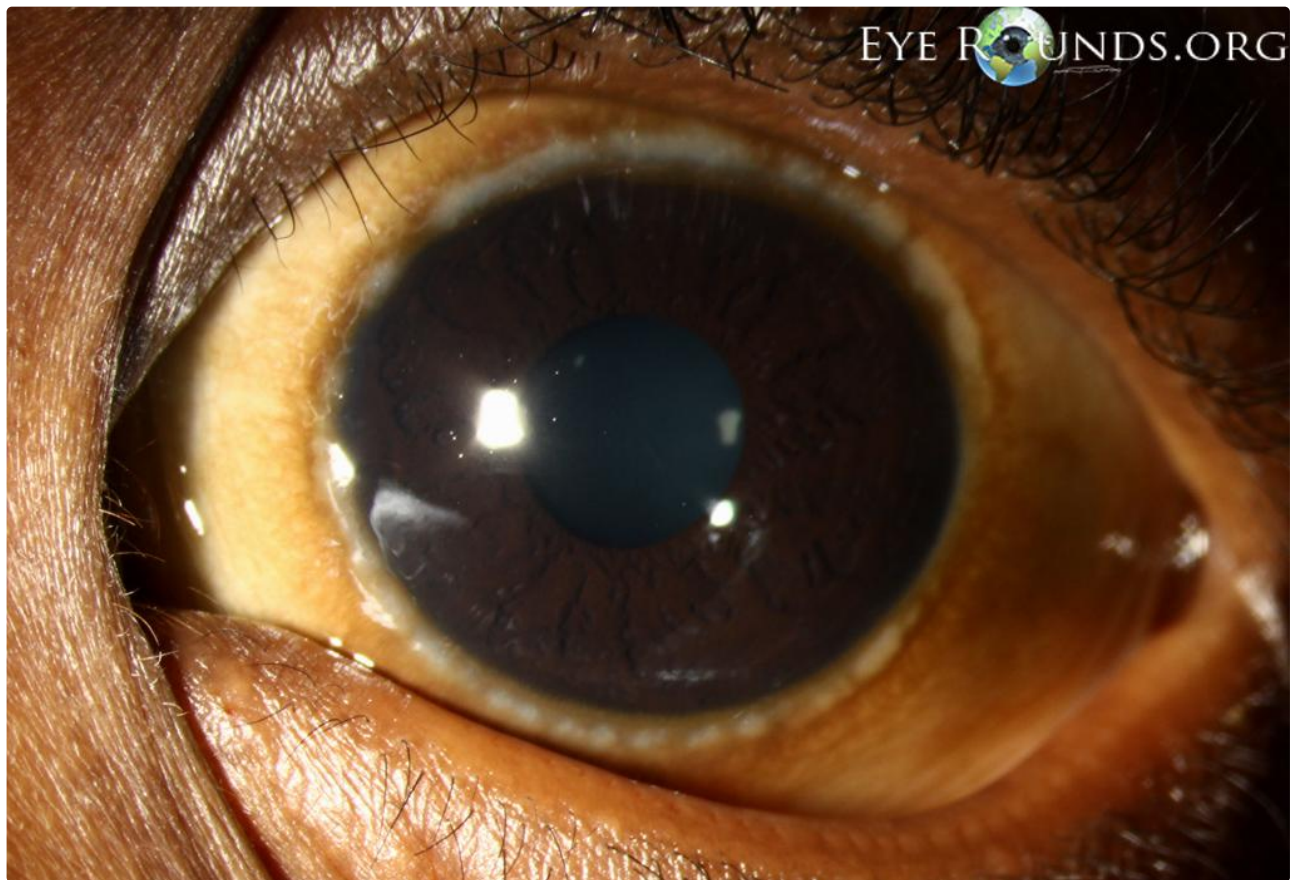Limbal vernal keratoconjunctivitis (VKC)

Category(ies): Cornea, External Disease, Pediatrics

Contributor: [Jesse Vislisel, MD](#)

Photographer: Stefani Karakas, CRA

Vernal keratoconjunctivitis (VKC) is a seasonal disorder, predominantly seen in male children with a history of atopy, which results in inflammation of the cornea and conjunctiva. Limbal VKC is most common in children of African or Asian descent and may occur alone or in combination with palpebral VKC. Clinical features include Horner-Trantas dots (raised, white accumulations of eosinophils at the limbus), gelatinous limbal follicles, and copious amounts of mucoid discharge.



[Enlarge](#) [Download](#)

Reference:

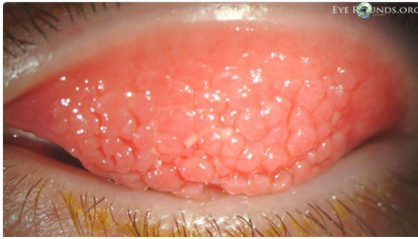
Koczman J, Oetting TA: Vernal Keratoconjunctivitis: 8-year-old asthmatic male with reduced vision. EyeRounds.org. June 25, 2007; Available from: <http://www.EyeRounds.org/cases/70-Vernal-Keratoconjunctivitis-Atopic-Asthma.htm>.

Image Permissions:

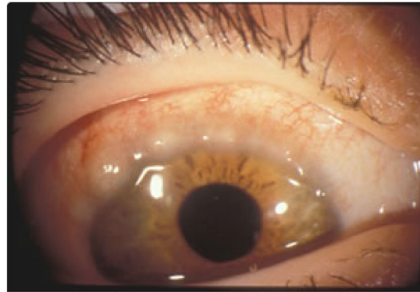

Ophthalmic Atlas Images by [EyeRounds.org](#), [The University of Iowa](#) are licensed under a [Creative Commons Attribution-NonCommercial-NoDerivs 3.0 Unported License](#).

Related Articles



[Related Atlas Entry: Palpebral vernal keratoconjunctivitis \(VKC\)](#)



[Related Case Entry: Vernal Keratoconjunctivitis](#)

Address

University of Iowa
Roy J. and Lucille A. Carver College
of Medicine
Department of Ophthalmology and
Visual Sciences
200 Hawkins Drive
Iowa City, IA 52242

[Support Us](#)

Legal

Copyright © 2019 The University of
Iowa. All Rights Reserved
[Report an issue with this page](#)
[Web Privacy Policy](#) |
[Nondiscrimination Statement](#)

Related Links

[Cataract Surgery for Greenhorns](#)
[EyeTransillumination](#)
[Gonioscopy.org](#)
[Iowa Glaucoma Curriculum](#)
[Iowa Wet Lab](#)
[Patient Information](#)
[Stone Rounds](#)
[The Best Hits Bookshelf](#)

EyeRounds Social Media

Follow



[Receive notification of new cases, sign up here](#)
[Contact Us](#)
[Submit a Suggestion](#)