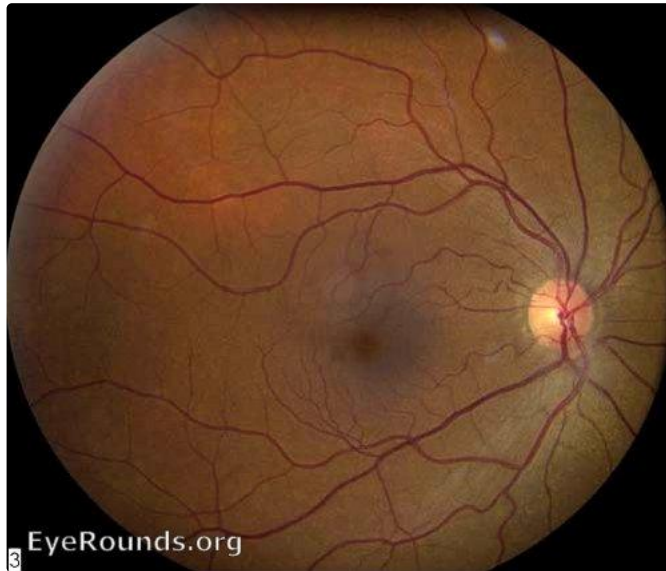


EyeRounds.org

Nevus of Ota

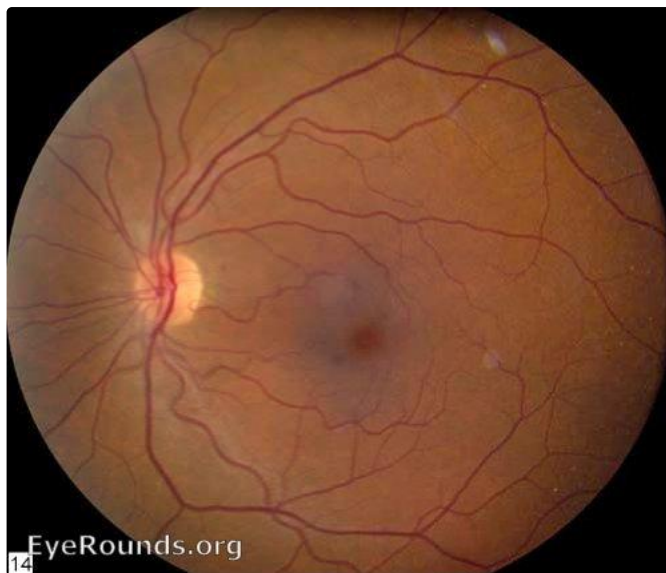
Category(ies): Retina

Contributor: Thomas A. Weingeist, PhD, MD



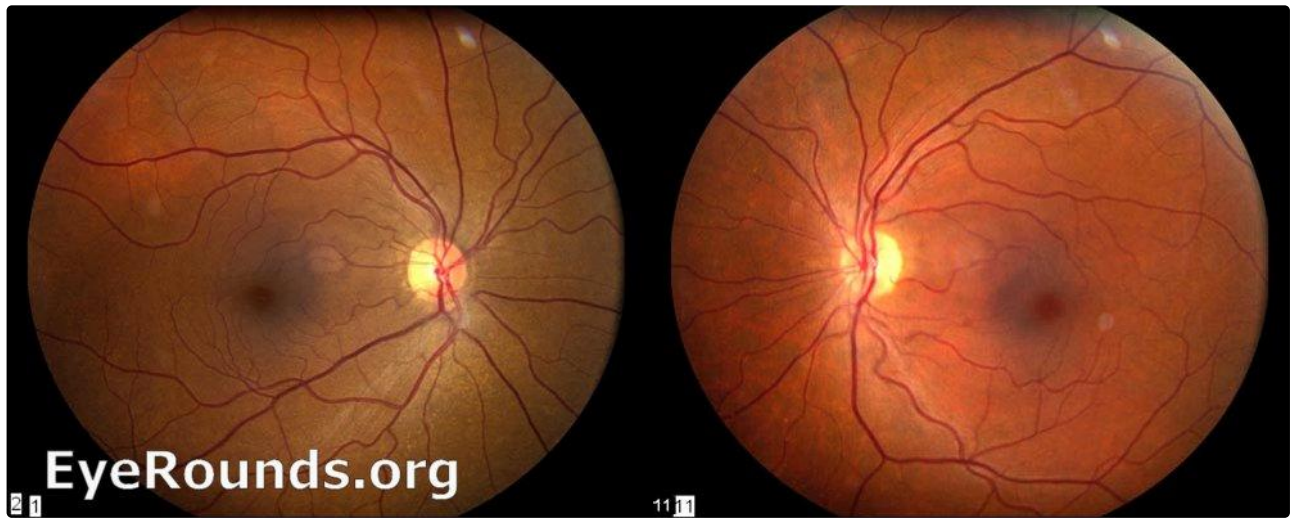
Right Eye, diffuse nevus of the choroid

[Enlarge](#) [Download](#)



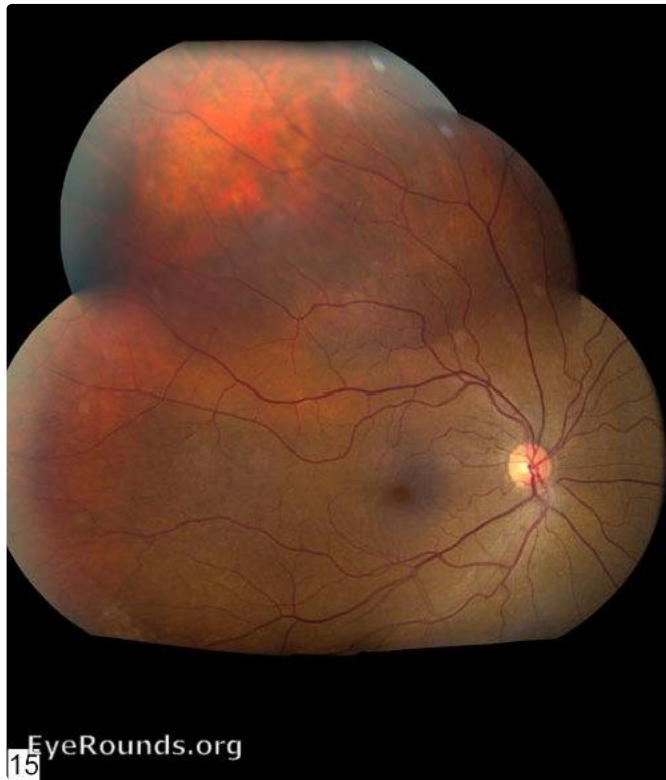Left Eye, normal fundus

[Enlarge](#) [Download](#)



both eyes, comparison of fundi

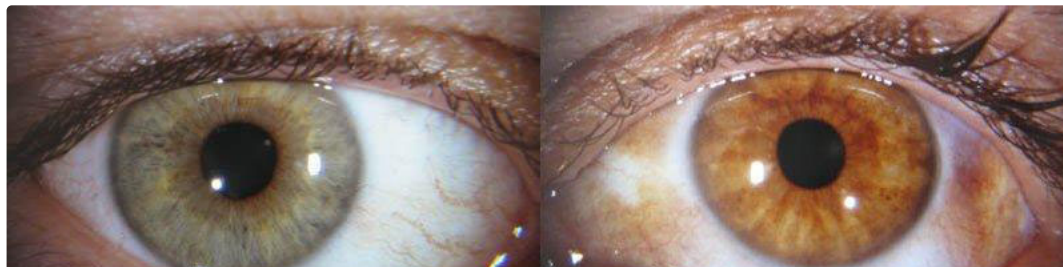[Enlarge](#) [Download](#)



Montage of diffuse choroidal nevus

[Enlarge](#) [Download](#)

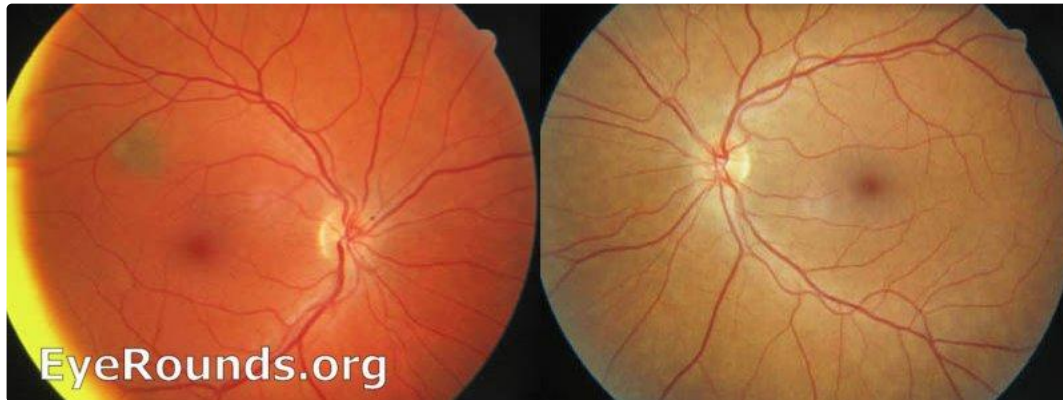Contributor: [Andrew Doan, MD, PhD](#)



Unilateral pigmentation of the left eye and fundus. Patients have higher risk of ocular melanoma and glaucoma.

[Enlarge](#)

[Download](#)



[Enlarge](#)

[Download](#)

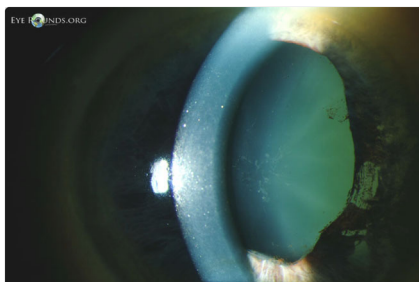
Image Permissions:



Ophthalmic Atlas Images by [EyeRounds.org](#), [The University of Iowa](#) are licensed under a [Creative Commons Attribution-NonCommercial-NoDerivs 3.0 Unported License](#).



Related Articles



[Related Atlas Entry: Oculodermal melanocytosis \(nevus of Ota\)](#)

Address

University of Iowa
Roy J. and Lucille A. Carver College

Legal

Related Links

[Cataract Surgery for Greenhorns](#)
[EyeTransillumination](#)

EyeRounds Social Media

of Medicine
Department of Ophthalmology and
Visual Sciences
200 Hawkins Drive
Iowa City, IA 52242

[Support Us](#)

Copyright © 2019 The University of
Iowa. All Rights Reserved
[Report an issue with this page](#)
[Web Privacy Policy](#) |
[Nondiscrimination Statement](#)

[Gonioscopy.org](#)
[Iowa Glaucoma Curriculum](#)
[Iowa Wet Lab](#)
[Patient Information](#)
[Stone Rounds](#)
[The Best Hits Bookshelf](#)

Follow



[Receive notification of new cases,
sign up here](#)
[Contact Us](#)
[Submit a Suggestion](#)