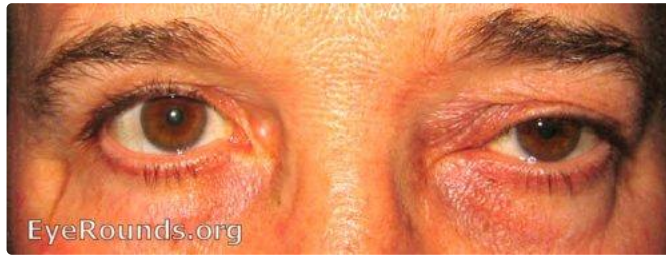


EyeRounds.org

Orbital lymphoma

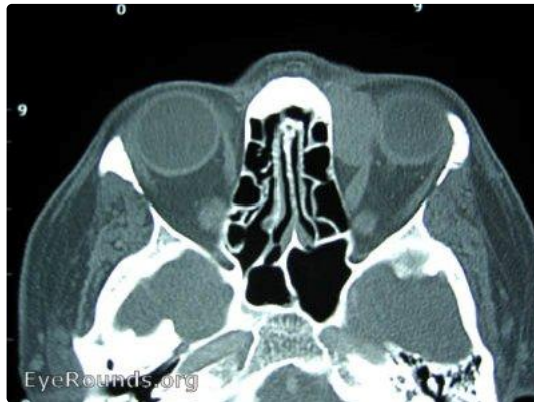Category(ies): Oculoplastics

Contributor: [Andrew Doan, MD, PhD](#)



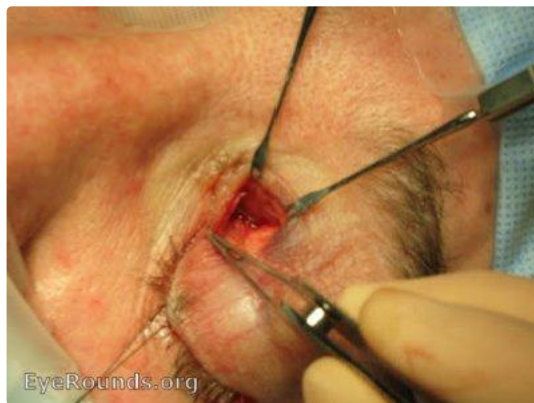1) Unilateral proptosis (painless), mechanical ptosis OS, and medial canthal mass.

[Enlarge](#) [Download](#)



2) Axial CT scan without contrast shows hypodense mass in the medial orbit.

[Enlarge](#) [Download](#)



3) Anterior orbitotomy for incisional biopsy.

[Enlarge](#) [Download](#)

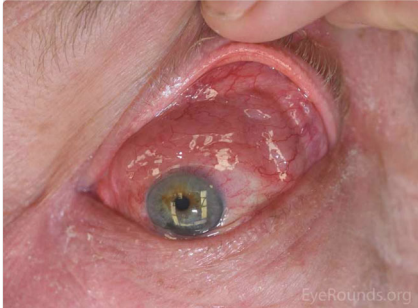Image Permissions:



Ophthalmic Atlas Images by [EyeRounds.org](#), [The University of Iowa](#) are licensed under a [Creative Commons Attribution-NonCommercial-NoDerivs 3.0 Unported License](#).



Related Articles



[Related Case: Orbital Lymphoma](#)

Address

University of Iowa
Roy J. and Lucille A. Carver College
of Medicine
Department of Ophthalmology and
Visual Sciences
200 Hawkins Drive
Iowa City, IA 52242

[Support Us](#)

Legal

Copyright © 2019 The University of
Iowa. All Rights Reserved
[Report an issue with this page](#)
[Web Privacy Policy](#) |
[Nondiscrimination Statement](#)

Related Links

[Cataract Surgery for Greenhorns](#)
[EyeTransillumination](#)
[Gonioscopy.org](#)
[Iowa Glaucoma Curriculum](#)
[Iowa Wet Lab](#)
[Patient Information](#)
[Stone Rounds](#)
[The Best Hits Bookshelf](#)

EyeRounds Social Media

Follow



Receive notification of new cases,
[sign up here](#)
[Contact Us](#)
[Submit a Suggestion](#)