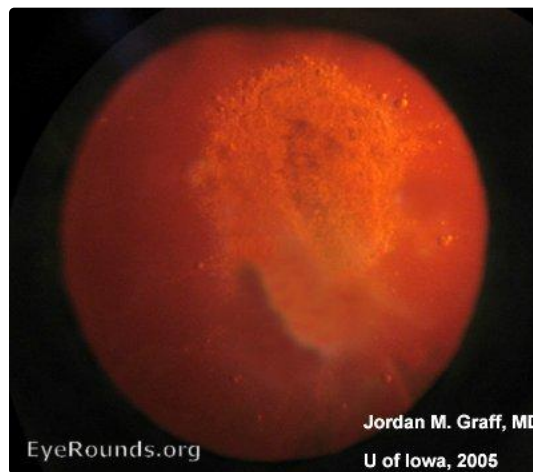


Posterior subcapsular cataract--retroillumination

Category(ies): Cataract

Contributor: [Jordan Graff, MD](#)

Photographer: Susan J. Wright



Posterior subcapsular plaque - red reflex

[Enlarge](#) [Download](#)

Image Permissions:



Ophthalmic Atlas Images by [EyeRounds.org](#), [The University of Iowa](#) are licensed under a [Creative Commons Attribution-NonCommercial-NoDerivs 3.0 Unported License](#).

Address

University of Iowa
Roy J. and Lucille A. Carver College
of Medicine
Department of Ophthalmology and
Visual Sciences

Legal

Copyright © 2019 The University of
Iowa. All Rights Reserved
Report an issue with this page
Web Privacy Policy |
Nondiscrimination Statement

Related Links

Cataract Surgery for Greenhorns
EyeTransillumination
Gonioscopy.org
Iowa Glaucoma Curriculum
Iowa Wet Lab

EyeRounds Social Media

Follow



200 Hawkins Drive
Iowa City, IA 52242

[Support Us](#)

[Patient Information](#)
[Stone Rounds](#)
[The Best Hits Bookshelf](#)

[Receive notification of new cases,
sign up here](#)
[Contact Us](#)
[Submit a Suggestion](#)