

## Pseudodendrites

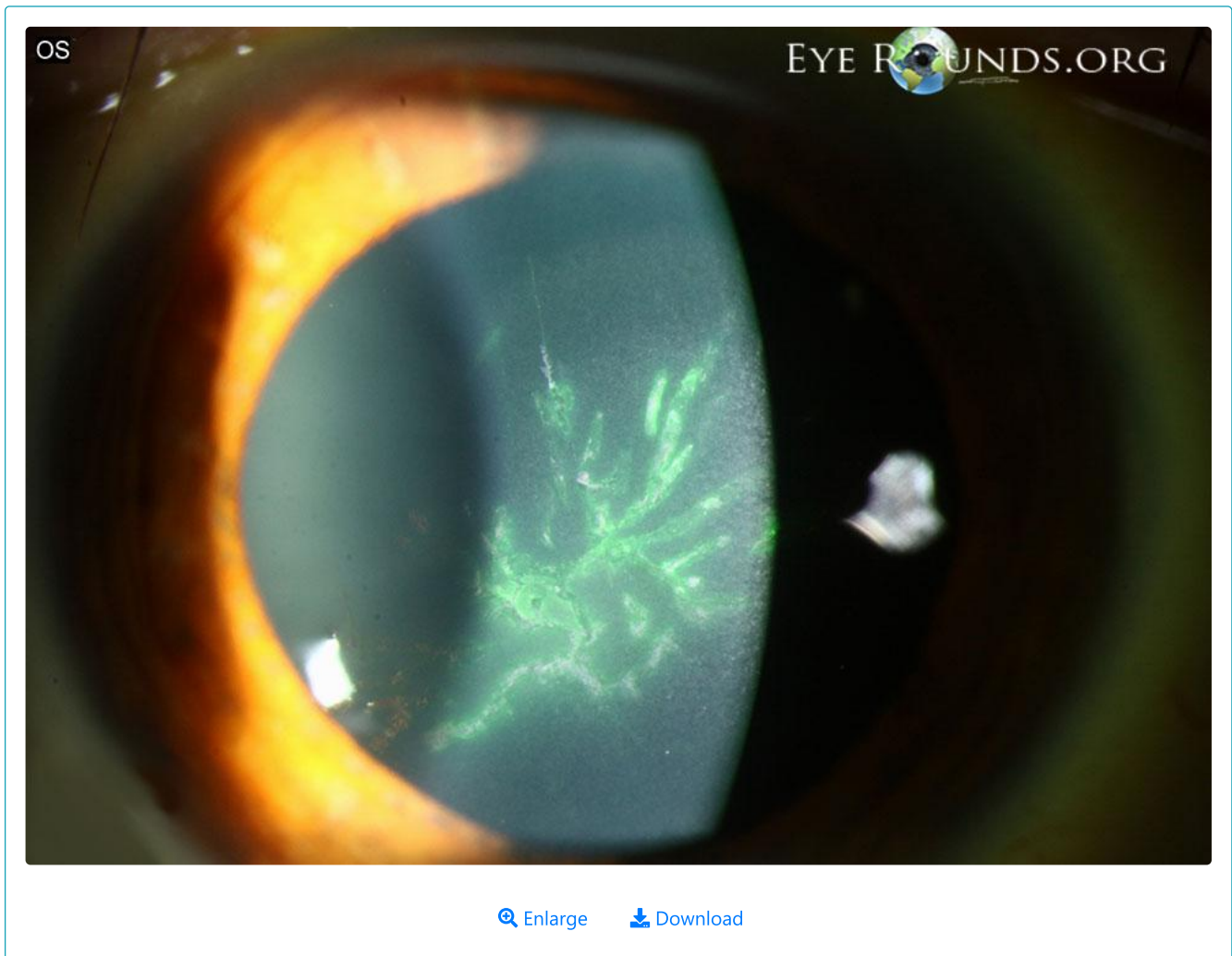
Category(ies): Cornea

Contributor: [Jeffrey Welder, MD](#)

Photographer: Brice Critser, CRA



51-year-old male presented with herpes zoster epithelial keratitis with pseudodendrites of the right eye in the setting of shingles in the right V1 distribution.



### Image Permissions:



Ophthalmic Atlas Images by [EyeRounds.org](#), [The University of Iowa](#) are licensed under a [Creative Commons Attribution-NonCommercial-NoDerivs 3.0 Unported License](#).

## Address

University of Iowa  
Roy J. and Lucille A. Carver College  
of Medicine  
Department of Ophthalmology and  
Visual Sciences  
200 Hawkins Drive  
Iowa City, IA 52242

[Support Us](#)

## Legal

Copyright © 2019 The University of  
Iowa. All Rights Reserved  
[Report an issue with this page](#)  
[Web Privacy Policy](#) |  
[Nondiscrimination Statement](#)

## Related Links

[Cataract Surgery for Greenhorns](#)  
[EyeTransillumination](#)  
[Gonioscopy.org](#)  
[Iowa Glaucoma Curriculum](#)  
[Iowa Wet Lab](#)  
[Patient Information](#)  
[Stone Rounds](#)  
[The Best Hits Bookshelf](#)

## EyeRounds Social Media

Follow



Receive notification of new cases,  
[sign up here](#)

[Contact Us](#)

[Submit a Suggestion](#)