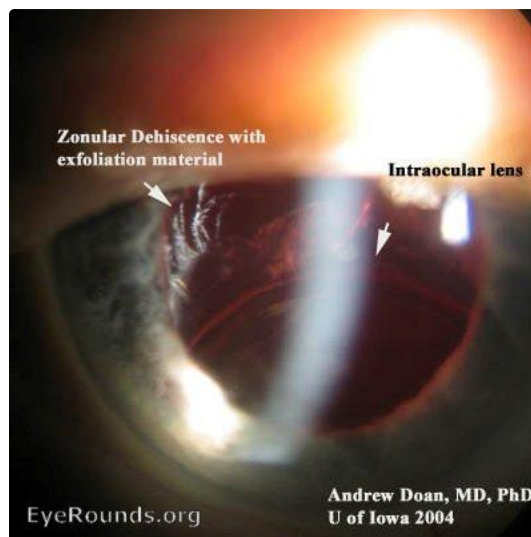


## Pseudoexfoliation zonular dehiscence

Category(ies): Cataract

Contributor: [Andrew Doan, MD, PhD](#)



Patient with pseudoexfoliation syndrome who had a cataract extraction and placement of an intraocular lens. Many years later, there was zonular dehiscence.

[Enlarge](#) [Download](#)

### Image Permissions:



Ophthalmic Atlas Images by [EyeRounds.org, The University of Iowa](#) are licensed under a [Creative Commons Attribution-NonCommercial-NoDerivs 3.0 Unported License](#).

### Address

University of Iowa  
Roy J. and Lucille A. Carver College  
of Medicine

### Legal

Copyright © 2019 The University of  
Iowa. All Rights Reserved  
Report an issue with this page

### Related Links

Cataract Surgery for Greenhorns  
EyeTransillumination  
Gonioscopy.org

### EyeRounds Social Media

Follow

Department of Ophthalmology and  
Visual Sciences  
200 Hawkins Drive  
Iowa City, IA 52242

[Support Us](#)

[Web Privacy Policy |  
Nondiscrimination Statement](#)

[Iowa Glaucoma Curriculum](#)  
[Iowa Wet Lab](#)  
[Patient Information](#)  
[Stone Rounds](#)  
[The Best Hits Bookshelf](#)



[Receive notification of new cases,  
sign up here](#)  
[Contact Us](#)  
[Submit a Suggestion](#)