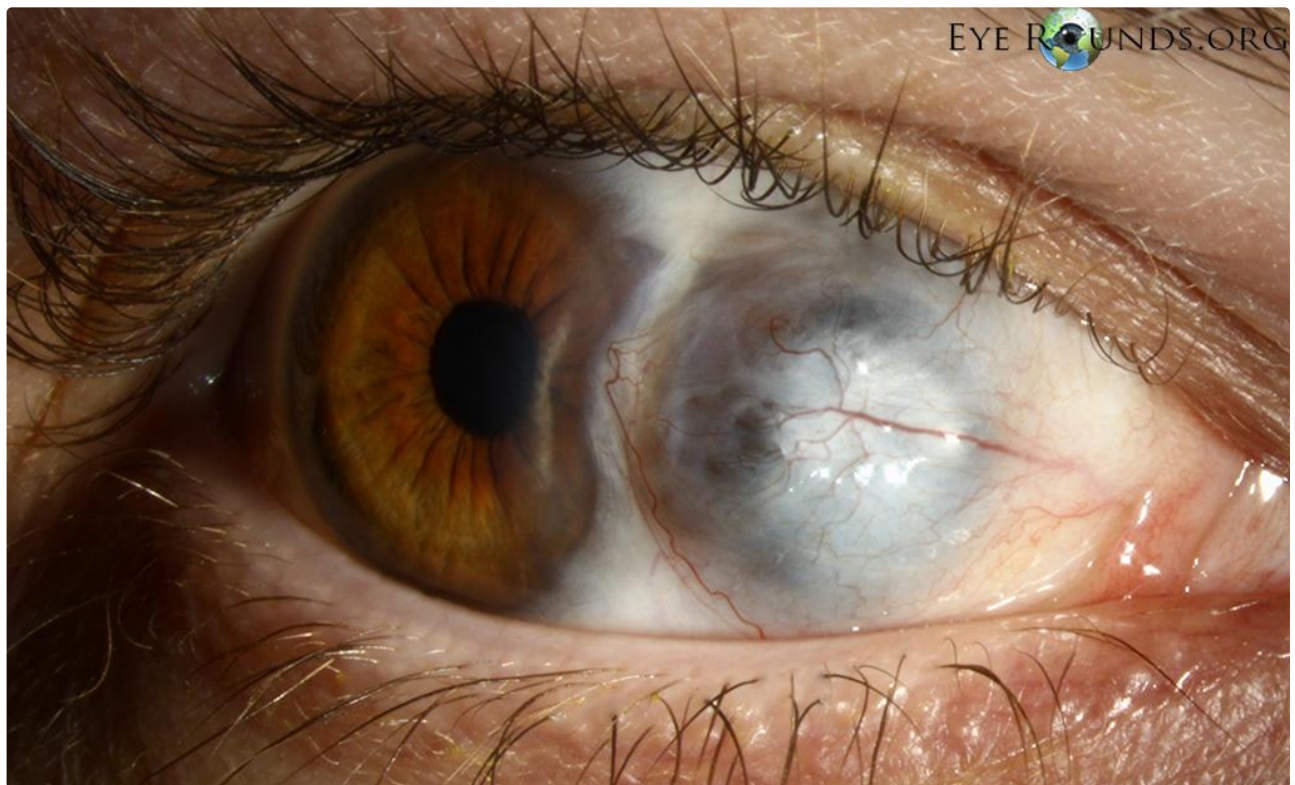

Scleromalacia

Category(ies): Cornea, External Disease

Contributor: [Matt Weed, MD](#)

Scleromalacia occurs in the setting of necrotizing scleritis. This patient has very thin medial sclera of the right eye, with pigmented uveal tissue readily visible. Note the domed elevation of the tissue. A systemic workup revealed Wegener's granulomatosis as the cause of this patient's necrotizing scleritis.



[Enlarge](#) [Download](#)

Image Permissions:

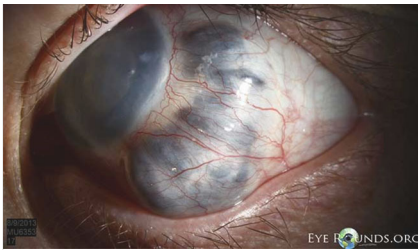


Ophthalmic Atlas Images by [EyeRounds.org](#), [The University of Iowa](#) are licensed under a [Creative Commons Attribution-NonCommercial-NoDerivs 3.0 Unported License](#).



Related Articles





[Related Atlas Entry: Scleromalacia and Anterior Staphyloma](#)

Address

University of Iowa
Roy J. and Lucille A. Carver College
of Medicine
Department of Ophthalmology and
Visual Sciences
200 Hawkins Drive
Iowa City, IA 52242

[Support Us](#)

Legal

Copyright © 2019 The University of
Iowa. All Rights Reserved
[Report an issue with this page](#)
[Web Privacy Policy](#) |
[Nondiscrimination Statement](#)

Related Links

[Cataract Surgery for Greenhorns](#)
[EyeTransillumination](#)
[Gonioscopy.org](#)
[Iowa Glaucoma Curriculum](#)
[Iowa Wet Lab](#)
[Patient Information](#)
[Stone Rounds](#)
[The Best Hits Bookshelf](#)

EyeRounds Social Media

Follow



Receive notification of new cases,
[sign up here](#)
[Contact Us](#)
[Submit a Suggestion](#)