

Thermal corneal burn

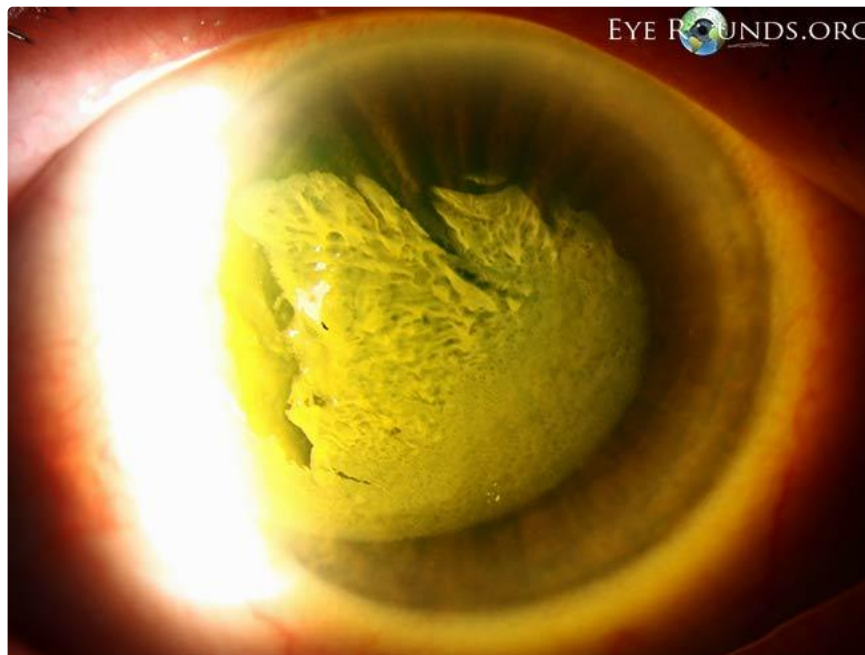Category(ies): Cornea

Contributor: Justin Risma, MD

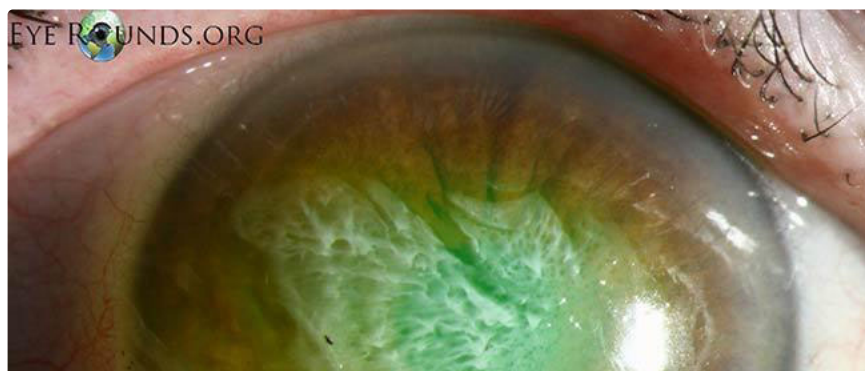
Photographer: Toni Venckus, CRA and Randy Verdick, FOPS

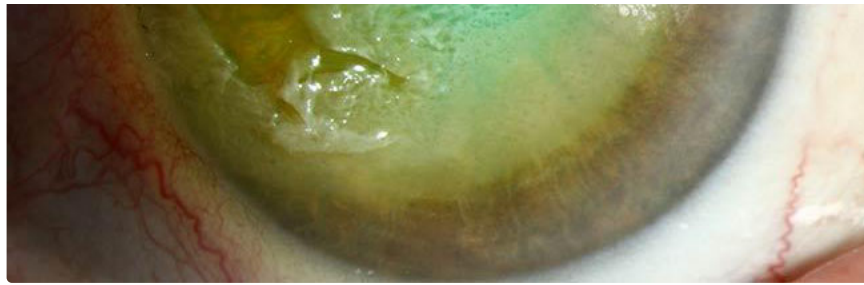

This 68-year-old female presented a few hours after accidentally touching her eye with a hot curling iron. Her visual acuity was 20/200 and she had a very large area of opacified, irregular corneal epithelium which was loose in some areas. We applied an antibiotic ointment and placed a pressure patch. The next day, her visual acuity was 20/70 and there was a moderate epithelial defect, but a large portion of previously opacified epithelium had completely cleared. We placed a bandage contact lens and treated her with topical antibiotic drops. At one week, her visual acuity had returned to baseline and her cornea appeared clear without stromal scarring.

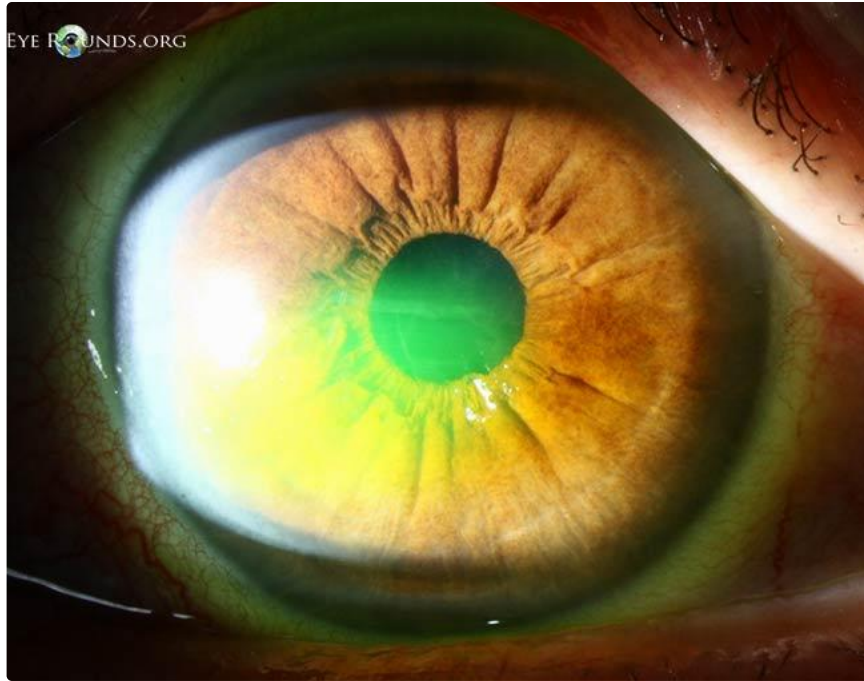

[Enlarge](#) [Download](#)





[Enlarge](#) [Download](#)



[Enlarge](#) [Download](#)

Image Permissions:



Ophthalmic Atlas Images by [EyeRounds.org](#), [The University of Iowa](#) are licensed under a [Creative Commons Attribution-NonCommercial-NoDerivs 3.0 Unported License](#).

Address

University of Iowa
Roy J. and Lucille A. Carver College
of Medicine
Department of Ophthalmology and
Visual Sciences
200 Hawkins Drive
Iowa City, IA 52242

Legal

Copyright © 2019 The University of
Iowa. All Rights Reserved
Report an issue with this page
Web Privacy Policy |
Nondiscrimination Statement

Related Links

Cataract Surgery for Greenhorns
EyeTransillumination
Gonioscopy.org
Iowa Glaucoma Curriculum
Iowa Wet Lab
Patient Information
Stone Rounds

EyeRounds Social Media

Follow



Receive notification of new cases,
sign up here

