

(<http://medicine.uiowa.edu/eye/>)

Ophthalmology and Visual Sciences  
(<http://medicine.uiowa.edu/eye/>)

Eye  ROUNDS.org

([../index.htm](http://medicine.uiowa.edu/eye/eye-roun-1/index.htm))

# Orbital Compartment Syndrome in a Burn Patient

56-year-old man with full-thickness burns involving the face presenting with bilateral proptosis, non-reactive pupils, and severely elevated intraocular pressures

**Authors:** Kelly H. Yom, BA; Anthony P. Mai, BS; Christopher R. Fortenbach, MD, PhD ([../bio/authors/Fortenbach-Christopher.htm](http://medicine.uiowa.edu/eye-roun-1/bio/authors/Fortenbach-Christopher.htm)); Lucy A. Wibbenmeyer, MD; Kai Wang, PhD; Erin M. Shriver, MD ([../bio/authors/Shriver-Erin.htm](http://medicine.uiowa.edu/eye-roun-1/bio/authors/Shriver-Erin.htm))

Posted May 15, 2020

---

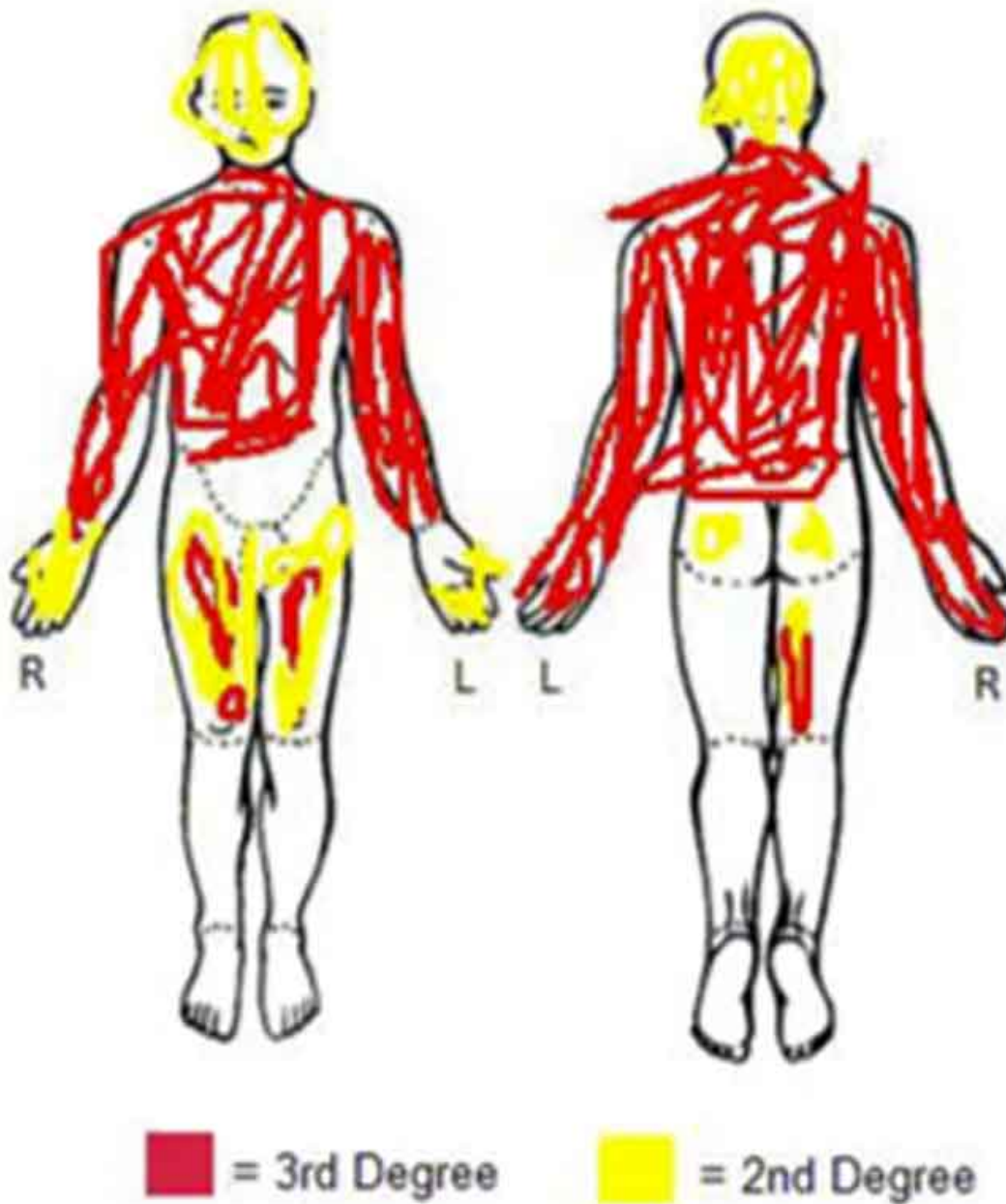
## INITIAL PRESENTATION

### Chief Complaint

Full thickness burns involving periorbital area

### History of Present Illness

A 56-year-old man was admitted to the burn service after suffering burns involving the face, torso, thighs, and upper extremities in a motor vehicle accident. At presentation, he had multiple rib fractures and full thickness burns encompassing 65% total body surface area (TBSA) and the patient required emergent intubation and fluid resuscitation, as well as escharotomy of the chest (Figure 1). Given burn involvement of the eyelids, ophthalmology was consulted 16 hours after admission to assess for further ocular involvement and management.



Total BSAB: 65%

EyeRounds.org

(../cases-i/case297/burn-diagram-LRG.jpg)

**Figure 1.** Burn diagram demonstrating location and extent of the patient's burn injuries. Note that injuries encompass a large total body surface area (65%), are mostly full thickness, and involve the periorbital region.

## Past Ocular History

- None

## Past Medical History

- Non-contributory

## Pertinent Past Surgical History

- Non-contributory

## Medications

- Atorvastatin, lisinopril, metformin, omeprazole

## Allergies (Reaction)

- NKDA

## Family History

- Non-contributory

## Social History

- Unable to obtain due to patient sedation and intubation

## Review of Systems

- Unable to obtain due to patient sedation and intubation

# OCULAR EXAMINATION

## Visual Acuity

- Unable to assess

## Ocular Motility/Alignment

- Unable to assess

## Intraocular Pressure (IOP) by Tonopen

- OD: 81 mmHg
- OS: 86 mmHg

## Pupils

- OD: 3mm (dark) → 3mm (light), round, non-reactive
- OS: 3mm (dark) → 3mm (light), round, non-reactive

## Confrontation Visual Fields

- Unable to assess

## External

Severe 2nd degree facial burns involving eyebrows and periorbital area OU

## Slit Lamp Exam

- Lids/lashes: firm, tight, and edematous upper and lower eyelids, significant proptosis OU
- Conjunctiva/sclera: 2+ chemosis 360° without epithelial defect OU
- Cornea: clear OU
- Anterior chamber: deep and quiet OU
- Iris: normal OU
- Lens: clear OU
- Anterior vitreous: normal OU

## Dilated Fundus Exam

Deferred

## Differential Diagnosis

- Orbital compartment syndrome, secondary to:
  - Edema (secondary to resuscitation)
  - Retrobulbar hemorrhage (traumatic, post-operative, spontaneous)
  - Soft tissue emphysema
  - Traumatic asphyxia syndrome
- Orbital inflammation (thyroid ophthalmopathy, idiopathic orbital inflammatory syndrome, etc.)
- Vascular lesions (venous malformation, lymphatic malformation, carotid cavernous fistula, arterial aneurysm)
- Infection (orbital cellulitis)
- Orbital neoplasm

## CLINICAL COURSE

The patient's severely elevated intraocular pressures, acute proptosis, and lack of pupillary response in the setting of third-degree burns were consistent with orbital compartment syndrome (OCS) secondary to fluid resuscitation. The patient received a total of 29.7 liters of fluid in the first 24 hours following admission, which exceeded the Parkland formula recommendation (a means of estimating fluid resuscitation requirements in burn patients) by 13.3 liters.

In order to relieve orbital pressure and minimize resulting damage to ocular structures, the patient underwent emergency bilateral canthotomy and inferior cantholysis. Intraocular pressures remained elevated following the initial cantholysis; therefore, a subsequent bilateral superior cantholysis was performed. Intraocular pressures then fell and remained stable in the teens for the remainder of his admission. To further aid in reduction of intraocular pressure, the patient was given brimonidine, dorzolamide-timolol, and latanoprost drops following the procedure and for one week afterwards. Erythromycin ointment was applied three times daily to protect the cornea and conjunctiva, and the head of the bed was elevated to aid with fluid redistribution. Pupils remained unreactive to light following the procedure, but a nystagmus response to optokinetic drum was elicited bilaterally.

From a thermal injury perspective, no epithelial defects were appreciable on the cornea or conjunctiva. However, given the periorbital location and severity of his burns, he had a complicated and prolonged hospital course. During recovery, he developed cicatricial eyelid changes resulting in bilateral lagophthalmos and

persistent exposure keratopathy, which were addressed with multiple full-thickness grafts and reconstructive surgeries to the bilateral upper and lower eyelids. At the time of discharge three months after the initial injury, ophthalmologic exam revealed bilateral optic nerve pallor. The patient's best visual acuity was light perception OD and 20/7000 OS.

## DIAGNOSIS

Orbital compartment syndrome secondary to fluid resuscitation for extensive second- and third-degree burns

## DISCUSSION

Orbital compartment syndrome occurs due to rapid tissue expansion within the intraorbital space, usually from tissue swelling, fluid, or blood. Because the orbit is enclosed by inflexible bony structures and an eyelid complex tethered to the orbital rim, it is a fixed compartment with limited capacity to accommodate extra volume. As a result, intraorbital pressures increase dramatically and are transmitted to the globe and retrobulbar contents. Like other compartment syndromes, OCS causes ischemia by compression of arterial blood supply. If blood flow through the posterior ciliary and ophthalmic arteries is compromised for a significant period of time, this can permanently damage the optic nerve and retinal tissue, resulting in vision loss. Treatment requires immediate relief of pressure in order to avoid blindness, as irreversible injury occurs in as little as 60 minutes [1]. While this article focuses on OCS associated in burn patients, a general discussion of orbital compartment syndrome can be found at the EyeRounds Orbital Compartment Syndrome Curriculum here ([../tutorials/OCS/index.htm](http://tutorials/OCS/index.htm)).

Severe or extensive burn injuries are a known cause of compartment syndrome; this occurs not only due to increased vascular permeability after thermal and/or chemical tissue damage, but also as a sequela of the aggressive fluid resuscitation necessary for burn therapy [2]. This excess fluid can cause tissue swelling, extravasate into the orbit, and increase orbital pressures. Other causes of OCS include trauma resulting in retrobulbar hemorrhage or tissue emphysema, infection, orbital malignancy, or iatrogenic events such as surgery or retrobulbar injections.

### Etiology / Pathophysiology

Depending on the location and extent of their injuries, burn patients are often at risk for developing ocular sequelae from their burns. In addition to direct thermal or chemical damage to the eyelids and cornea, patients may develop complications such as infection, exposure keratopathy, or orbital compartment syndrome in the setting of extensive burns or burns involving the periorbital area [3-5]. OCS is relatively rare, but constitutes a true ophthalmologic emergency when it occurs.

In 1991, Evans was the first to document the association between OCS and large volume fluid resuscitation [6]. This initial case series described increased IOP measurements in three burn patients receiving aggressive fluid resuscitation. This relationship has since been corroborated by multiple studies, and the positive linear relationship between fluid resuscitation volume and peak IOP was later quantified by Singh et al., whose case series of 28 patients showed that fluid resuscitation volumes  $\geq 8.6$  ml / kg / %TBSA increased the risk of requiring emergent orbital decompression by 4.4 times [2].

Fluid resuscitation is a cornerstone of burn management. Large burns (those encompassing >30% of TBSA) severely compromise skin integrity and induce an inflammatory-mediated capillary leak syndrome, resulting in copious evaporative water loss [7]. Therefore, vigorous fluid resuscitation must be employed in order to prevent systemic hypovolemia and hypotension. However, fluid resuscitation has also been shown to increase the risk for compartment syndromes of the chest, abdomen, and extremities in burn patients [8-10]. It follows that the orbit is another possible site for compartment syndrome during fluid resuscitation, as the rigid bony walls of the

orbit and the eyelid complex serve to create a closed space that cannot accommodate significant volume expansion [11]. Elevated pressures compress arterial blood flow, increase peripheral vascular resistance, diminish perfusion of the optic nerve and retina, and cause ocular dysfunction and ischemia [12].

## Signs / Symptoms

The hallmark of OCS is severe orbital congestion, which may lead to acute proptosis, markedly elevated intraocular pressure (IOP, >35 mmHg), ophthalmoplegia, and fixed dilated pupils or a relative afferent pupillary defect (RAPD) [13]. Patients may report subjective visual symptoms such as acute vision loss or diplopia as a result of compression and ischemia of ocular tissues. The exam commonly demonstrates tight eyelids that are not distractible from the globe, resistance to retropulsion, and periocular edema.

## Testing and Imaging / Work-up

Given the emergent nature of OCS, prompt diagnosis is critical for salvaging visual function. The diagnosis must be made clinically, and findings outlined above in the setting of trauma, burns, infection, or a post-operative time period should engender a high index of suspicion for this condition. If possible, time to intervention should be within 90-120 minutes from injury to prevent permanent vision loss [12, 14].

Acutely, there is often insufficient time to obtain radiographic studies, as this will delay intervention and put vision at risk. Thus, imaging is not routinely used to affect clinical decision-making. If the etiology of OCS is unclear or if initial decompression fails, CT may identify the underlying pathology and guide further treatment. Common radiological findings include globe tenting and proptosis. Depending on the cause of OCS, retroorbital hemorrhage, edema, or mass lesions may be seen as well.

Regarding screening for OCS in acute burn patients, bedside tonometry with a Tonopen can be used to test IOP, which is almost always >35 mmHg in OCS. IOP serves as a surrogate measure of intraorbital pressure, and serial tonometry should be performed to monitor changes in IOP throughout the course of initial burn management. (See "A Systems-Based Approach to Management" for further discussion.)

## Treatment / Management / Guidelines

There should be no delay in initiating treatment once OCS has been diagnosed. The goal of intervention is to decompress orbital contents and restore blood flow to the retina and optic nerve. This is accomplished emergently at the bedside with a lateral canthotomy and inferior cantholysis, which allows anterior displacement of the globe and release of orbital compartment pressure [12]. The EyeRounds Orbital Compartment Syndrome Curriculum demonstrating lateral canthotomy and inferior cantholysis can be found here ([../tutorials/lateral-canthotomy-cantholysis.htm](http://tutorials/lateral-canthotomy-cantholysis.htm)). If IOP remains elevated, a superior cantholysis can then be performed to further relieve pressure [15]. Alternatively, a vertical eyelid split or paracanthal decompression can be performed in place of a traditional lateral canthotomy and cantholysis [16, 17]. These "one-snip" procedures are easily performed, which may make them more accessible to the non-ophthalmologist and reduce delays in surgical decompression [17]. However, while they seem to be effective in decompressing the orbit, these techniques may also increase the risk of exposure keratopathy, necessitating repair in a more timely fashion. More extensive orbital decompression under general anesthesia may be needed for surgical decompression of the orbit if pressures are refractory to bedside cantholysis or eyelid split [18].

Medical therapy can be used as adjunctive treatment to canthotomy and cantholysis, but is rarely effective in achieving decompression alone. Intravenous acetazolamide, IV mannitol, and topical glaucoma drops such as  $\alpha_2$  agonists, beta blockers, carbonic anhydrase inhibitors, or prostaglandin analogues all function to decrease IOP by small amounts. Other interventions include elevating the head of the bed, ice packs to reduce edema, and potentially corticosteroids [13].

# A Systems-Based Approach to Management

Because prognosis is highly dependent on time elapsed until treatment, optimal management of OCS in burn victims first necessitates prompt identification of patients at risk. It is imperative that burn victims be closely monitored for OCS. Previously, Singh and colleagues recommended that daily IOP checks should be performed for three days for burn patients receiving  $> 5.5 \text{ ml / kg / \%TBSA}$  in the first 24 hours of resuscitation [2]. However, a recent retrospective analysis of burn victims at the University of Iowa by Mai *et al.* found that OCS can develop rapidly within a matter of hours, even in patients receiving low volume or no fluid resuscitation [19]. These findings suggest that earlier and more frequent IOP checks may be necessary to effectively detect and treat OCS in susceptible burn patients, especially within the first 24 hours of admission when resuscitation volumes are the greatest.

While the presence of periocular burns, subjective visual symptoms, or tight eyelids on examination necessitates immediate ophthalmology evaluation, additional risk factors for elevated IOPs were uncovered by Mai *et al.* to help identify those most at risk for OCS and vision loss [19]. These risk factors include large burn surface area, large Parkland formula-calculated fluid volumes, and volumes in excess of the Ivy Index (traditionally used to screen patients at risk for abdominal compartment syndrome) [19]. Patients presenting with these risk factors should be evaluated for OCS early in their course with frequent serial IOP evaluations. The presence of chemosis, the use of albumin, and the use of vasopressors may also be associated with the development of OCS, although these measures remain to be validated in larger studies (Table 1.) [19].

OCS Associated Factors in Burn Patients
<p><b>Significant Risk Factors</b> &gt; 50% TBSA burned* &gt; 15 L Parkland formula calculation* Ivy Index: fluid resuscitation &gt; 250 ml/kg</p> <p><b>Likely Risk Factors</b> Vasopressor use Albumin use Chemosis</p>

**Table 1.** Factors associated with the development of orbital compartment syndrome in burn patients. Patient cohorts with increased intraocular pressures tend to have higher %TBSA burns, higher Parkland formula calculations, and fluid resuscitation volumes in excess of the Ivy Index when compared to cohorts without increased intraocular pressures [19].

\*Marked risk factors were present for all but one patient in the cohort of patients with elevated IOP in the Mai *et al.* study.

<p><b>ETIOLOGY</b></p> <ul style="list-style-type: none"> <li>• Rare complication of burns, especially periocular or large TBSA burns</li> <li>• Associated with large volume fluid resuscitation</li> <li>• Excess fluid and deranged vascular function causes periocular edema to accumulate in the enclosed orbital compartment and compress vital ocular structures</li> <li>• Can lead to ischemia of ocular tissues and loss of vision</li> </ul>	<p><b>SIGNS</b></p> <ul style="list-style-type: none"> <li>• Proptosis</li> <li>• Elevated IOP (&gt;35 mmHg)</li> <li>• Ophthalmoplegia</li> <li>• RAPD, fixed / dilated pupils</li> <li>• Tight eyelids that are not distractible from globe, resistance to retro-pulsion</li> </ul>
<p><b>SYMPTOMS</b></p> <ul style="list-style-type: none"> <li>• Acutely decreased vision</li> <li>• Diplopia</li> <li>• Pain / pressure</li> </ul>	<p><b>TREATMENT/MANAGEMENT</b></p> <ul style="list-style-type: none"> <li>• Serial IOP checks</li> <li>• Emergent canthotomy / cantholysis</li> <li>• Orbital decompression</li> </ul>

1. Hayreh SS, Kolder HE, Weingeist TA. Central retinal artery occlusion and retinal tolerance time. *Ophthalmology* 1980;87(1):75-78. <https://pubmed.gov/6769079> (<https://pubmed.gov/6769079>). DOI: 10.1016/s0161-6420(80)35283-4
2. Singh CN, Klein MB, Sullivan SR, Sires BS, Hutter CM, Rice K, Jian-Amadi A. Orbital compartment syndrome in burn patients. *Ophthalmic Plast Reconstr Surg* 2008;24(2):102-106. <https://pubmed.gov/18356713> (<https://pubmed.gov/18356713>). DOI: 10.1097/IOP.0b013e318163d2fb
3. Bouchard CS, Morno K, Perkins J, McDonnell JF, Dicken R. Ocular complications of thermal injury: a 3-year retrospective. *J Trauma* 2001;50(1):79-82. <https://pubmed.gov/11231674> (<https://pubmed.gov/11231674>). DOI: 10.1097/00005373-200101000-00014
4. Fitzgerald O'Connor E, Frew Q, Din A, Pleat J, Ashraff S, Ghazi-Nouri S, El-Muttardi N, Philp B, Dziewulski P. Periorbital burns - a 6 year review of management and outcome. *Burns* 2015;41(3):616-623. <https://pubmed.gov/25406883> (<https://pubmed.gov/25406883>). DOI: 10.1016/j.burns.2014.08.022
5. Spencer T, Hall AJ, Stawell RJ. Ophthalmologic sequelae of thermal burns over ten years at the Alfred Hospital. *Ophthalmic Plast Reconstr Surg* 2002;18(3):196-201. <https://pubmed.gov/12021650> (<https://pubmed.gov/12021650>). DOI: 10.1097/00002341-200205000-00008
6. Evans LS. Increased intraocular pressure in severely burned patients. *Am J Ophthalmol* 1991;111(1):56-58. <https://pubmed.gov/1985491> (<https://pubmed.gov/1985491>). DOI: 10.1016/s0002-9394(14)76897-7
7. Busche MN, Roettger A, Herold C, Vogt PM, Rennekampff HO. Evaporative Water Loss in Superficial to Full Thickness Burns. *Ann Plast Surg* 2016;77(4):401-405. <https://pubmed.gov/27387468> (<https://pubmed.gov/27387468>). DOI: 10.1097/sap.0000000000000845
8. Block EF, Dobo S, Kirton OC. Compartment syndrome in the critically injured following massive resuscitation: case reports. *J Trauma* 1995;39(4):787-791. <https://pubmed.gov/7473979> (<https://pubmed.gov/7473979>). DOI: 10.1097/00005373-199510000-00036
9. Boehm D, Schroder C, Arras D, Siemers F, Siafliakis A, Lehnhardt M, Dadras M, Hartmann B, Kuepper S, Czaja KU, Kneser U, Hirche C. Fluid Management as a Risk Factor for Intra-abdominal Compartment Syndrome in Burn Patients: A Total Body Surface Area-Independent Multicenter Trial Part I. *J Burn Care Res* 2019;40(4):500-506. <https://pubmed.gov/30918949> (<https://pubmed.gov/30918949>). DOI: 10.1093/jbcr/irz053
10. Harrell BR, Miller S. Abdominal Compartment Syndrome as a Complication of Fluid Resuscitation. *Nurs Clin North Am* 2017;52(2):331-338. <https://pubmed.gov/28478881> (<https://pubmed.gov/28478881>). DOI: 10.1016/j.cnur.2017.01.010
11. Dutton JJ. Atlas of clinical and surgical orbital anatomy. 2011.
12. Stiff HA, Chung AT, Benage M, Janson BJ, Fox AR, Oetting TA, Shriver EM. Orbital Compartment Syndrome Curriculum. *EyeRounds.com* 2018.



13. Lima V, Burt B, Leibovitch I, Prabhakaran V, Goldberg RA, Selva D. Orbital compartment syndrome: the ophthalmic surgical emergency. *Surv Ophthalmol* 2009;54(4):441-449. <https://PubMed.gov/19539832> (<https://PubMed.gov/19539832>). DOI: 10.1016/j.survophthal.2009.04.005
14. Hislop WS, Dutton GN. Retrobulbar haemorrhage: can blindness be prevented? *Injury* 1994;25(10):663-665. <https://PubMed.gov/7829190> (<https://PubMed.gov/7829190>). DOI: 10.1016/0020-1383(94)90009-4
15. Haubner F, Jagle H, Nunes DP, Schleder S, Cvetkova N, Kuhnel T, Gassner HG. Orbital compartment: effects of emergent canthotomy and cantholysis. *Eur Arch Otorhinolaryngol* 2015;272(2):479-483. <https://PubMed.gov/25115315> (<https://PubMed.gov/25115315>). DOI: 10.1007/s00405-014-3238-5
16. Kersten RC, Kulwin DR. Vertical lid split orbitotomy revisited. *Ophthalmic Plast Reconstr Surg* 1999;15(6):425-428. <https://PubMed.gov/10588252> (<https://PubMed.gov/10588252>). DOI: 10.1097/00002341-199911000-00011
17. Blandford AD, Young JM, Arepalli S, Li A, Hwang CJ, Perry JD. Paracanthal "One-Snip" Decompression in a Cadaver Model of Retrobulbar Hemorrhage. *Ophthalmic Plast Reconstr Surg* 2018;34(5):428-431. <https://PubMed.gov/29369152> (<https://PubMed.gov/29369152>). DOI: 10.1097/iop.0000000000001032
18. McCallum E, Keren S, Lapira M, Norris JH. Orbital Compartment Syndrome: An Update With Review Of The Literature. *Clin Ophthalmol* 2019;13:2189-2194. <https://PubMed.gov/31806931> (<https://PubMed.gov/31806931>). DOI: 10.2147/opth.S180058
19. Mai AP, Fortenbach CR, Wibbenmeyer LA, Wang K, Shriver EM. Preserving Vision: Rethinking Burn Patient Monitoring to Prevent Orbital Compartment Syndrome. *J Burn Care Res* 2020;10.1093/jbcr/iraa053. <https://PubMed.gov/32246146> (<https://PubMed.gov/32246146>). DOI: 10.1093/jbcr/iraa053

---

## Suggested Citation Format

Yom KH, Mai AP, Fortenbach CR, Wibbenmeyer LA, Wang K, Shriver EM. Orbital Compartment Syndrome in a Burn Patient. *EyeRounds.org*. Posted May 15, 2020; Available from <https://EyeRounds.org/cases/297-OCS-in-burn-patient.htm>

last updated: 05/15/2020

Share this page:

---

University of Iowa Carver College of Medicine  
Department of Ophthalmology & Visual Sciences  
200 Hawkins Dr.  
Iowa City, IA 52242

Web Privacy Policy (<http://www.uiowa.edu/homepage/online-privacy-information>) | Nondiscrimination Statement (<http://opsmanual.uiowa.edu/community-policies/nondiscrimination-statement>)

**Directory (<https://www.dna.its.uiowa.edu/Whitepages/>) | A-Z Search (<http://www.uiowa.edu/a-z>) |  
About Iowa (<http://www.uiowa.edu/homepage/about-university>) | Contact Us  
(<http://www.uiowa.edu/homepage/about-university>) | Calendars  
(<http://www.uiowa.edu/homepage/calendars>) | Privacy Information  
(<http://www.uiowa.edu/homepage/online-privacy-information>)**

copyright ©2016 The University of Iowa.