

# EyeRounds.org

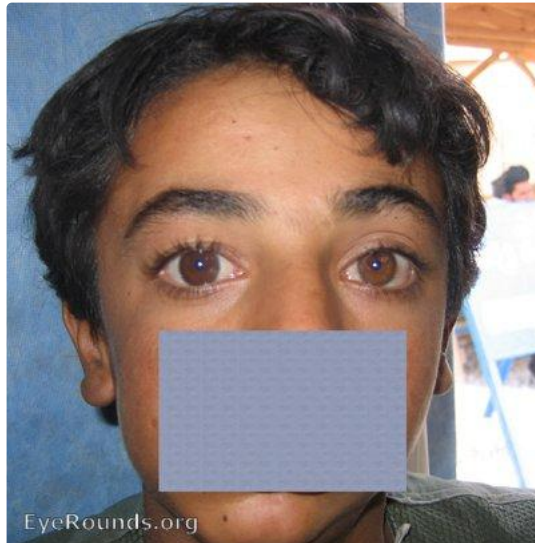## Congenital Glaucoma

**Category(ies):** Glaucoma

**Contributor:** David W. Hayes, DO

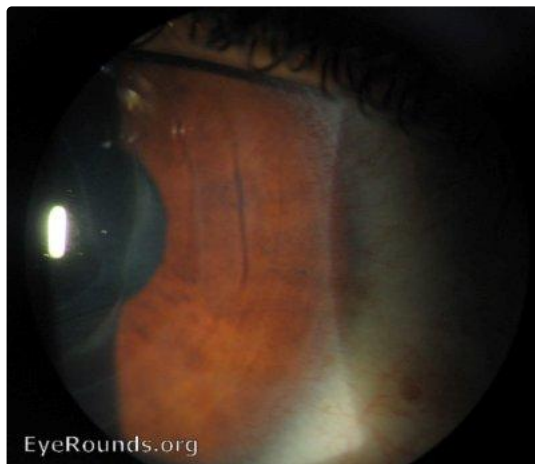
I am a Navy flight surgeon currently serving my second tour here in SW Asia. Due to my interest in Ophthalmology I am working closely with an Egyptian field hospital where I see about 45 local Afghani's a day. As you can imagine in a country of 30 million and very few ophthalmologist, the pathology is amazing.

The EyeRounds Editorial Board welcomes this submission of US NAVY Flight Surgeon Dr. David Hayes, practicing abroad:



"Congenital glaucoma in a 11-year-old Afghani boy. Please note the bilateral buphthalmos."

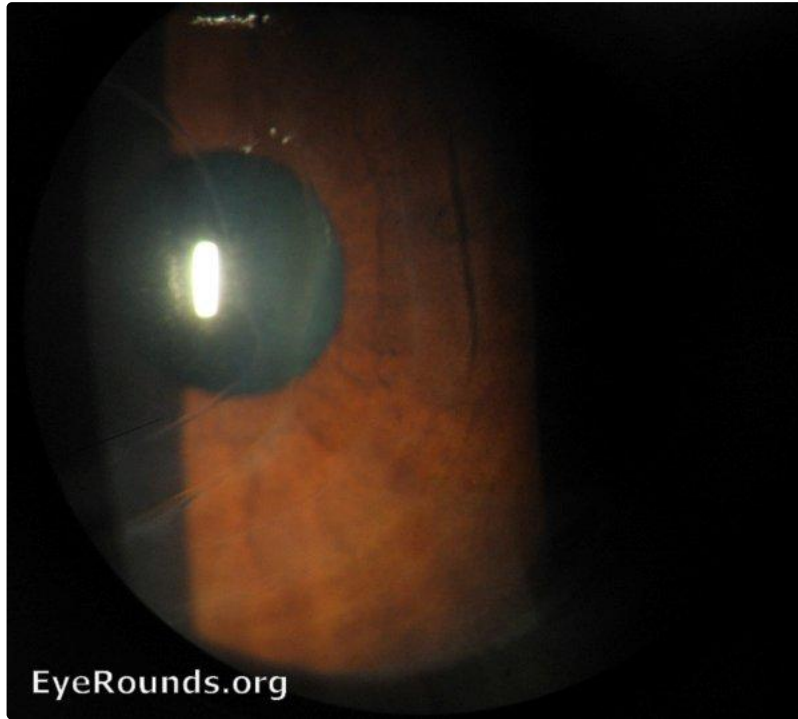
[Enlarge](#) [Download](#)



Primary congenital glaucoma (also termed "Infantile Glaucoma") is associated with Haab striae, seen here in slit lamp view of the cornea.

[Enlarge](#)

[Download](#)



Larger and closer view provides greater detail of these extensive, circumferential breaks in Descemet's membrane.

[Enlarge](#)

[Download](#)

### Image Permissions:



Ophthalmic Atlas Images by [EyeRounds.org](#), [The University of Iowa](#) are licensed under a [Creative Commons Attribution-NonCommercial-NoDerivs 3.0 Unported License](#).



### Related Articles

#### Address

University of Iowa  
Roy J. and Lucille A. Carver College  
of Medicine  
Department of Ophthalmology and  
Visual Sciences  
200 Hawkins Drive  
Iowa City, IA 52242

[Support Us](#)

#### Legal

Copyright © 2019 The University of  
Iowa. All Rights Reserved  
[Report an issue with this page](#)  
[Web Privacy Policy](#) |  
[Nondiscrimination Statement](#)

#### Related Links

[Cataract Surgery for Greenhorns](#)  
[EyeTransillumination](#)  
[Gonioscopy.org](#)  
[Iowa Glaucoma Curriculum](#)  
[Iowa Wet Lab](#)  
[Patient Information](#)  
[Stone Rounds](#)  
[The Best Hits Bookshelf](#)

#### EyeRounds Social Media

Follow



Receive notification of new cases,  
[sign up here](#)  
[Contact Us](#)  
[Submit a Suggestion](#)