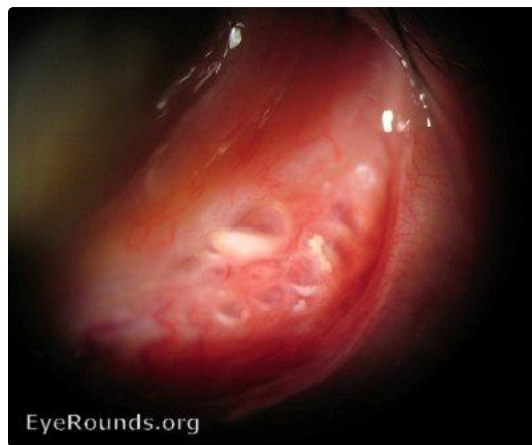


## Conjunctival concretions

Category(ies): Cornea, External Disease

Contributor: [Jordan Graff, MD](#)



Asymptomatic concretions within the inferior conjunctiva

[Enlarge](#) [Download](#)

### Image Permissions:



Ophthalmic Atlas Images by [EyeRounds.org, The University of Iowa](#) are licensed under a [Creative Commons Attribution-NonCommercial-NoDerivs 3.0 Unported License](#).

### Address

University of Iowa  
Roy J. and Lucille A. Carver College  
of Medicine  
Department of Ophthalmology and  
Visual Sciences  
200 Hawkins Drive  
Iowa City, IA 52242

### Legal

Copyright © 2019 The University of  
Iowa. All Rights Reserved  
[Report an issue with this page](#)  
[Web Privacy Policy](#) |  
[Nondiscrimination Statement](#)

### Related Links

[Cataract Surgery for Greenhorns](#)  
[EyeTransillumination](#)  
[Gonioscopy.org](#)  
[Iowa Glaucoma Curriculum](#)  
[Iowa Wet Lab](#)  
[Patient Information](#)  
[Stone Rounds](#)

### EyeRounds Social Media

Follow



Receive notification of new cases,  
[sign up here](#)  
[Contact Us](#)

