

## Interstitial Keratitis Secondary to Syphilis

Category(ies): Cornea

Contributors: [Lucas Lenci, MD](#); [Prashant Parekh, MD, MBA](#)

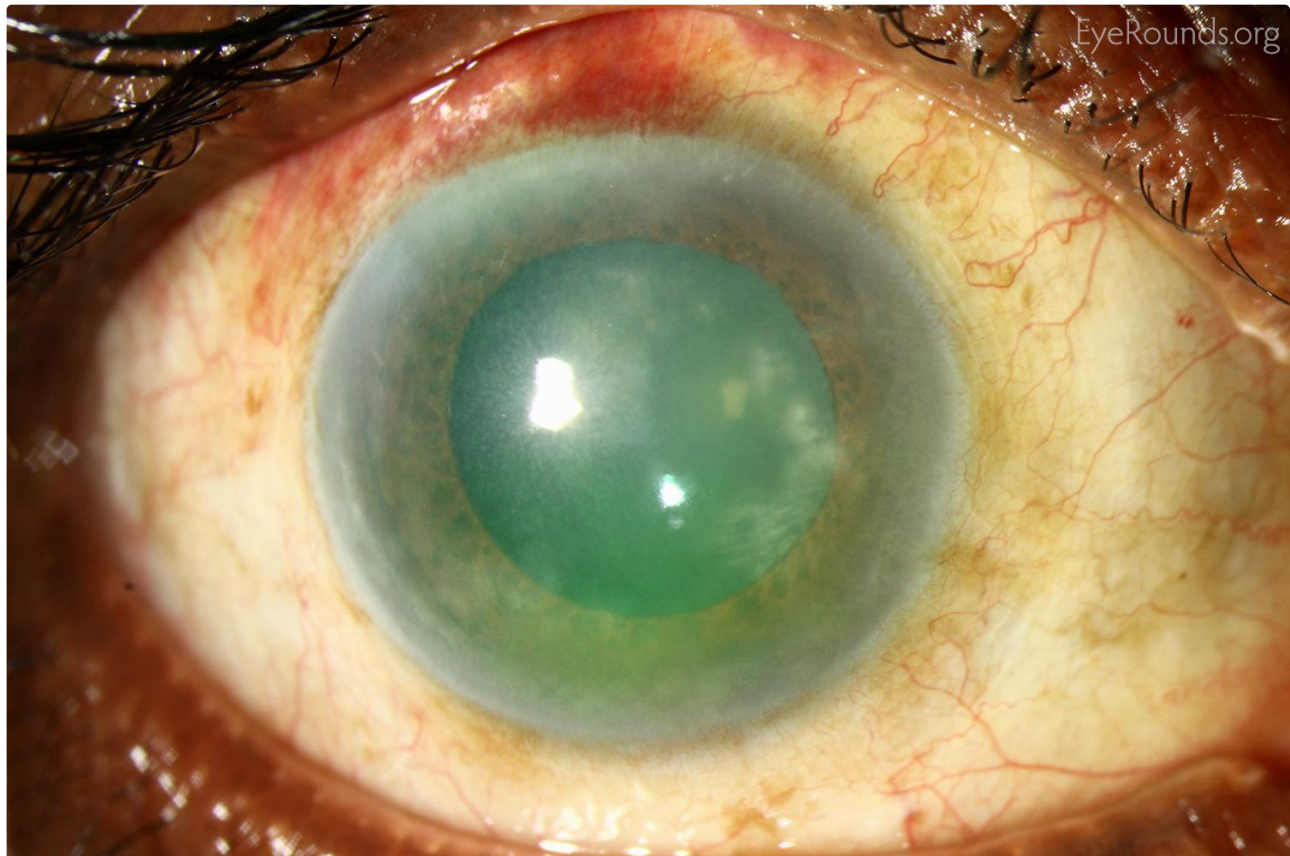Photographer: Brice Critser, CRA



This is a 73-year-old male who presented initially for trabeculectomy surgery. Upon examination, the patient was found to have a corneal stromal scar with prominent ghost vessels. The patient was sent for blood work which returned positive for syphilis serologies.

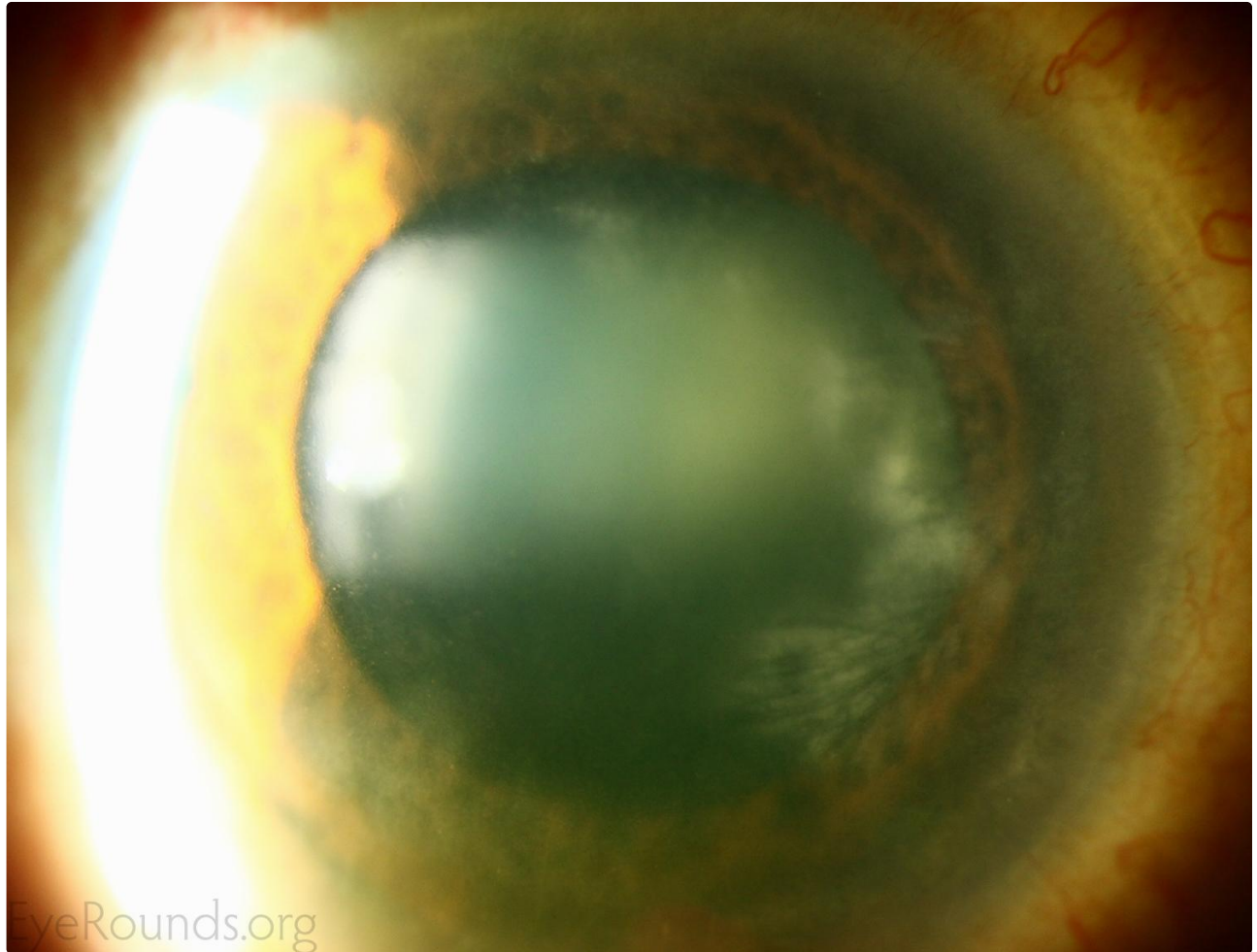
He was referred to infectious diseases and treated. He was having no acute symptoms further suggesting this was a chronic process.

These lesions, when acute, present with neovascularization of the stroma, which some refer to as a salmon patch. Patients are also generally symptomatic initially with symptoms of photophobia, redness, and pain. Over time there is regression of these vessels leaving the images as seen above as a classic example of interstitial keratitis. The differential diagnoses is quite broad, but in the US the most common etiologies are HSV and syphilis.



 Enlarge

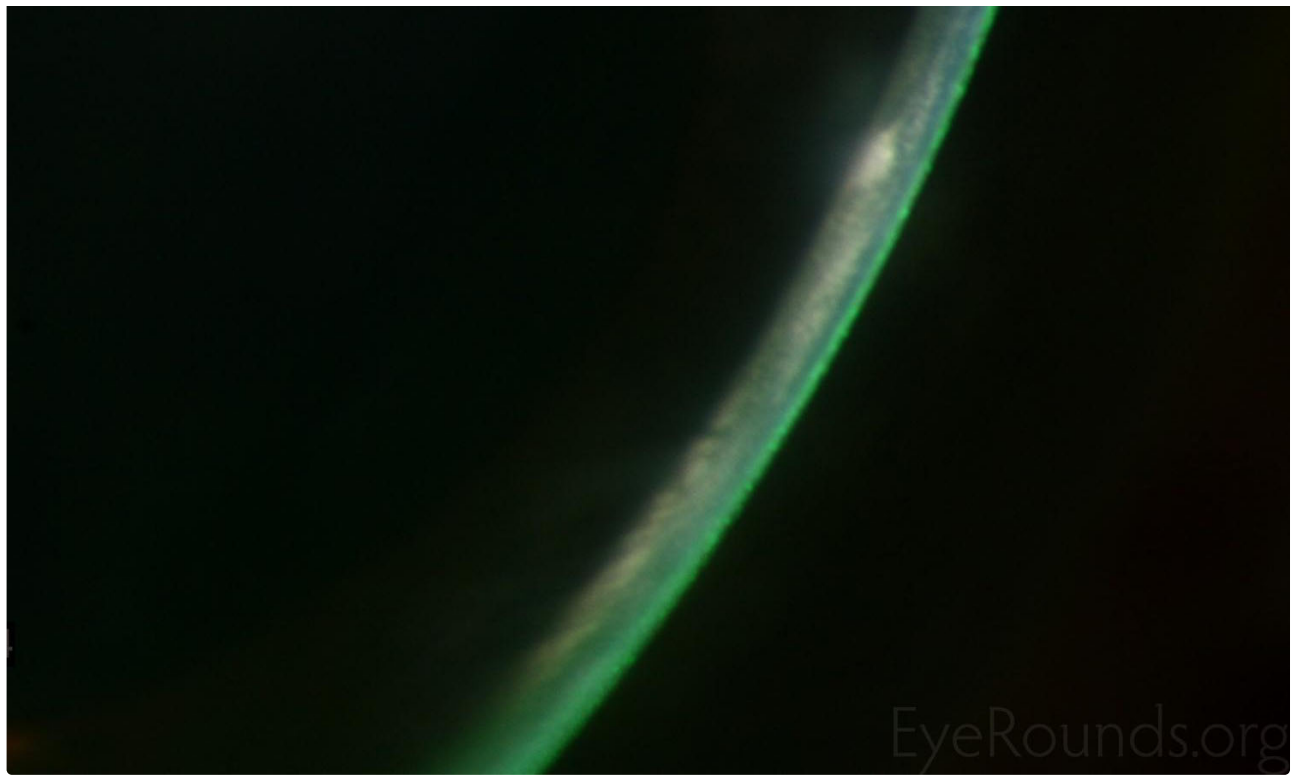
 Download



[Enlarge](#)

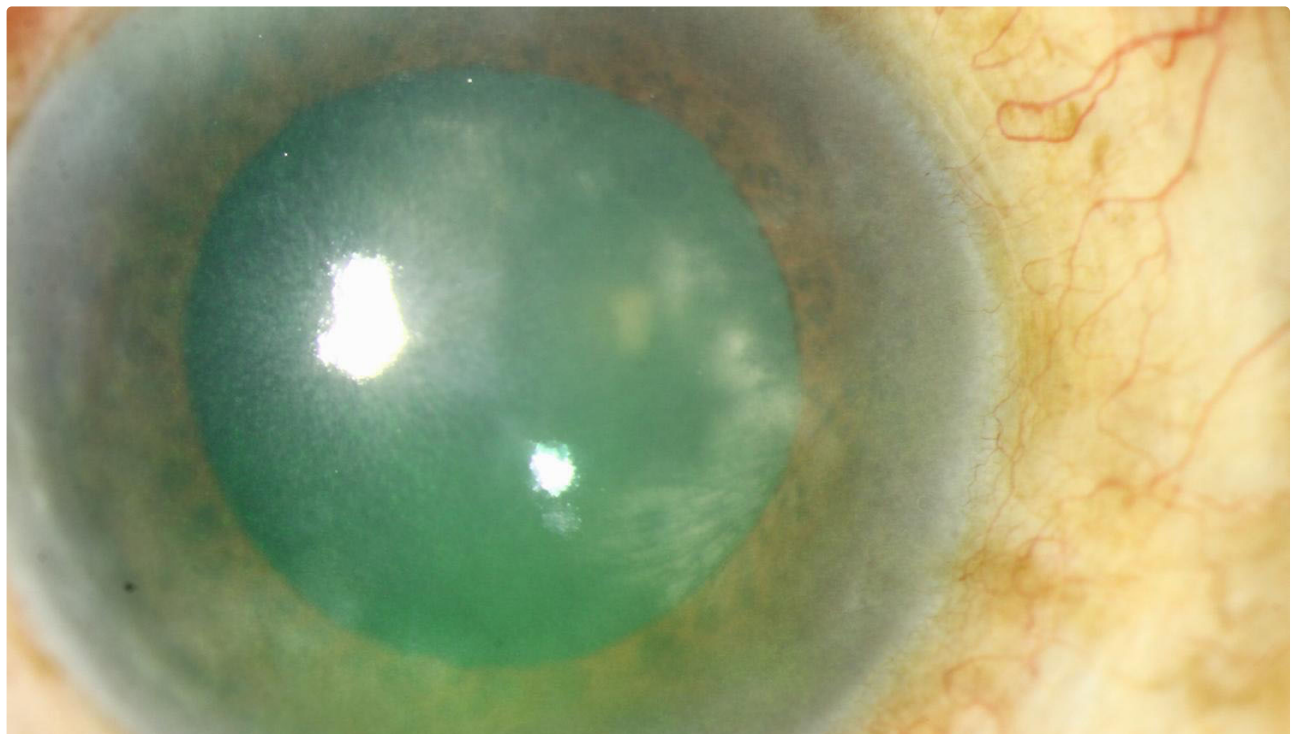
[Download](#)





[Enlarge](#)

[Download](#)



 Enlarge

 Download

### Image Permissions:



Ophthalmic Atlas Images by [EyeRounds.org](#), [The University of Iowa](#) are licensed under a [Creative Commons Attribution-NonCommercial-NoDerivs 3.0 Unported License](#).

### Address

University of Iowa  
Roy J. and Lucille A. Carver College  
of Medicine  
Department of Ophthalmology and  
Visual Sciences  
200 Hawkins Drive  
Iowa City, IA 52242

[Support Us](#)

### Legal

Copyright © 2019 The University of  
Iowa. All Rights Reserved  
[Report an issue with this page](#)  
[Web Privacy Policy](#) |  
[Nondiscrimination Statement](#)

### Related Links

[Cataract Surgery for Greenhorns](#)  
[EyeTransillumination](#)  
[Gonioscopy.org](#)  
[Iowa Glaucoma Curriculum](#)  
[Iowa Wet Lab](#)  
[Patient Information](#)  
[Stone Rounds](#)  
[The Best Hits Bookshelf](#)

### EyeRounds Social Media

Follow



[Receive notification of new cases,  
sign up here](#)  
[Contact Us](#)  
[Submit a Suggestion](#)