

Stellate, anterior subcapsular cataract with granular, brown deposits along the suture lines in a patient taking chlorpromazine.

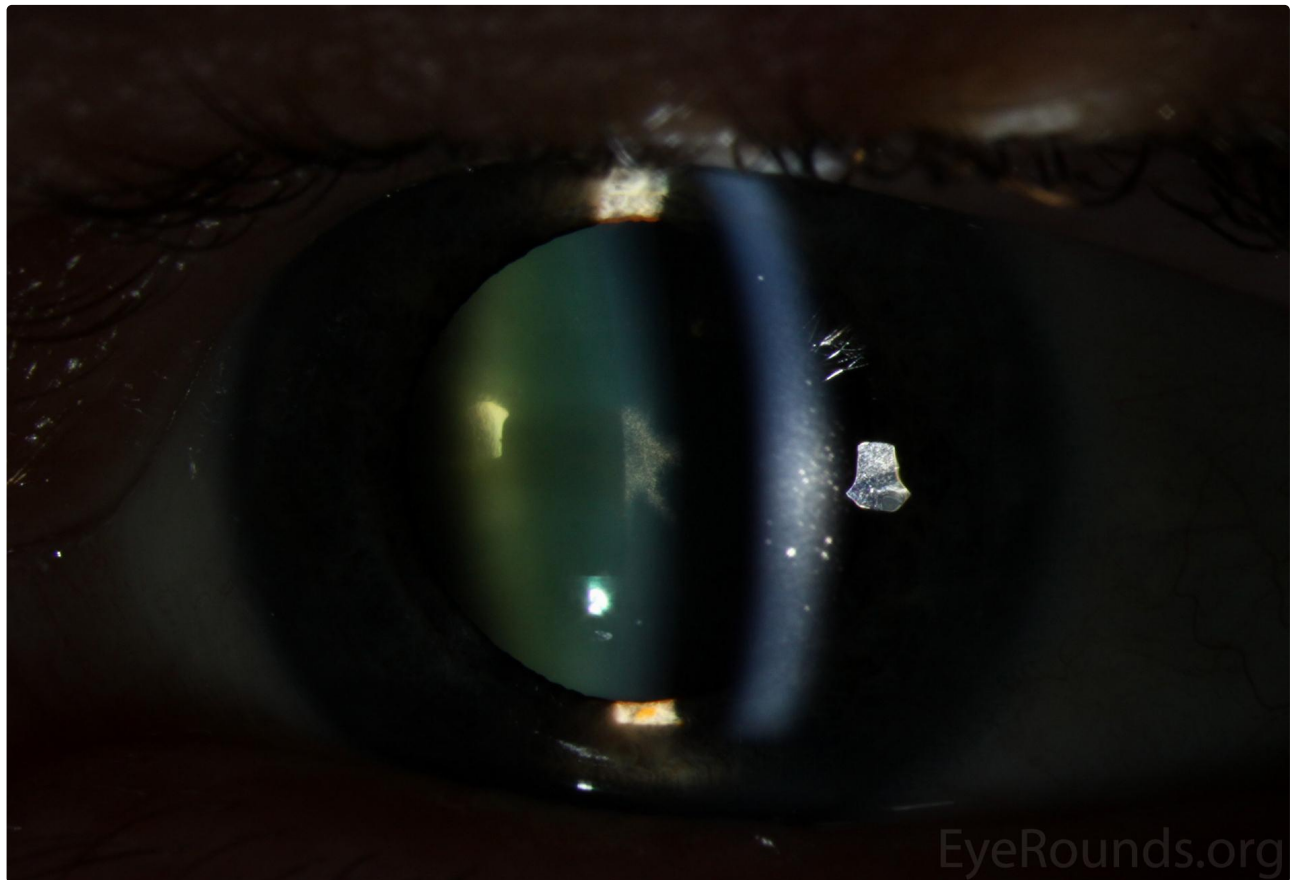
Category(ies): [Cataract, Lens](#)

Contributor: [Jaclyn Haugsdal, MD](#)

Photographer: [Brice Critser, CRA](#)



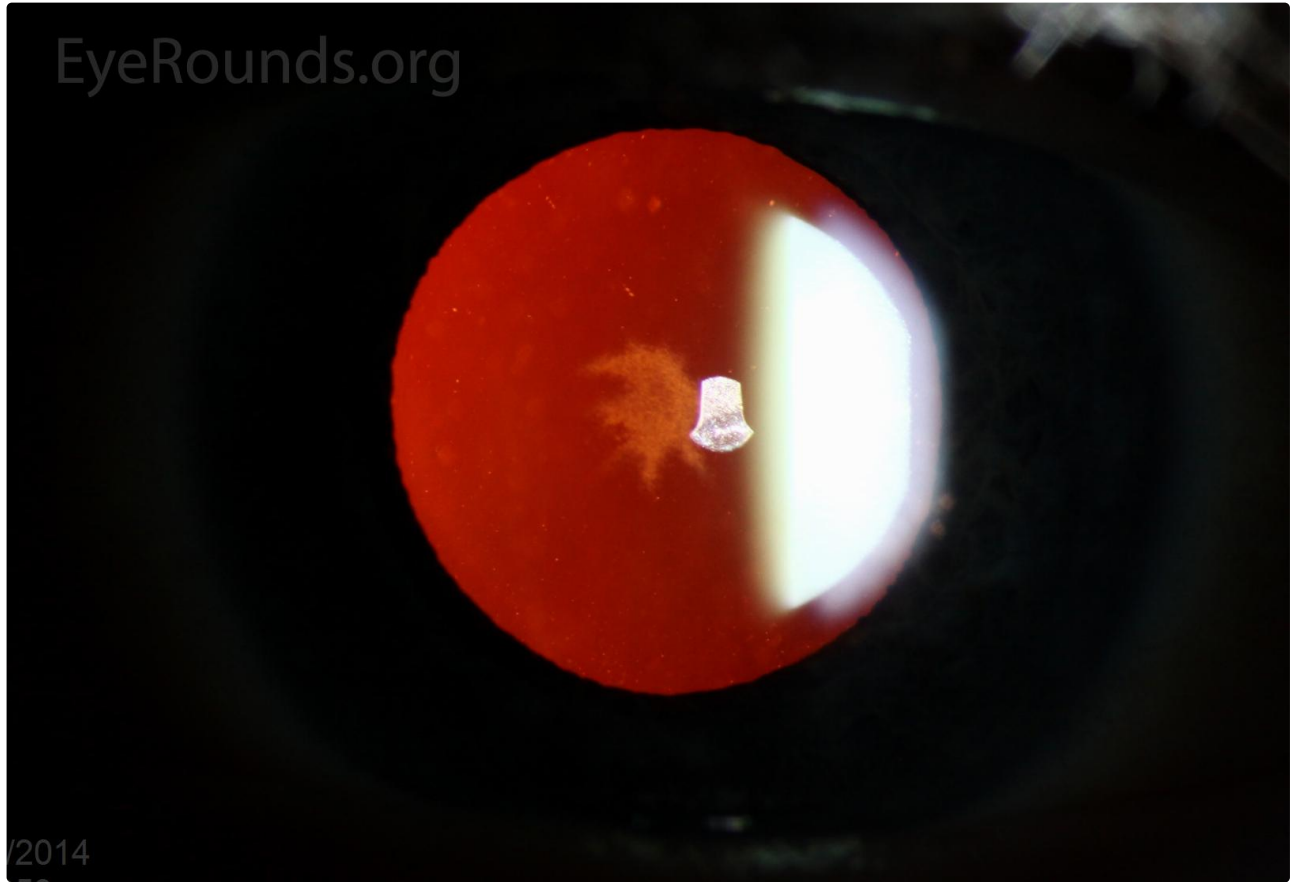
Stellate, anterior subcapsular cataract with granular, brown deposits along the suture lines in a patient taking chlorpromazine.



[Enlarge](#)

[Download](#)

EyeRounds.org



2014

 Enlarge

 Download

Image Permissions:



Ophthalmic Atlas Images by EyeRounds.org, The University of Iowa are licensed under a Creative Commons Attribution-NonCommercial-NoDerivs 3.0 Unported License.

Address

University of Iowa
Roy J. and Lucille A. Carver College
of Medicine
Department of Ophthalmology and
Visual Sciences

Legal

Copyright © 2019 The University of
Iowa. All Rights Reserved
Report an issue with this page
Web Privacy Policy |
Nondiscrimination Statement

Related Links

Cataract Surgery for Greenhorns
EyeTransillumination
Gonioscopy.org
Iowa Glaucoma Curriculum
Iowa Wet Lab

EyeRounds Social Media

Follow



200 Hawkins Drive
Iowa City, IA 52242

[Support Us](#)

[Patient Information](#)
[Stone Rounds](#)
[The Best Hits Bookshelf](#)

[Receive notification of new cases,
sign up here](#)
[Contact Us](#)
[Submit a Suggestion](#)