

Distichiasis

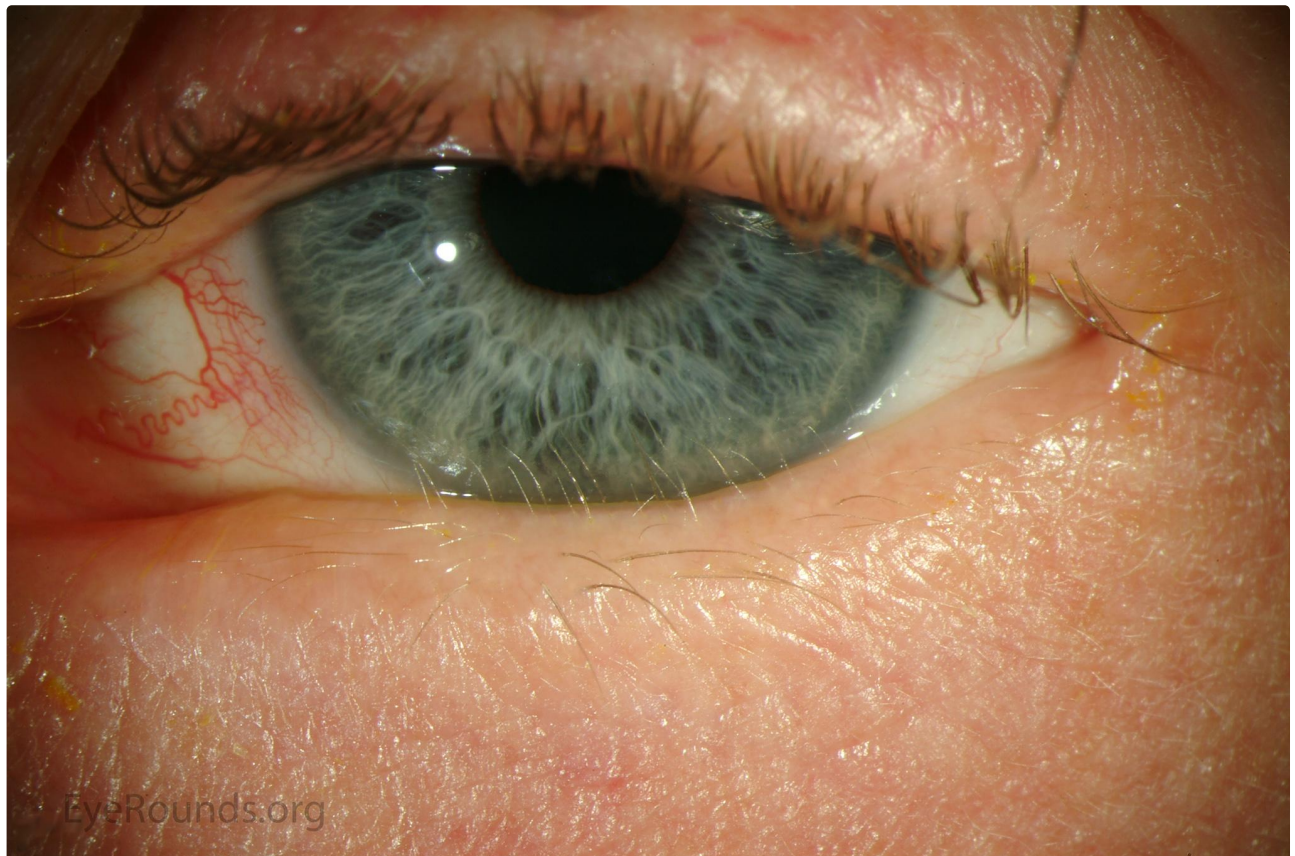Category(ies): [Occuplastics](#)

Contributor: [Jesse Vislisel, MD](#)

Photographer: [Brice Critser, CRA](#)

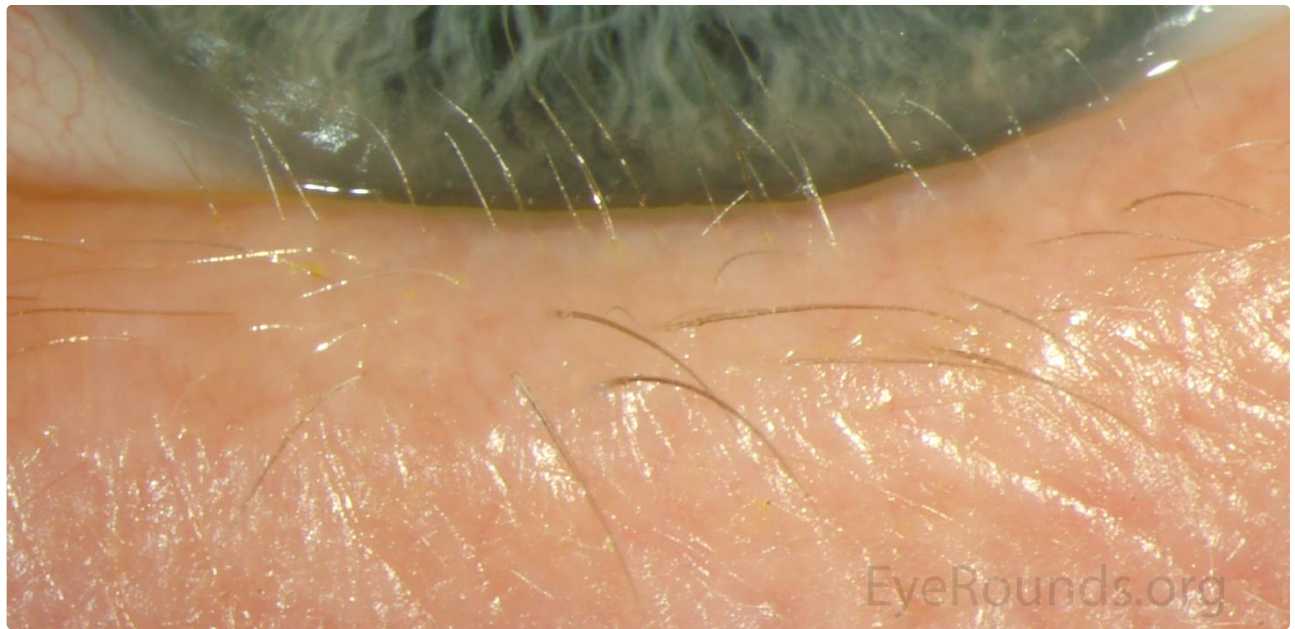

Distichiasis is the congenital or acquired presence of a partial or complete second row of eyelashes arising from the meibomian gland orifices. This is made possible because the meibomian glands and lash follicles differentiate from a common pilosebaceous unit. Acquired causes occur after trauma or chronic irritation to the eyelid margin.



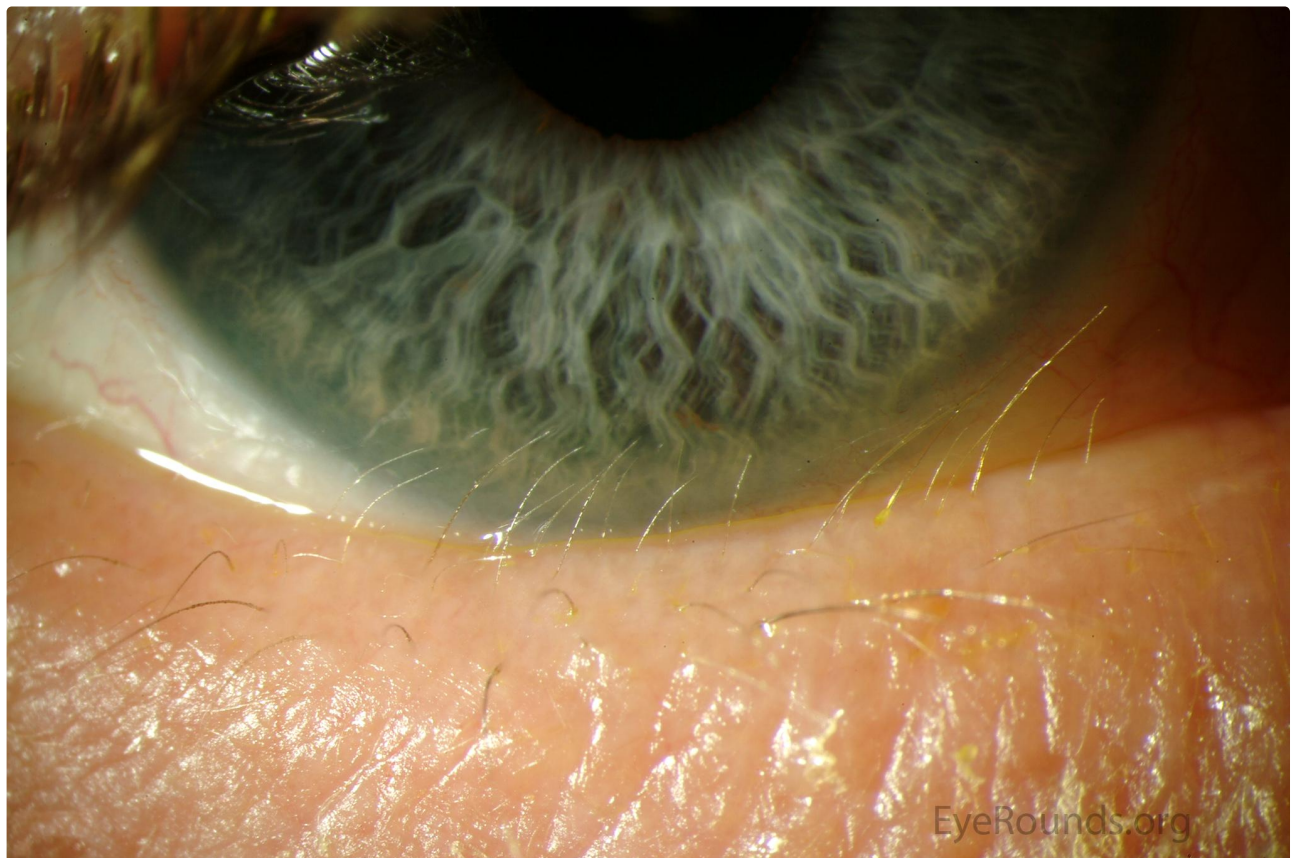
[Enlarge](#)

[Download](#)



[Enlarge](#)

[Download](#)



[Enlarge](#)

[Download](#)

Image Permissions:



Ophthalmic Atlas Images by EyeRounds.org, The University of Iowa are licensed under a [Creative Commons Attribution-NonCommercial-NoDerivs 3.0 Unported License](https://creativecommons.org/licenses/by-nc-nd/3.0/).

Address

University of Iowa
Roy J. and Lucille A. Carver College
of Medicine
Department of Ophthalmology and
Visual Sciences
200 Hawkins Drive
Iowa City, IA 52242

[Support Us](#)

Legal

Copyright © 2019 The University of
Iowa. All Rights Reserved
[Report an issue with this page](#)
[Web Privacy Policy](#) |
[Nondiscrimination Statement](#)

Related Links

[Cataract Surgery for Greenhorns](#)
[EyeTransillumination](#)
Gonioscopy.org
[Iowa Glaucoma Curriculum](#)
[Iowa Wet Lab](#)
[Patient Information](#)
[Stone Rounds](#)
[The Best Hits Bookshelf](#)

EyeRounds Social Media

Follow



Receive notification of new cases,
[sign up here](#)

[Contact Us](#)

[Submit a Suggestion](#)