

## Iris mammillations

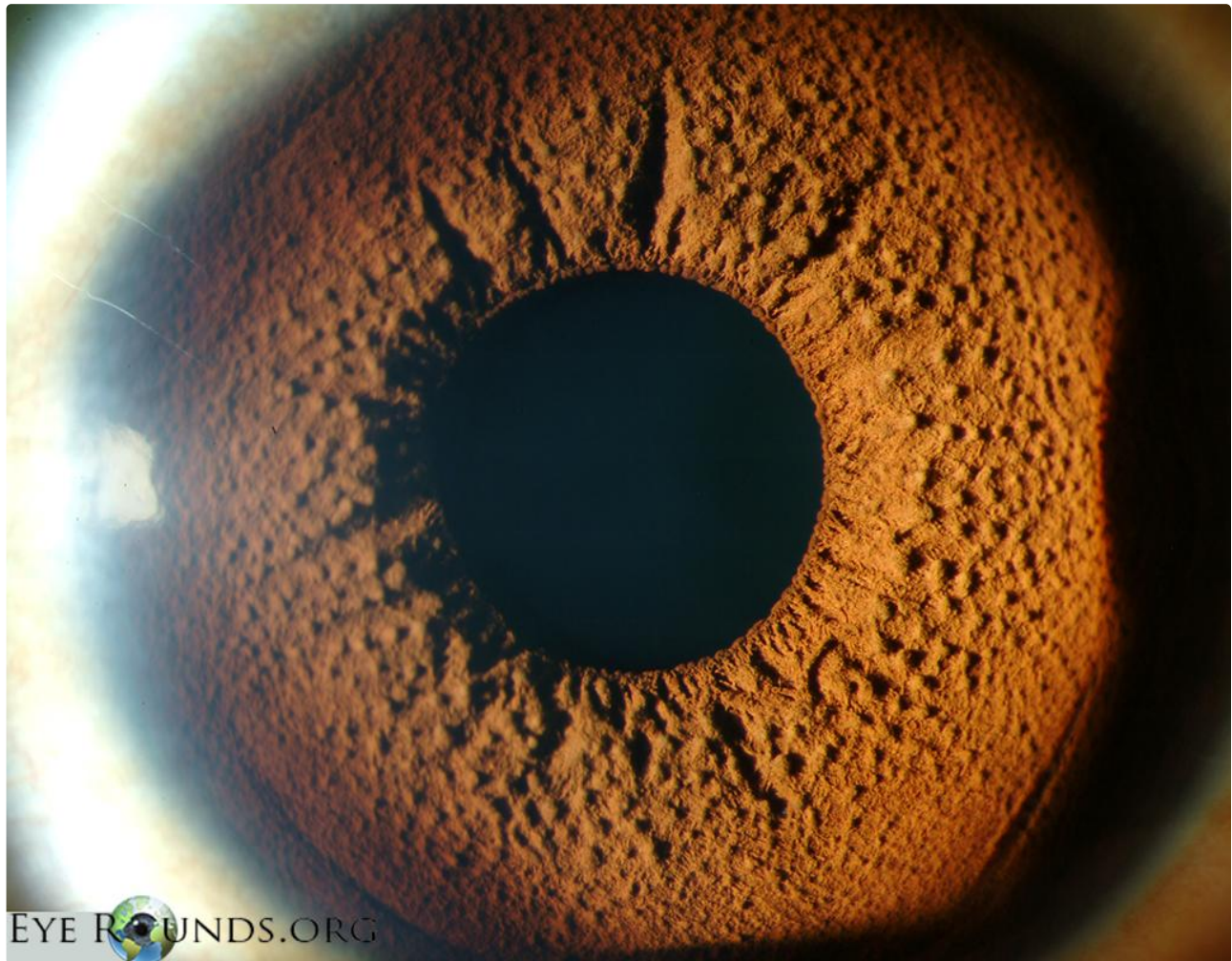
**Category(ies):** [Glaucoma](#), [Iris](#)

**Contributor:** [Jesse Vislisel, MD](#)

**Photographer:** [Toni Venckus, CRA](#)



Iris mammillations are diffuse, tiny, nodules that cover the iris surface. They are most commonly unilateral and are usually seen in darkly pigmented irides or overlying iris nevi. Mammillations can be associated with oculodermal melanocytosis or phakomatosis pigmentovascularis (PPV) type IIb and neurofibromatosis (NF) type I. They are usually sporadic, but can have autosomal dominant inheritance.



EyeRounds.org

[Enlarge](#)

[Download](#)

### References:

1. Ragge NK, Acheson J, Murphree AL. Iris mammillations: significance and associations. *Eye (Lond)*. 1996;10 ( Pt 1):86-91.

---

## Image Permissions:



Ophthalmic Atlas Images by [EyeRounds.org](http://EyeRounds.org), [The University of Iowa](http://The University of Iowa) are licensed under a [Creative Commons Attribution-NonCommercial-NoDerivs 3.0 Unported License](https://creativecommons.org/licenses/by-nc-nd/3.0/).

---

### Address

University of Iowa  
Roy J. and Lucille A. Carver College  
of Medicine  
Department of Ophthalmology and  
Visual Sciences  
200 Hawkins Drive  
Iowa City, IA 52242

[Support Us](#)

### Legal

Copyright © 2019 The University of  
Iowa. All Rights Reserved  
[Report an issue with this page](#)  
[Web Privacy Policy](#) |  
[Nondiscrimination Statement](#)

### Related Links

[Cataract Surgery for Greenhorns](#)  
[EyeTransillumination](#)  
[Gonioscopy.org](http://Gonioscopy.org)  
[Iowa Glaucoma Curriculum](#)  
[Iowa Wet Lab](#)  
[Patient Information](#)  
[Stone Rounds](#)  
[The Best Hits Bookshelf](#)

### EyeRounds Social Media

Follow



[Receive notification of new cases,  
sign up here](#)  
[Contact Us](#)  
[Submit a Suggestion](#)