

EyeRounds.org

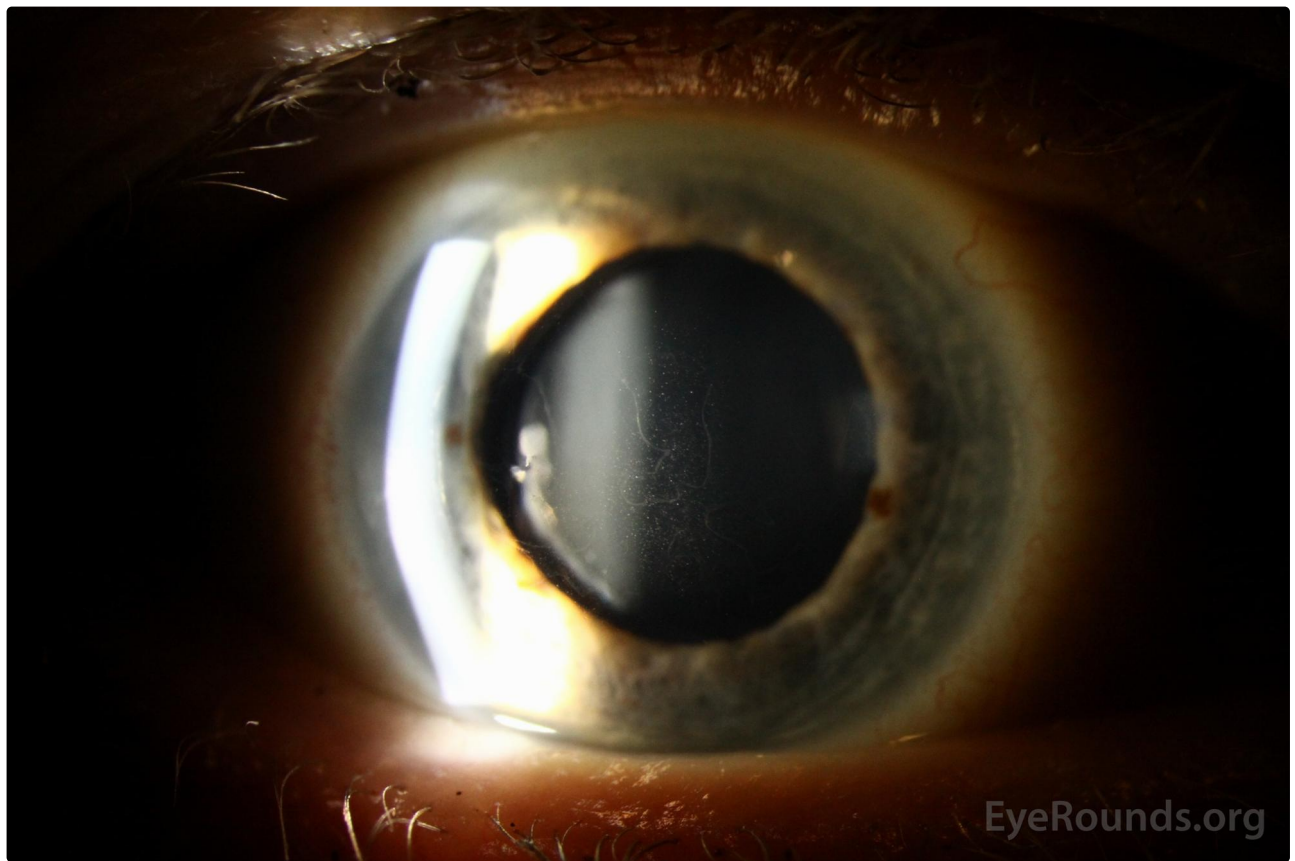
Epithelial basement membrane dystrophy (map-dot-fingerprint dystrophy)

Category(ies): Cornea


Contributor: Lorraine M. Provencher, MD

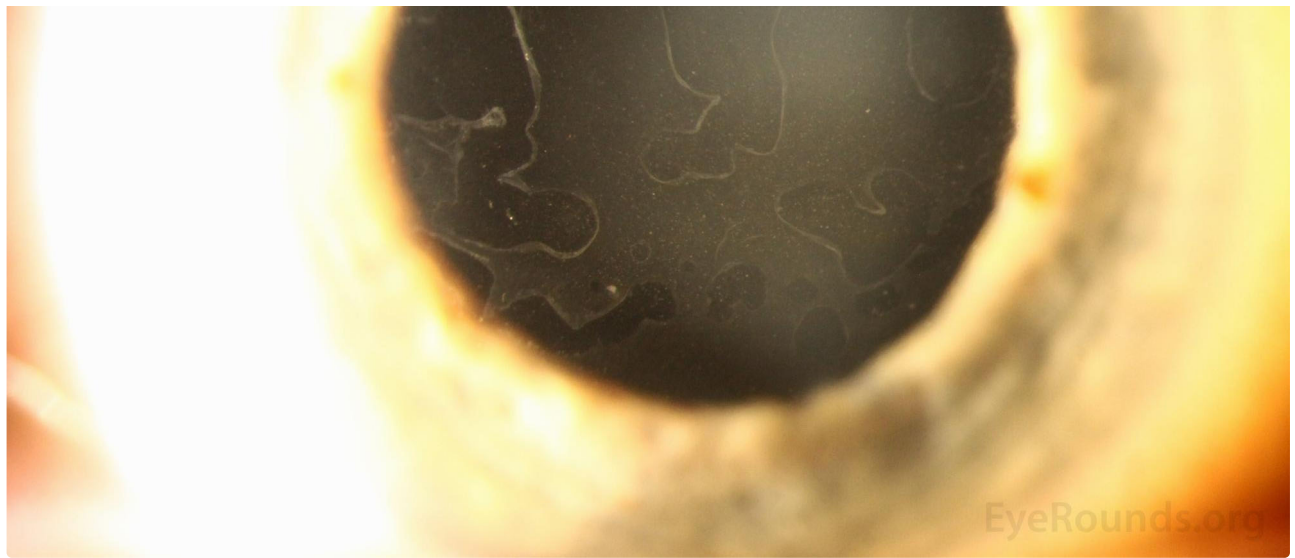Photographer: Brice Critser, CRA

This patient had both [Meesmann epithelial corneal dystrophy](#) and striking epithelial basement membrane dystrophy (EBMD), neither of which were symptomatic.



[Enlarge](#) [Download](#)




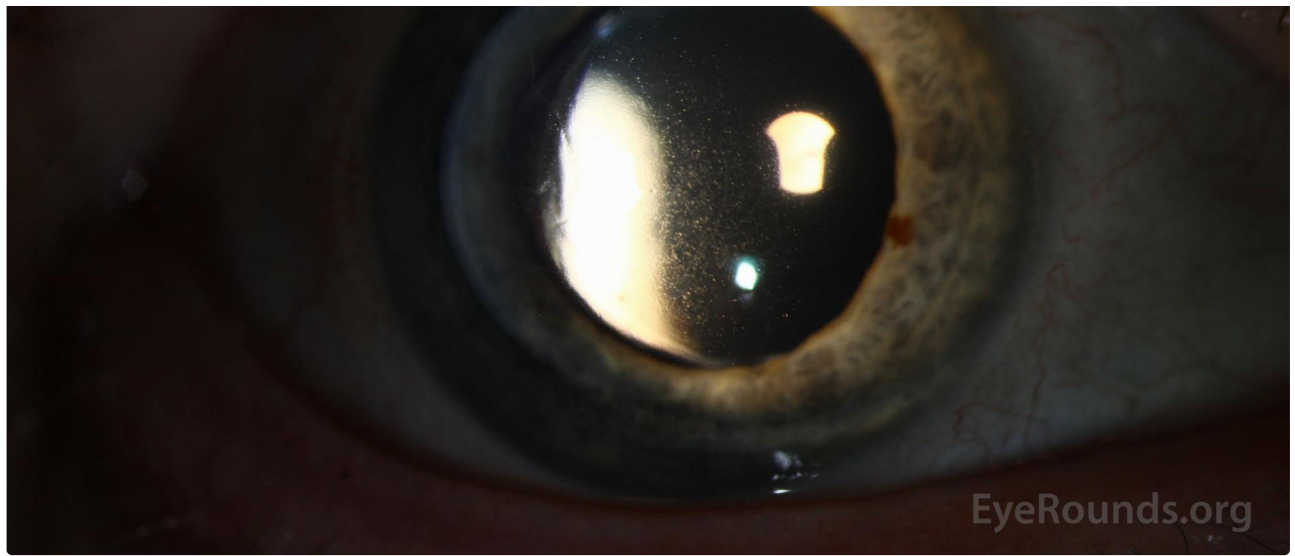


[Enlarge](#) [Download](#)



[Enlarge](#) [Download](#)

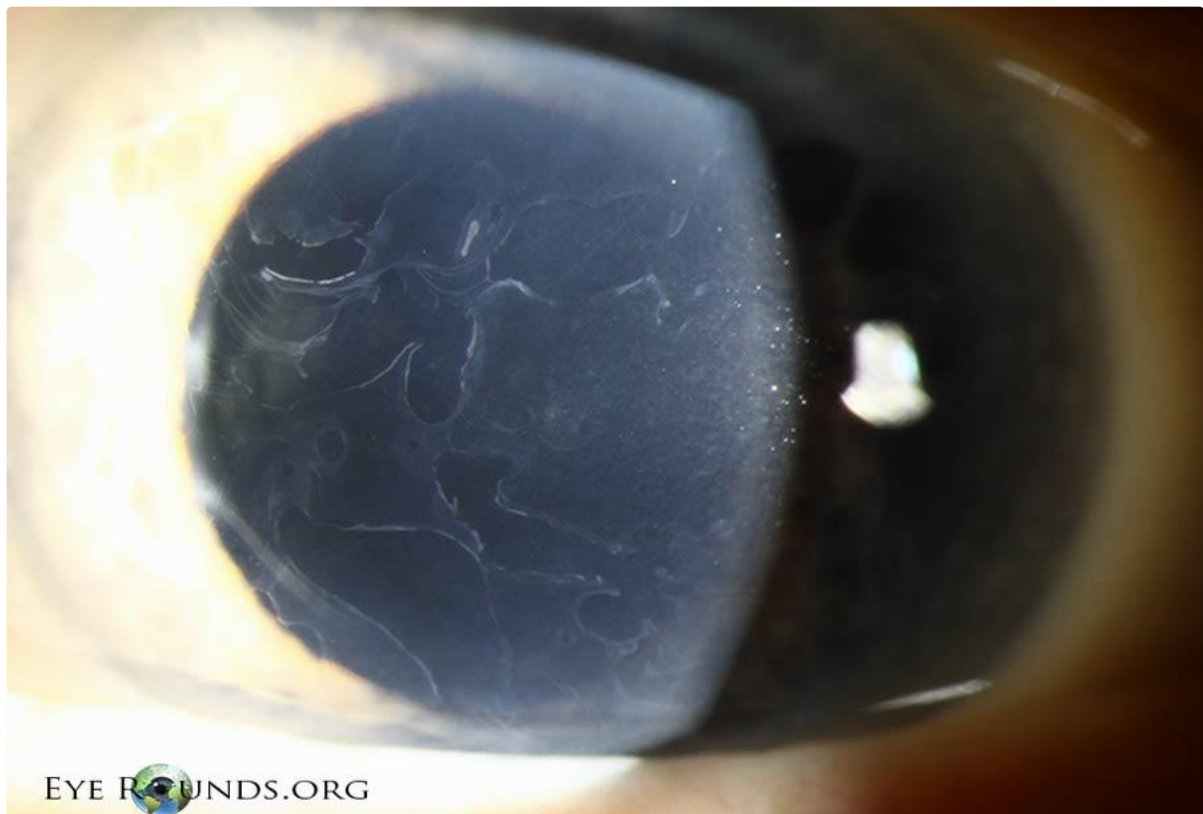



[Enlarge](#) [Download](#)

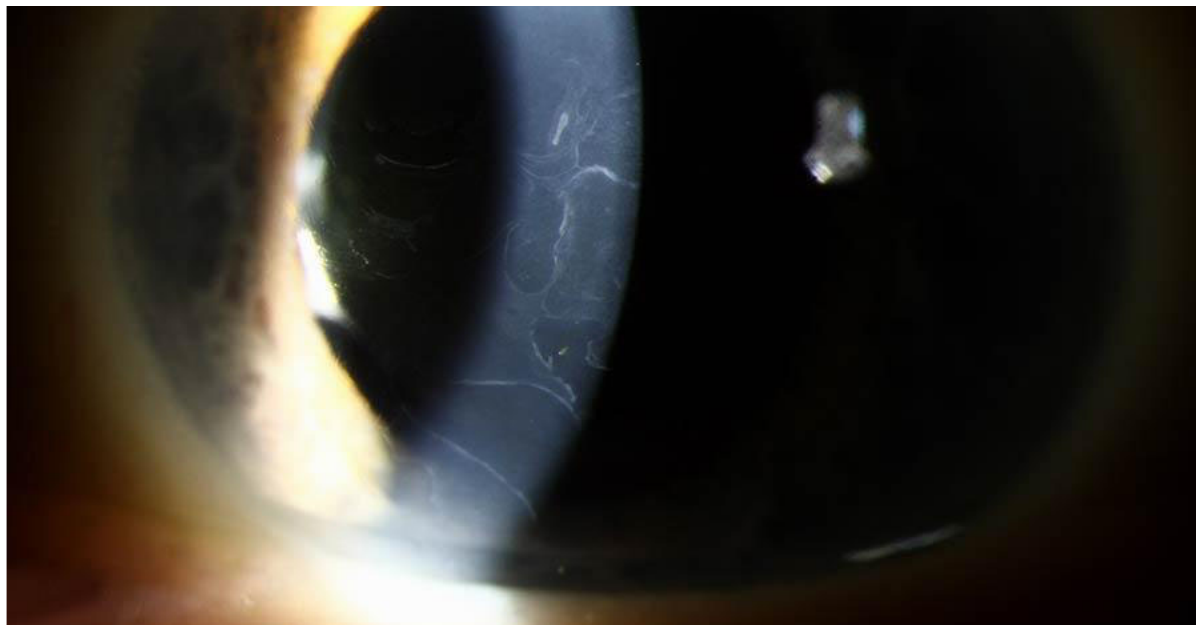
Contributor: [Meredith Baker, MD](#)

72-year-old female with decrease in central visual acuity. Classic gray patches, fingerprint lines, map lines, dots, and cobblestone pattern in the corneal epithelium are seen on this photo.



[Enlarge](#) [Download](#)



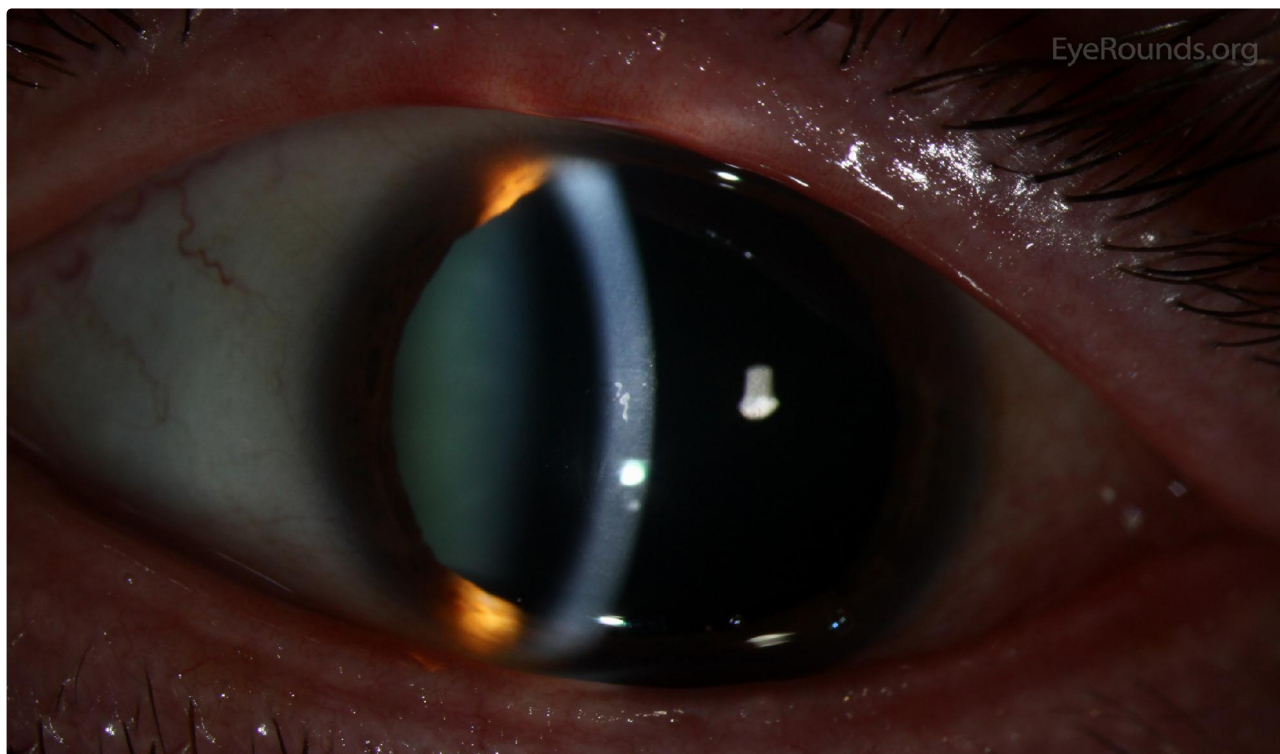


[Enlarge](#) [Download](#)

Contributor: [Thomas J.E. Clark, MD](#)

Photographer: Carol Chan, CRA

This photo demonstrates classic "dots", which manifest as irregular round, oval, or comma-shaped, non-staining, putty-gray intraepithelial opacities. They represent intraepithelial pseudocysts containing cytoplasmic debris.



[Enlarge](#) [Download](#)

Reference:

Weiss JS, Moller HU, Aldave AJ, et al. IC3D Classification of Corneal Dystrophies—Edition 2. *Cornea*. 2015;34:117-159.

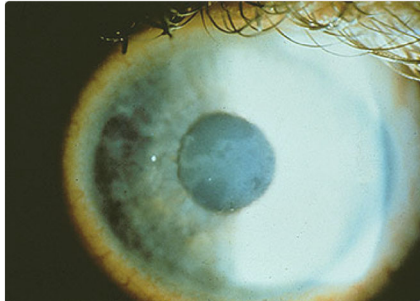
Image Permissions:



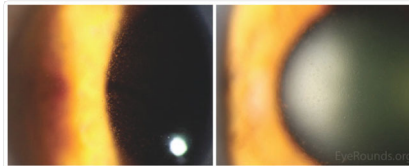
Ophthalmic Atlas Images by EyeRounds.org, The University of Iowa are licensed under a [Creative Commons Attribution-NonCommercial-NoDerivs 3.0 Unported License](https://creativecommons.org/licenses/by-nc-nd/3.0/).



Related Articles



[Related Case: EBMD Treatment](#)



[Related Atlas: Meesmann Epithelial Corneal Dystrophy](#)

Address

University of Iowa
Roy J. and Lucille A. Carver College
of Medicine
Department of Ophthalmology and
Visual Sciences
200 Hawkins Drive
Iowa City, IA 52242

[Support Us](#)

Legal

Copyright © 2019 The University of
Iowa. All Rights Reserved
[Report an issue with this page](#)
[Web Privacy Policy I](#)
[Nondiscrimination Statement](#)

Related Links

[Cataract Surgery for Greenhorns](#)
[EyeTransillumination](#)
[Gonioscopy.org](#)
[Iowa Glaucoma Curriculum](#)
[Iowa Wet Lab](#)
[Patient Information](#)
[Stone Rounds](#)
[The Best Hits Bookshelf](#)

EyeRounds Social Media

Follow



Receive notification of new cases,
[sign up here](#)
[Contact Us](#)
[Submit a Suggestion](#)