

Fuch's Endothelial Corneal Dystrophy

Category(ies): Cornea

Contributor: Brendan K. Penaluna, [Jordan Graff, MD](#), [Andrew Doan, MD, PhD](#)



Expanded text by Brendan K. Penaluna, May 5, 2017

Fuchs' dystrophy is an example of a posterior corneal dystrophy. Thickening of the Descemet's membrane and defects of endothelial cell number and shape may result in progressive obscuration of vision. Cataract surgery in the setting of Fuch's dystrophy may rarely result in the decompensation of the corneal endothelium, creating an opportunity for the worsening of Fuchs' dystrophy. In this image of a patient with Fuchs' dystrophy post-cataract surgery, endothelial degeneration and subsequent edema and scarring can be appreciated as the white, hazy opacity contrasting against the brown iris and black of the pupil.[1]

Contributor: Jordan M. Graff, MD



Slit beam view of cornea in a patient with Fuch's corneal dystrophy. By overlying the slit beam with the reflected image of the tungsten filament on the cornea, the examiner can highlight the endothelial surface just to the side of the combined bright spot in the slit beam.

[Enlarge](#) [Download](#)

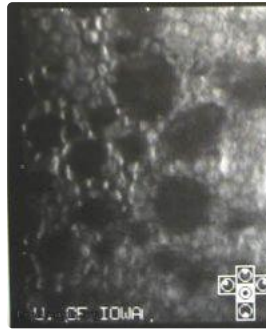




Here, the characteristic corneal endothelial guttata are well visualized.

[Enlarge](#) [Download](#)

Contributor: Andrew Doan, MD, PhD



specular microscopy with loss of endothelial cells

[Enlarge](#) [Download](#)

References:

1. Biswell R. Chapter 6. Cornea. In: Riordan-Eva P, Cunningham ET, Jr. eds. Vaughan & Asbury's General Ophthalmology, 18e New York, NY: McGraw-Hill; 2011. <http://accessmedicine.mhmedical.com/content.aspx?bookid=387&ionid=40229323>. Accessed April 17, 2017.

Image Permissions:



Ophthalmic Atlas Images by [EyeRounds.org](http://www.eyerounds.org), [The University of Iowa](http://www.theuniversityofiowa.edu) are licensed under a [Creative Commons Attribution-NonCommercial-NoDerivs 3.0 Unported License](https://creativecommons.org/licenses/by-nc-nd/3.0/).

Address

University of Iowa
Roy J. and Lucille A. Carver College

Legal

Related Links

Cataract Surgery for Greenhorns
EyeTransillumination

EyeRounds Social Media

of Medicine
Department of Ophthalmology and
Visual Sciences
200 Hawkins Drive
Iowa City, IA 52242

[Support Us](#)

Copyright © 2019 The University of
Iowa. All Rights Reserved
[Report an issue with this page](#)
[Web Privacy Policy](#) |
[Nondiscrimination Statement](#)

[Gonioscopy.org](#)
[Iowa Glaucoma Curriculum](#)
[Iowa Wet Lab](#)
[Patient Information](#)
[Stone Rounds](#)
[The Best Hits Bookshelf](#)

Follow



Receive notification of new cases,
[sign up here](#)
[Contact Us](#)
[Submit a Suggestion](#)