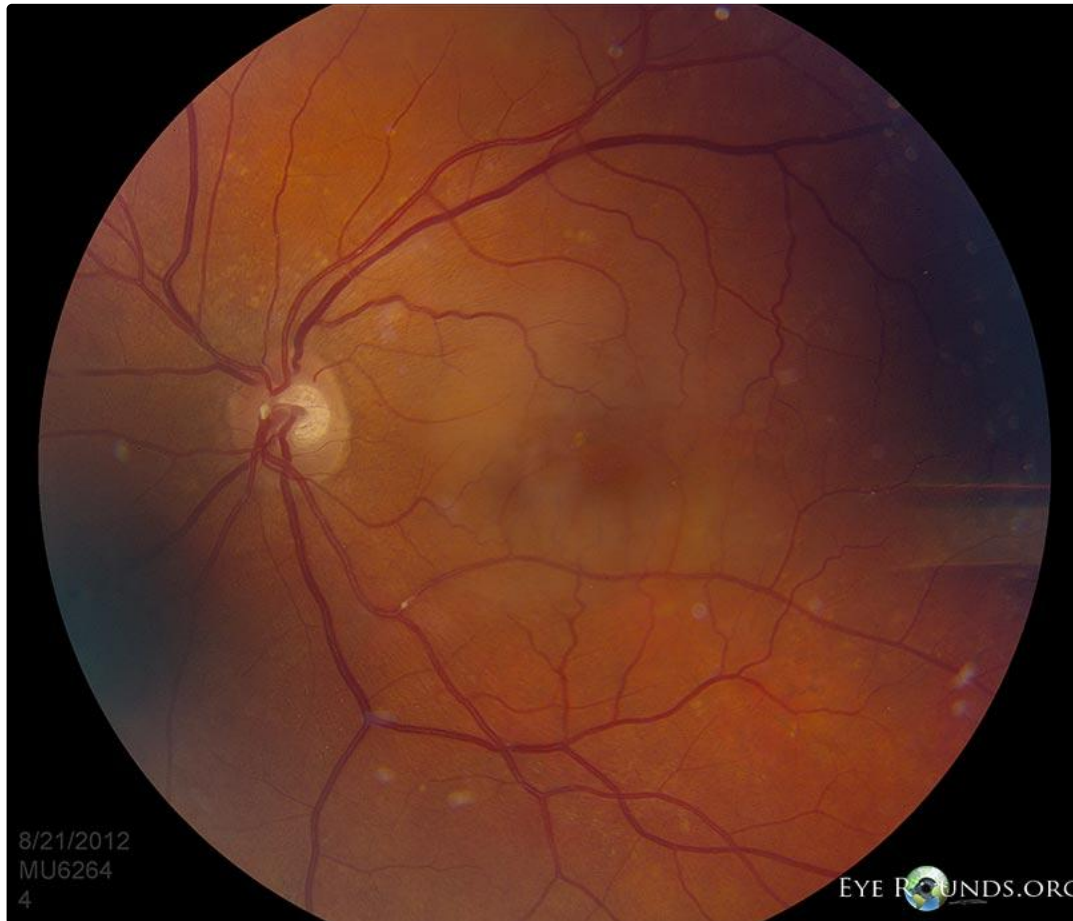

## Hollenhorst plaque in Branch Retinal Artery Occlusion (BRAO)

Category(ies): Retina, Vitreous

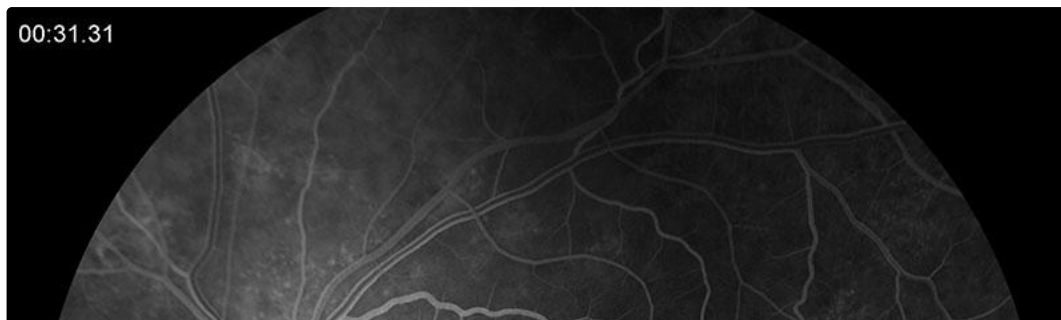
Contributor: [Elizabeth Gauger, MD](#)

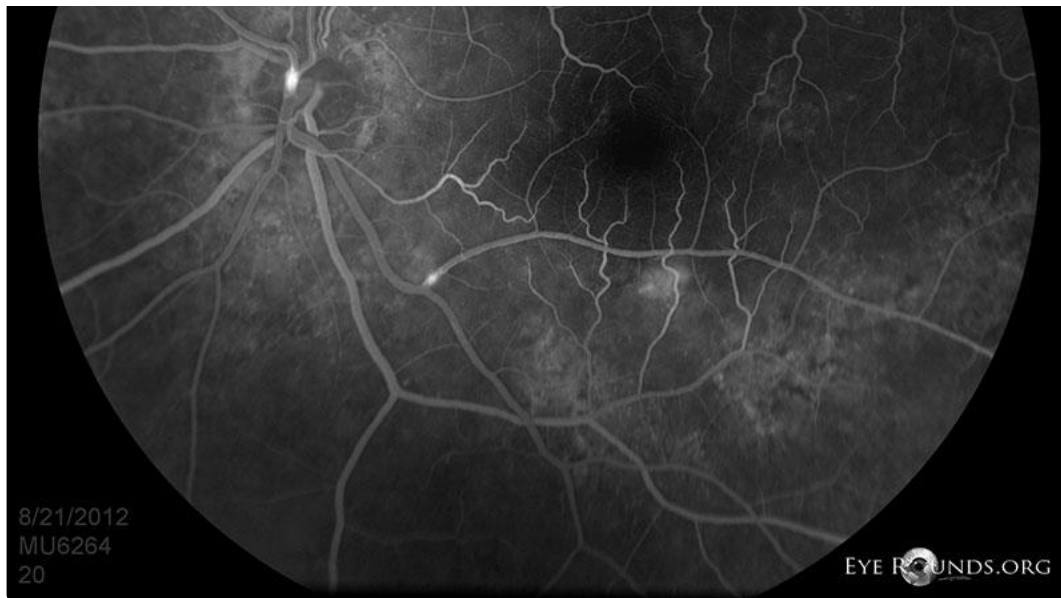Photographer: Toni Venckus, CRA



BRAO left eye. Two Hollenhorst plaques can be visualized: one in the first bifurcation of the central retinal artery and another along the inferotemporal arcade arteriole at a branch point.

[Enlarge](#) [Download](#)





Note the macular whitening indicating macular ischemia.

[Enlarge](#)

[Download](#)

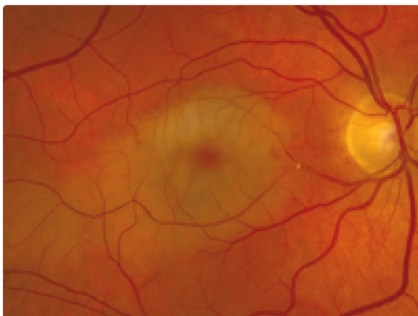
### Image Permissions:



Ophthalmic Atlas Images by [EyeRounds.org](#), [The University of Iowa](#) are licensed under a [Creative Commons Attribution-NonCommercial-NoDerivs 3.0 Unported License](#).



### Related Articles



[Related Atlas Entry: Hollenhorst plaque with branch retinal artery occlusion \(BRAO\) causing a cherry red spot](#)

## Address

University of Iowa  
Roy J. and Lucille A. Carver College  
of Medicine  
Department of Ophthalmology and  
Visual Sciences  
200 Hawkins Drive  
Iowa City, IA 52242

[Support Us](#)

## Legal

Copyright © 2019 The University of  
Iowa. All Rights Reserved  
[Report an issue with this page](#)  
[Web Privacy Policy](#) |  
[Nondiscrimination Statement](#)

## Related Links

[Cataract Surgery for Greenhorns](#)  
[EyeTransillumination](#)  
[Gonioscopy.org](#)  
[Iowa Glaucoma Curriculum](#)  
[Iowa Wet Lab](#)  
[Patient Information](#)  
[Stone Rounds](#)  
[The Best Hits Bookshelf](#)

## EyeRounds Social Media

Follow



Receive notification of new cases,  
[sign up here](#)  
[Contact Us](#)  
[Submit a Suggestion](#)