

Laser Pointer Maculopathy

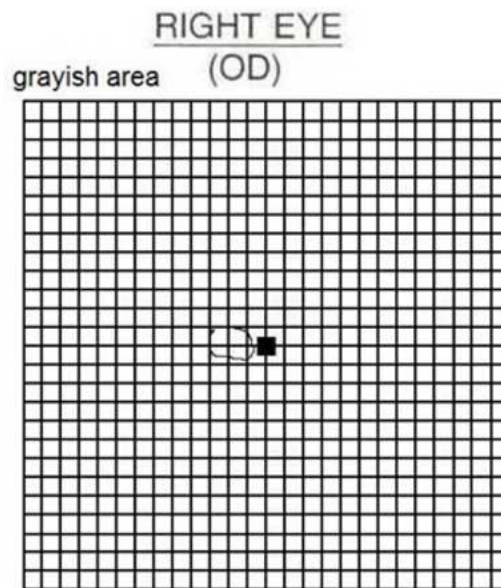
Category(ies): Retina, Vitreous

Contributor: Kristina Damisch, M2 and [Alison Bozung, OD](#)



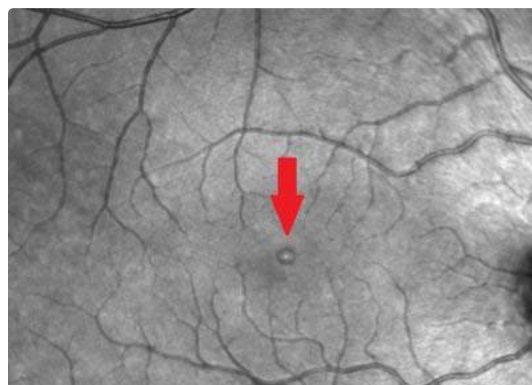This is a 16-year-old male who suffered a laser pointer injury to his right eye and subsequently found that he had a small central area of "blackness" that made it difficult to read. On fundus exam, the right eye showed a small, depigmented, circular defect just temporal to the center of the fovea. OCT showed a small cavitation at this location with IS/OS disruption. The Amsler grid was normal for the left eye but demonstrated a small central scotoma in the right eye. The exam was otherwise normal including 20/20 vision OU.

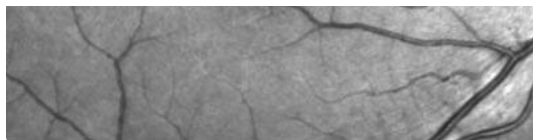
On one month follow-up, Amsler grid testing demonstrated a reduced scotoma size, and the patient reported that he notices the deficit less. The visible lesion near the fovea had healed somewhat and appeared smaller on OCT and fundus exam.



2 days after injury

[Enlarge](#) [Download](#)

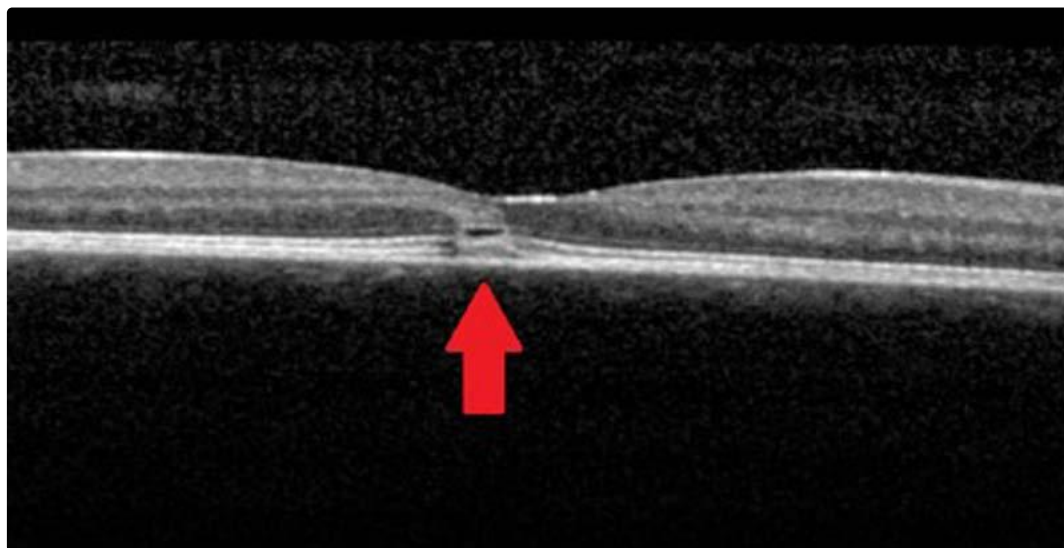




2 days after injury

[Enlarge](#)

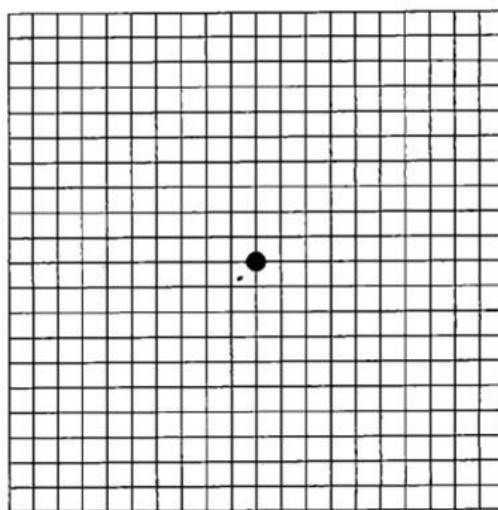
[Download](#)



2 days after injury

[Enlarge](#)

[Download](#)

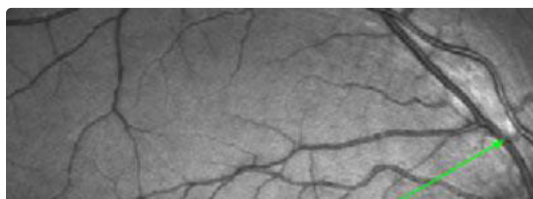


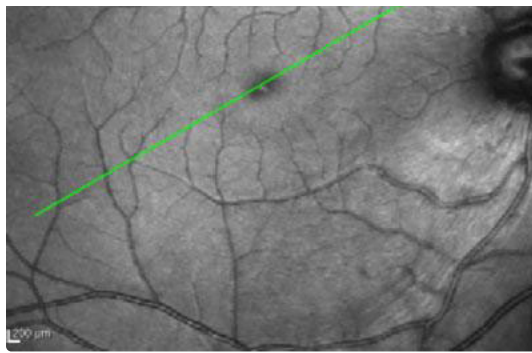
OD - tiny spot

One month after injury

[Enlarge](#)

[Download](#)

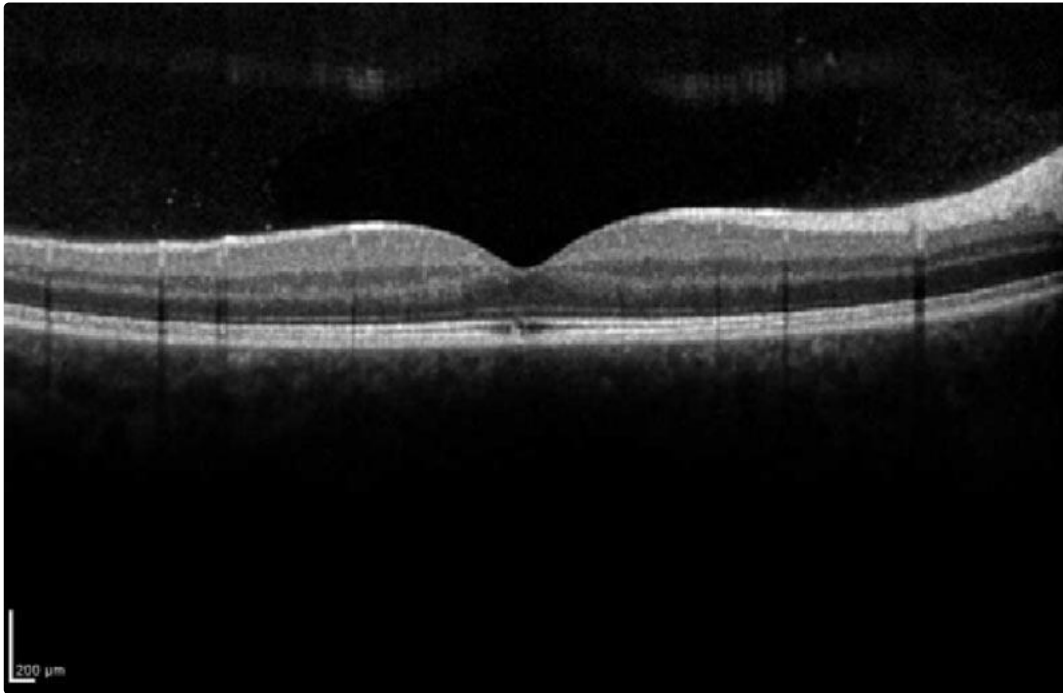




One month after injury

[Enlarge](#)

[Download](#)



One month after injury

[Enlarge](#)

[Download](#)

Image Permissions:



Ophthalmic Atlas Images by EyeRounds.org, The University of Iowa are licensed under a [Creative Commons Attribution-NonCommercial-NoDerivs 3.0 Unported License](http://creativecommons.org/licenses/by-nc-nd/3.0/).

Address

University of Iowa
Boyd and Lucille A. Carter College

Legal

Related Links

Cataract Surgery for Greenhorns

EyeRounds Social Media

Roy J. and Lucile A. Carver College
of Medicine
Department of Ophthalmology and
Visual Sciences
200 Hawkins Drive
Iowa City, IA 52242

[Support Us](#)

Copyright © 2019 The University of
Iowa. All Rights Reserved
[Report an issue with this page](#)
[Web Privacy Policy](#) |
[Nondiscrimination Statement](#)

[EyeTransillumination](#)
[Gonioscopy.org](#)
[Iowa Glaucoma Curriculum](#)
[Iowa Wet Lab](#)
[Patient Information](#)
[Stone Rounds](#)
[The Best Hits Bookshelf](#)

Follow



Receive notification of new cases,
[sign up here](#)
[Contact Us](#)
[Submit a Suggestion](#)