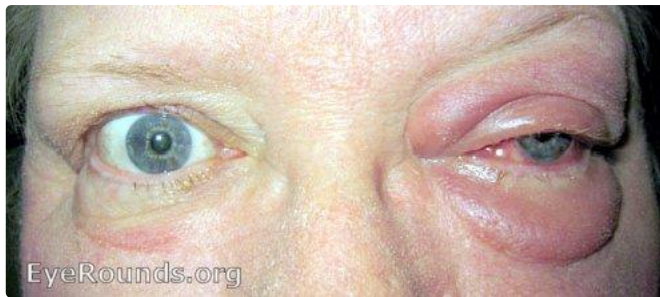

Orbital myositis (inflammatory pseudotumor)

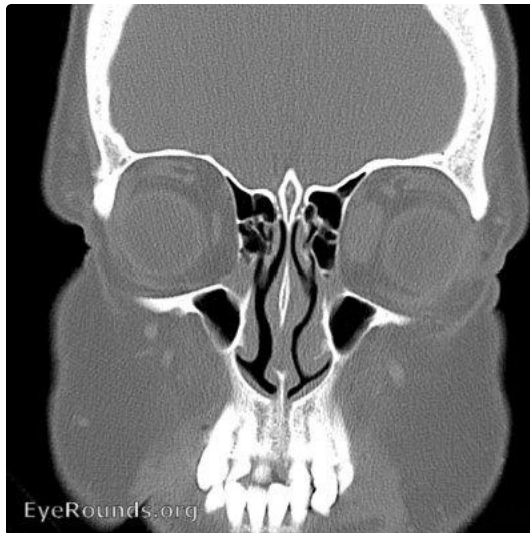
Category(ies): Oculoplastics

Contributor: [Andrew Doan, MD, PhD](#)



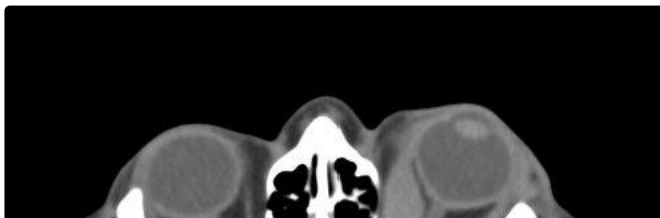Patient with vision loss over 2 weeks, restriction of gaze, and pain in the left eye.

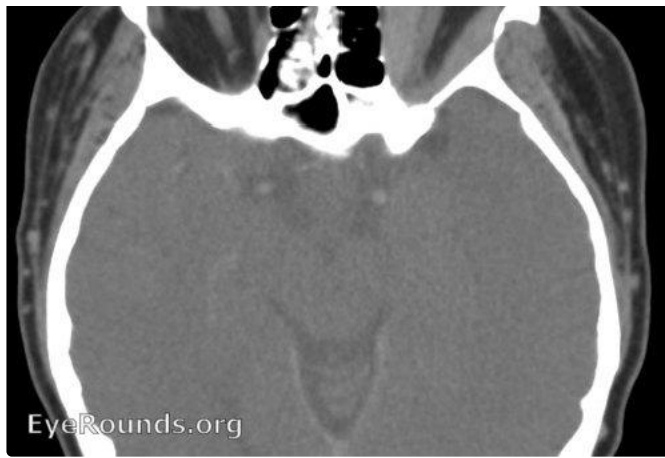[Enlarge](#) [Download](#)



Coronal CT scan with enlarged left medial rectus muscle

[Enlarge](#) [Download](#)





Axial CT scan showing enlarged muscle and optic neuropathy (globe OS is pushed forward with strain on optic nerve).

[Enlarge](#) [Download](#)

Image Permissions:



Ophthalmic Atlas Images by EyeRounds.org, The University of Iowa are licensed under a [Creative Commons Attribution-NonCommercial-NoDerivs 3.0 Unported License](https://creativecommons.org/licenses/by-nc-nd/3.0/).

Address

University of Iowa
Roy J. and Lucille A. Carver College
of Medicine
Department of Ophthalmology and
Visual Sciences
200 Hawkins Drive
Iowa City, IA 52242

[Support Us](#)

Legal

Copyright © 2019 The University of
Iowa. All Rights Reserved
[Report an issue with this page](#)
[Web Privacy Policy](#) |
[Nondiscrimination Statement](#)

Related Links

[Cataract Surgery for Greenhorns](#)
[EyeTransillumination](#)
[Gonioscopy.org](#)
[Iowa Glaucoma Curriculum](#)
[Iowa Wet Lab](#)
[Patient Information](#)
[Stone Rounds](#)
[The Best Hits Bookshelf](#)

EyeRounds Social Media

Follow



Receive notification of new cases,
[sign up here](#)
[Contact Us](#)
[Submit a Suggestion](#)