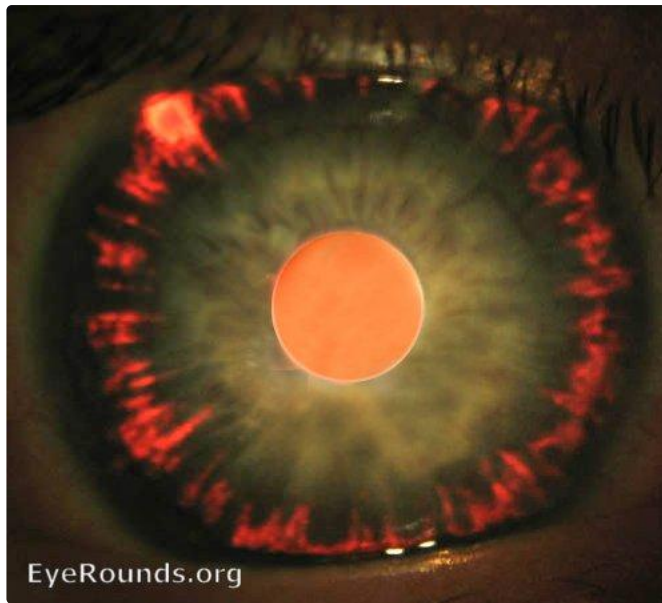


Pigment dispersion syndrome / glaucoma

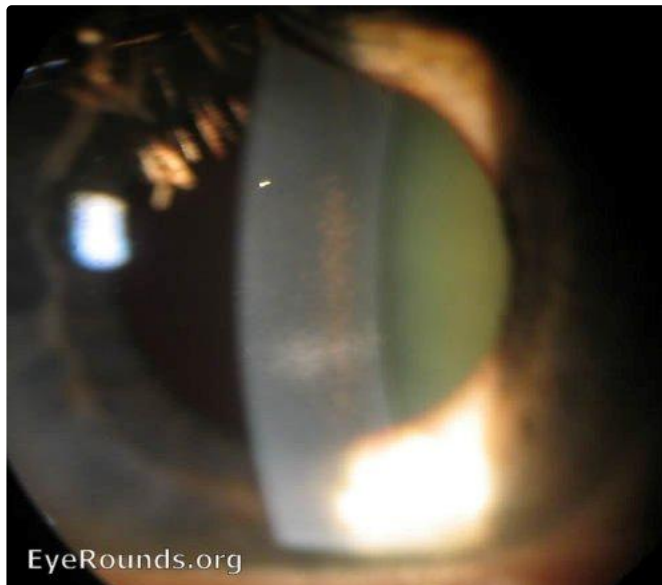
Category(ies): [Glaucoma / Iris](#)

Contributor: [Andrew Doan, MD, PhD](#)



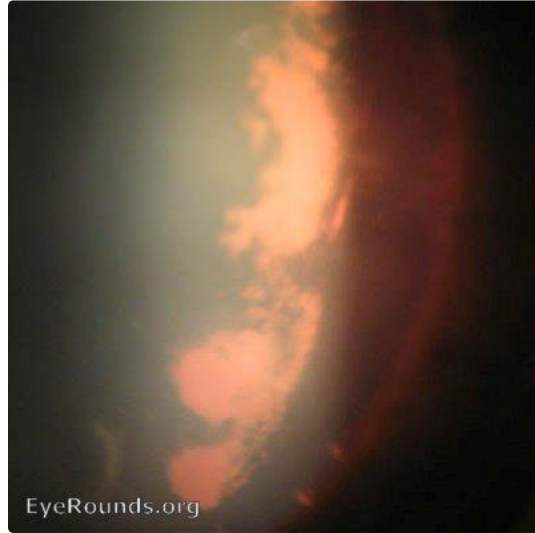1) Iris transillumination defects in a radial pattern (backbowing of iris rubs on lens zonules).

[Enlarge](#) [Download](#)



2) Krukenberg Spindle (pigment) dispersed on the corneal endothelium

[Enlarge](#) [Download](#)



3) Scheie's stripe: pigment on the lens capsule

[Enlarge](#) [Download](#)



4) Krukenberg Spindle (pigment) dispersed on the corneal endothelium

[Enlarge](#) [Download](#)

Image Permissions:



Ophthalmic Atlas Images by [EyeRounds.org](#), [The University of Iowa](#) are licensed under a [Creative Commons Attribution-NonCommercial-NoDerivs 3.0 Unported License](#).

Address

University of Iowa
Roy J. and Lucille A. Carver College
of Medicine
Department of Ophthalmology and
Visual Sciences
200 Hawkins Drive
Iowa City, IA 52242

[Support Us](#)

Legal

Copyright © 2019 The University of
Iowa. All Rights Reserved
[Report an issue with this page](#)
[Web Privacy Policy](#) |
[Nondiscrimination Statement](#)

Related Links

[Cataract Surgery for Greenhorns](#)
[EyeTransillumination](#)
[Gonioscopy.org](#)
[Iowa Glaucoma Curriculum](#)
[Iowa Wet Lab](#)
[Patient Information](#)
[Stone Rounds](#)
[The Best Hits Bookshelf](#)

EyeRounds Social Media

Follow



[Receive notification of new cases,
sign up here](#)
[Contact Us](#)
[Submit a Suggestion](#)