

Retinal astrocytoma

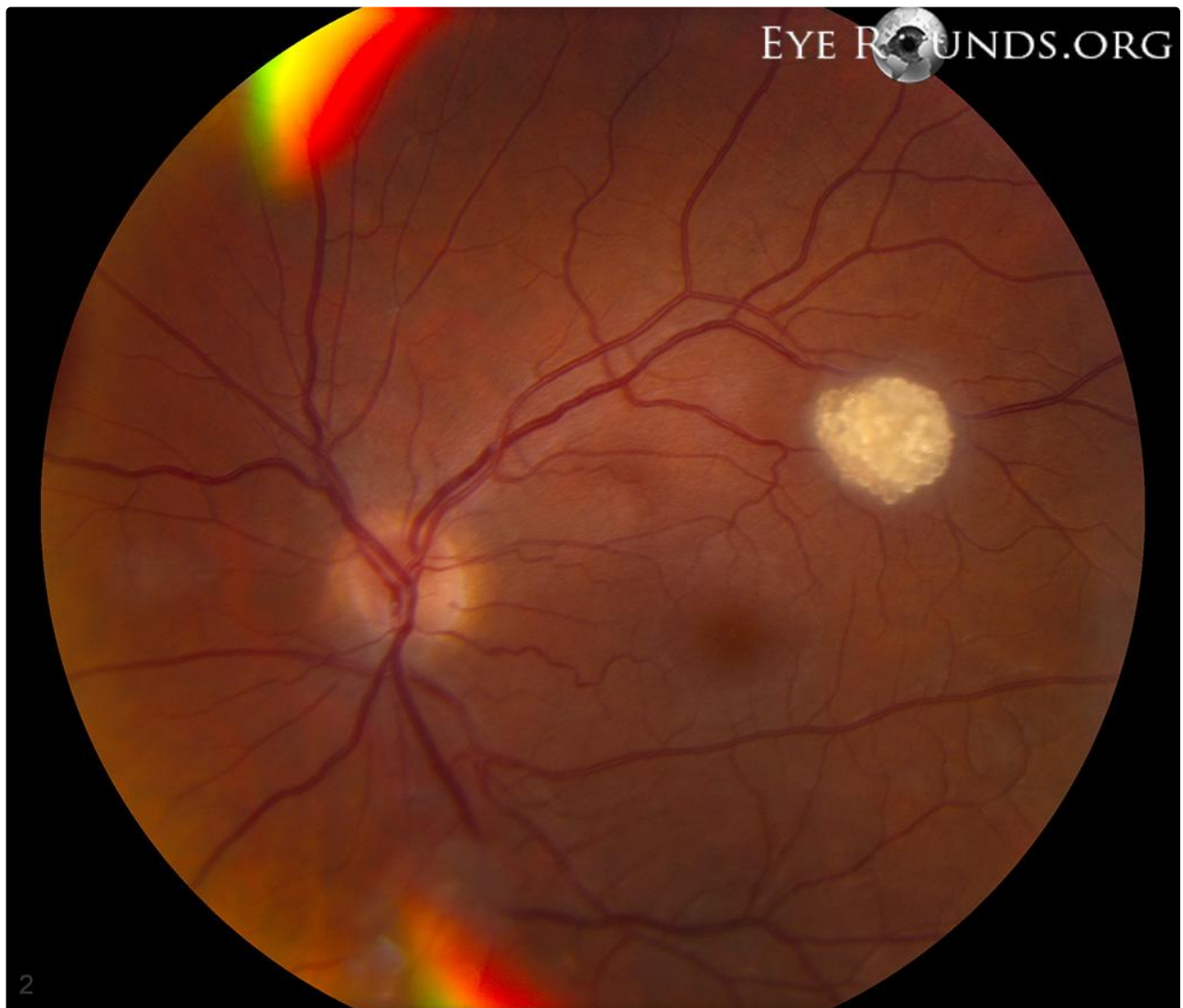
Category(ies): [Retina, Vitreous](#)

Contributor: [Justin Risma, MD](#)

Updated and Expanded by: [Cameron Wagner, BS](#) and [Lorraine M. Provencher, MD](#)



Retinal Astrocytoma is a rare benign glioma that typically occurs in childhood and adolescence. Most patients have no visual disturbance with initial presentation. Symptoms usually occur with tumor involvement of the macula. Retinal astrocytomas typically appear white in color, opaque, or translucent, with varying degrees of thickness. Tumors are typically comprised of large, fibrous astrocytes containing small, oval nuclei. Larger tumors may develop areas of calcification. Retinal astrocytomas may be unilateral or bilateral. Patients can sometimes present with an astrocytoma as a manifestation of tuberous sclerosis, which is more commonly seen with bilateral astrocytomas. Retinal astrocytomas rarely become malignant, and treatment is usually observation. Tumors that continue to grow or cause symptoms may require surgical intervention.



References:

1. Tasman W and Jaeger EA. Atlas of Clinical Ophthalmology. Chapter 7: Retinal Tumors. Ed. 2001: 274-275.

Image Permissions:



Ophthalmic Atlas Images by [EyeRounds.org](#), [The University of Iowa](#) are licensed under a [Creative Commons Attribution-NonCommercial-NoDerivs 3.0 Unported License](#).

Address

University of Iowa
Roy J. and Lucille A. Carver College
of Medicine
Department of Ophthalmology and
Visual Sciences
200 Hawkins Drive
Iowa City, IA 52242

[Support Us](#)

Legal

Copyright © 2019 The University of
Iowa. All Rights Reserved
[Report an issue with this page](#)
[Web Privacy Policy](#) |
[Nondiscrimination Statement](#)

Related Links

[Cataract Surgery for Greenhorns](#)
[EyeTransillumination](#)
[Gonioscopy.org](#)
[Iowa Glaucoma Curriculum](#)
[Iowa Wet Lab](#)
[Patient Information](#)
[Stone Rounds](#)
[The Best Hits Bookshelf](#)

EyeRounds Social Media

Follow



Receive notification of new cases,
[sign up here](#)
[Contact Us](#)
[Submit a Suggestion](#)