

Sclopetaria

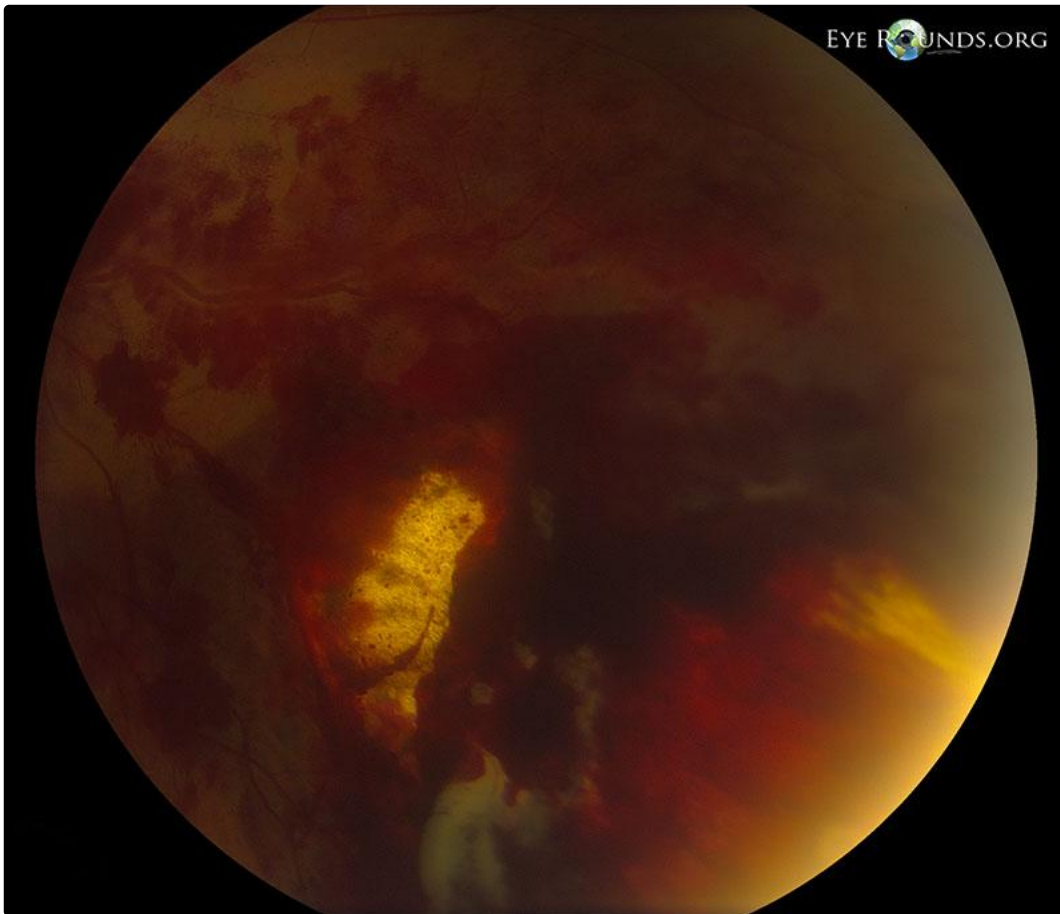
Category(ies): Retina

Contributor: [Elizabeth Gauger, MD](#)

Photographer: Stefani Karakas, CRA

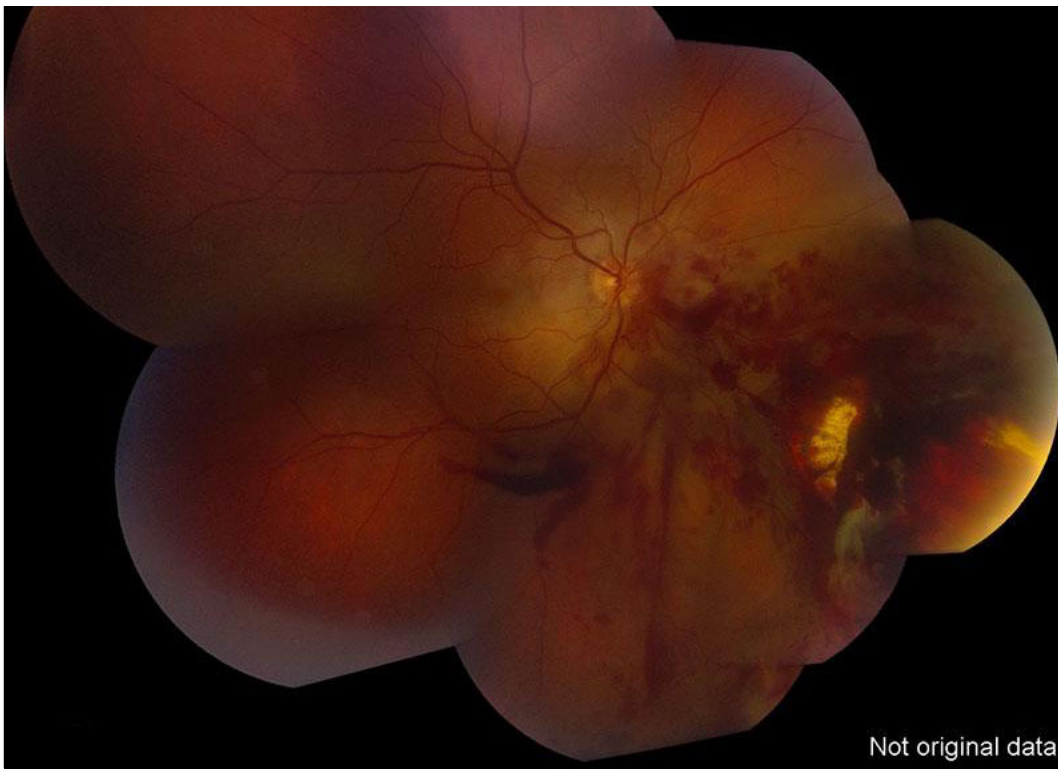

18-year-old male who suffered an ocular injury from a BB discharged from a BB gun. The BB entered the medial aspect of the orbit, but did not penetrate the globe. The photo shows inferonasal sclopetaria with associated intraretinal and pre-retinal hemorrhage. Sclopetaria is often seen after high-velocity injury to the orbit. Also note the extensive commotio retinae, or retinal whitening, especially in the macula and around the optic disc. No retinal holes or tears were identified.



[Enlarge](#) [Download](#)





[Enlarge](#) [Download](#)

Image Permissions:



Ophthalmic Atlas Images by [EyeRounds.org](#), [The University of Iowa](#) are licensed under a [Creative Commons Attribution-NonCommercial-NoDerivs 3.0 Unported License](#).

Address

University of Iowa
Roy J. and Lucille A. Carver College
of Medicine
Department of Ophthalmology and
Visual Sciences
200 Hawkins Drive
Iowa City, IA 52242

[Support Us](#)

Legal

Copyright © 2019 The University of
Iowa. All Rights Reserved
[Report an issue with this page](#)
[Web Privacy Policy](#) |
[Nondiscrimination Statement](#)

Related Links

[Cataract Surgery for Greenhorns](#)
[EyeTransillumination](#)
[Gonioscopy.org](#)
[Iowa Glaucoma Curriculum](#)
[Iowa Wet Lab](#)
[Patient Information](#)
[Stone Rounds](#)
[The Best Hits Bookshelf](#)

EyeRounds Social Media

Follow



Receive notification of new cases,
[sign up here](#)
[Contact Us](#)
[Submit a Suggestion](#)