

Traumatic aniridia and cataract

Category(ies): [Cataract](#), [Lens](#), [Iris](#), [Trauma](#)

Contributor: [Elizabeth Gauger, MD](#)

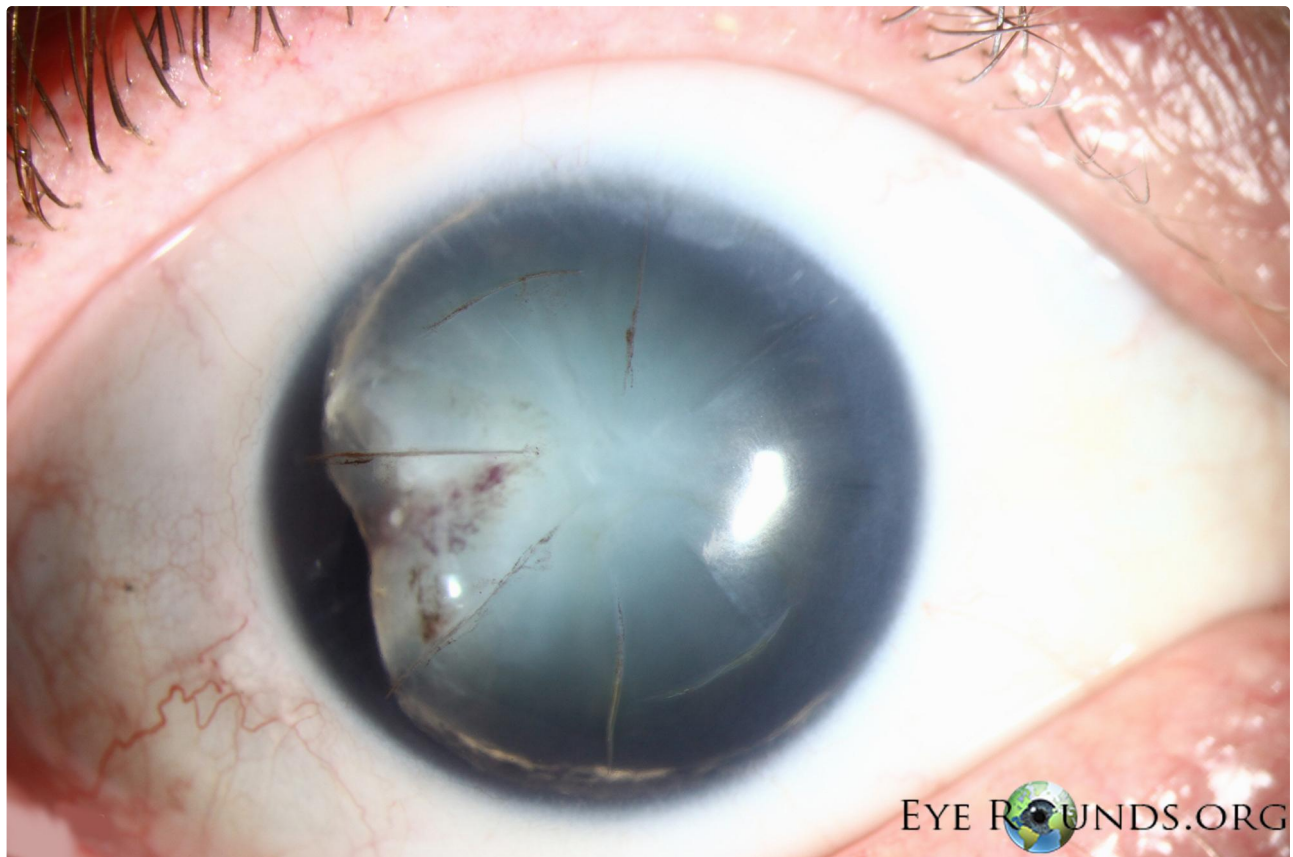Photographer: [Toni Venckus, CRA](#)

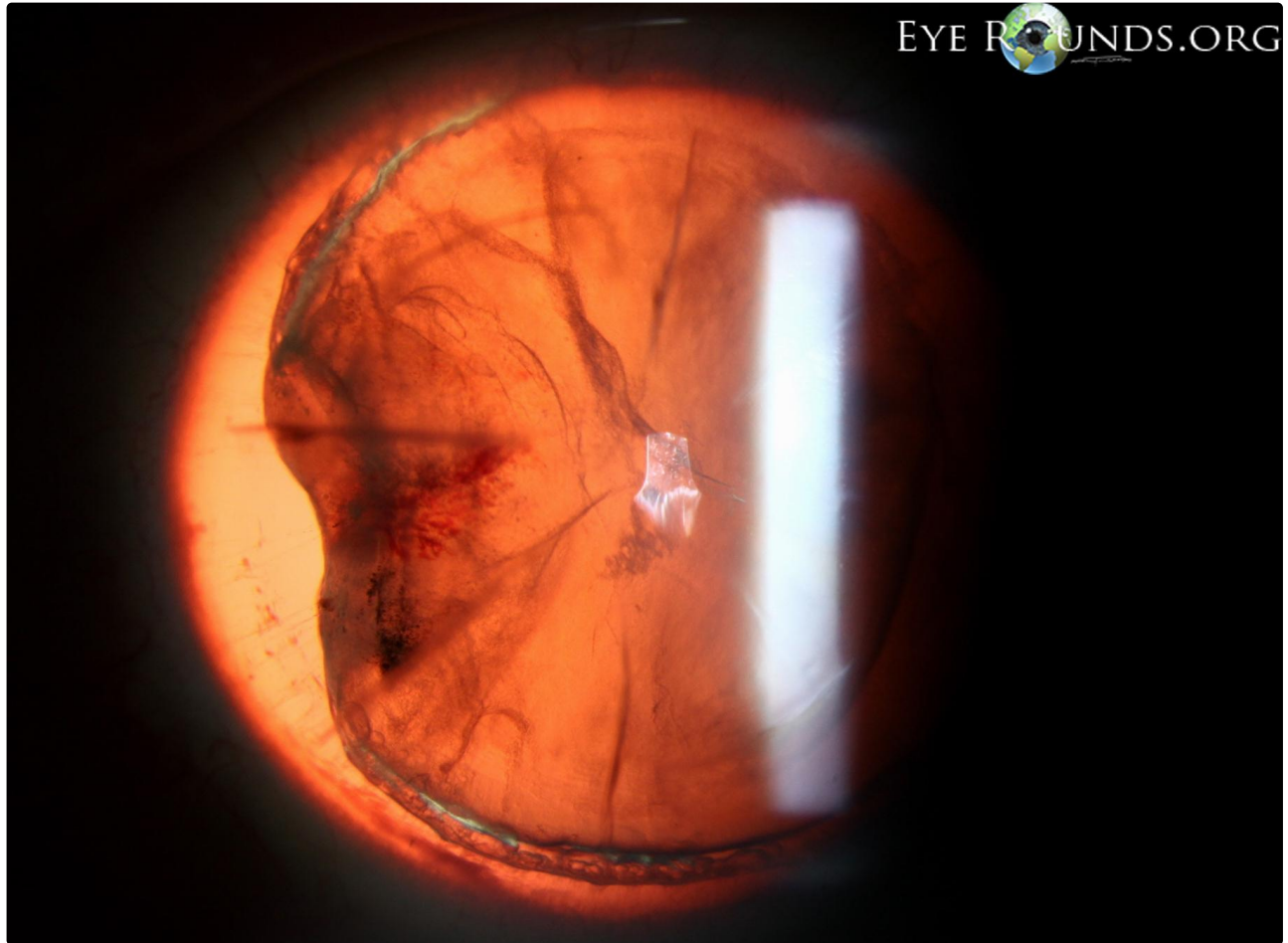


59-year-old male with past ocular history of radial keratotomy (RK) in both eyes, presented to our clinic after sustaining an injury to his right eye with a wrench. Initially there was nearly a complete hyphema and no view of iris, lens, or posterior pole. B scan echography did not show any posterior pathology. Several months later, after the hyphema had resolved, the patient returned with the exam seen below. His vision was hand motions at this time and he was noted to have a traumatic cataract in the right eye. Interestingly, the iris was noted to be missing on exam. There was no evidence of even a small iris stump on gonioscopy. Previous photos of the patient confirmed that he did, at one time, have both a clear lens and complete iris.

He was also noted to have pigment on his RK scars. After discussion amongst several faculty, the current hypothesis is that he may have had an open globe with the initial injury, and the iris may have prolapsed through one of his RK scars. This may have been inadvertently wiped from the eye by the patient, prior to his seeking medical care. The RK wound may have then self-sealed.

This patient was referred to another ophthalmologist for cataract extraction and insertion of a pupillary prosthesis.





[Enlarge](#) [Download](#)

Image Permissions:



Ophthalmic Atlas Images by [EyeRounds.org](#), [The University of Iowa](#) are licensed under a [Creative Commons Attribution-NonCommercial-NoDerivs 3.0 Unported License](#).

Address

University of Iowa
Roy J. and Lucille A. Carver College
of Medicine
Department of Ophthalmology and
Visual Sciences
200 Hawkins Drive
Iowa City, IA 52242

[Support Us](#)

Legal

Copyright © 2019 The University of
Iowa. All Rights Reserved
[Report an issue with this page](#)
[Web Privacy Policy](#) |
[Nondiscrimination Statement](#)

Related Links

[Cataract Surgery for Greenhorns](#)
[EyeTransillumination](#)
[Gonioscopy.org](#)
[Iowa Glaucoma Curriculum](#)
[Iowa Wet Lab](#)
[Patient Information](#)
[Stone Rounds](#)
[The Best Hits Bookshelf](#)

EyeRounds Social Media

Follow



Receive notification of new cases,
[sign up here](#)
[Contact Us](#)
[Submit a Suggestion](#)