

High-water mark after resolution of acute optic nerve head edema

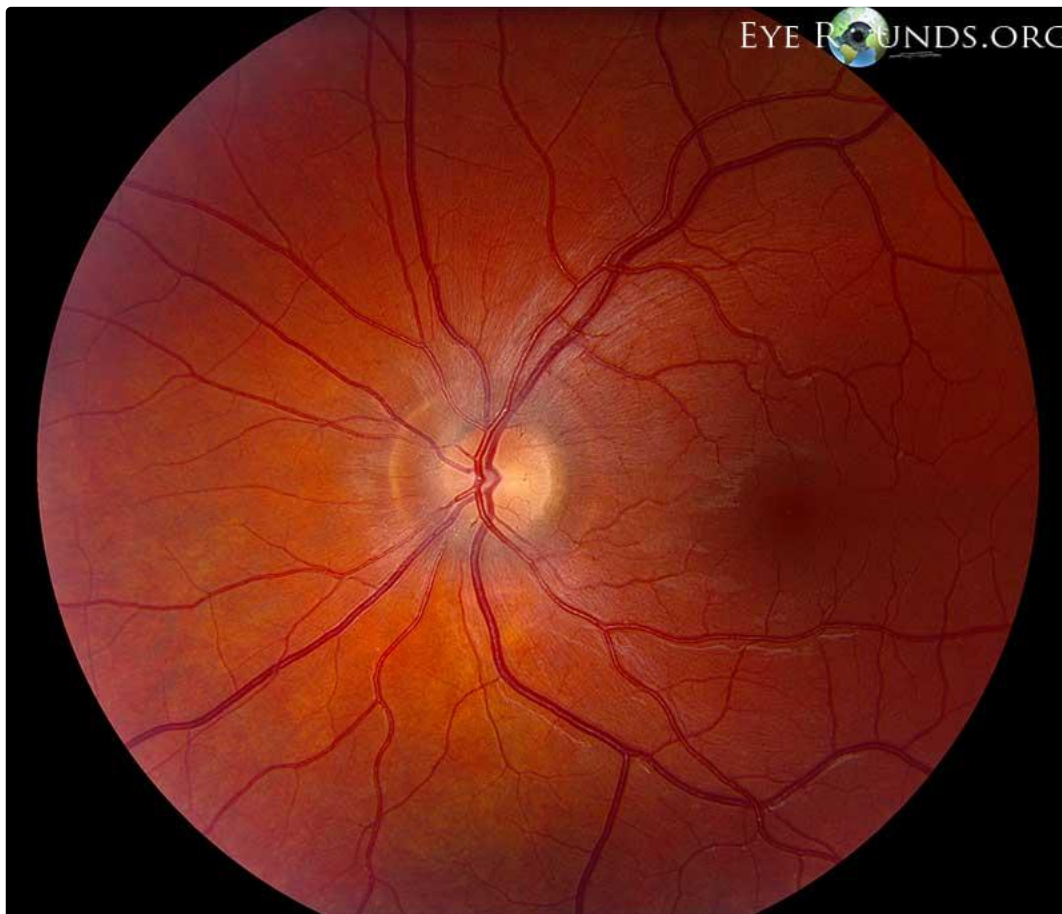
Category(ies): Retina, Vitreous, Neuro-ophthalmology

Contributor: Elizabeth Gauger, MD

Photographer: Cindy Montague, CRA



25-year-old female with history of acute left optic nerve head edema, now resolved. In this photo you can see a circumpapillary 'high-water mark'. When seen, this defines the prior extent of retinal elevation after the acute edema resolves. This artifact may take months or years to disappear.



[Enlarge](#) [Download](#)

Image Permissions:



Ophthalmic Atlas Images by [EyeRounds.org](#). The University of Iowa are licensed under a [Creative Commons Attribution-NonCommercial](#)

Address

University of Iowa
Roy J. and Lucille A. Carver College
of Medicine
Department of Ophthalmology and
Visual Sciences
200 Hawkins Drive
Iowa City, IA 52242

[Support Us](#)

Legal

Copyright © 2019 The University of
Iowa. All Rights Reserved
[Report an issue with this page](#)
[Web Privacy Policy](#) |
[Nondiscrimination Statement](#)

Related Links

[Cataract Surgery for Greenhorns](#)
[EyeTransillumination](#)
[Gonioscopy.org](#)
[Iowa Glaucoma Curriculum](#)
[Iowa Wet Lab](#)
[Patient Information](#)
[Stone Rounds](#)
[The Best Hits Bookshelf](#)

EyeRounds Social Media

Follow



Receive notification of new cases,
[sign up here](#)
[Contact Us](#)
[Submit a Suggestion](#)