

# Polymorphic Amyloid Degeneration

## 73-year-old asymptomatic patient with filamentous corneal opacities

Joy N. Carroll, [Amanda C. Maltry, MD](#), [Anna S. Kitzmann, MD](#)

July 29, 2013

### Chief Complaint

A 73-year-old woman with pseudophakia returns for one-year follow-up.

### History of Present Illness

Since cataract extraction last year, the patient has enjoyed her improved vision with no complaints.

### Past Ocular History

Pseudophakia, both eyes, 2009

Posterior YAG capsulotomy, left eye

Refractive error and presbyopia, both eyes

### Medical History

Obesity, hypertension, hypercholesterolemia

### Medications

No ocular medications. Systemic medications: amlodipine, atorvastatin, hydrochlorothiazide

### Family History

No family history of glaucoma, macular degeneration, blindness or known ocular diseases.

### Social History

Smoking history of 17 pack years, quit in 1975. Alcohol use is <1 drink per week.

### Ocular Exam

- Visual acuity (distance with correction):
- Right eye (OD): 20/30, pinhole to 20/25
- Left eye (OS): 20/40, pinhole to 20/25
- Intraocular pressure (applanation): OD 13, OS 14
- Pupils: Equal, round, 3 mm in dark, 2 mm in light, no relative afferent pupillary defect
- Visual fields: Full to confrontation both eyes (OU)
- Motility: Full OU

### Slit lamp exam

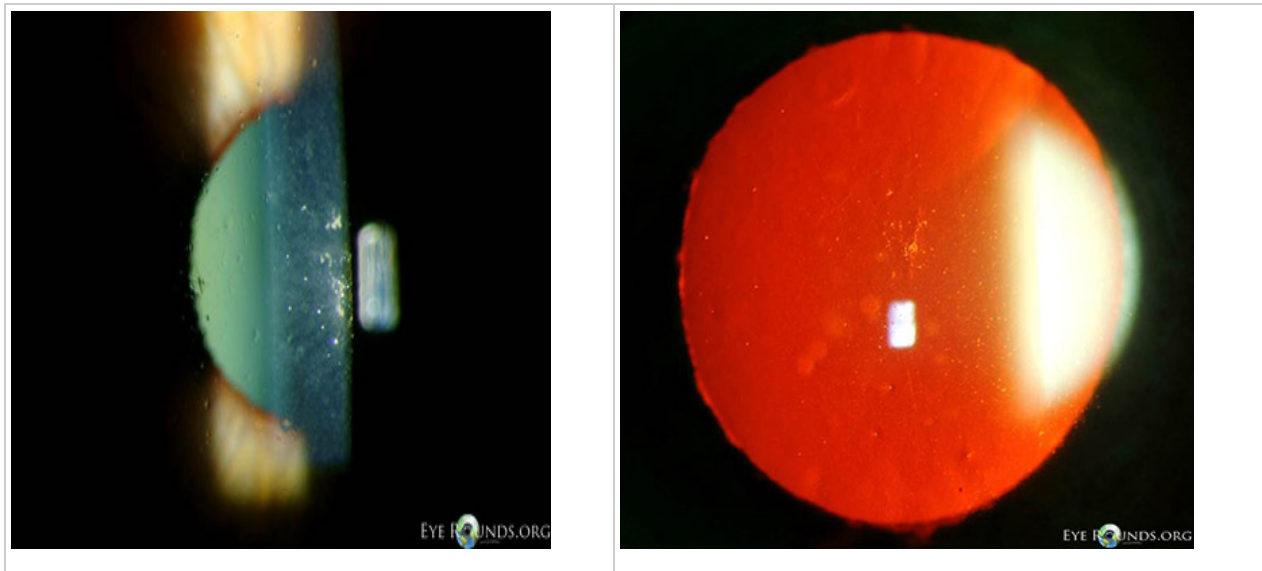
- External: Normal OU
- Lids & lashes: Dermatochalasis, normal lashes OU
- Conjunctiva & sclera: No injection OU
- Cornea: Polymorphous glass like deposits in the deep corneal stroma OU
- Anterior chamber: Deep and quiet OU
- Iris: Normal architecture OU

- Lens: Posterior chamber intraocular lens (PCIOL) with trace superior peripheral posterior capsular opacification OD; PCIOL with open posterior capsule OS
- Vitreous: Normal OU

### Dilated fundus exam

- Disc: Normal, cup-to-disc ratio 0.5 OU
- Vessels: Normal OU
- Macula: Normal OU
- Periphery: Normal OU

**Figure 1: Slit Lamp Photos (click on image for higher resolution)**



### Diagnosis

Based on the clinical appearance and asymptomatic nature of her corneal opacities, the patient was diagnosed with polymorphic amyloid degeneration.

### Treatment

Since visual acuity was not affected, no treatment was necessary.

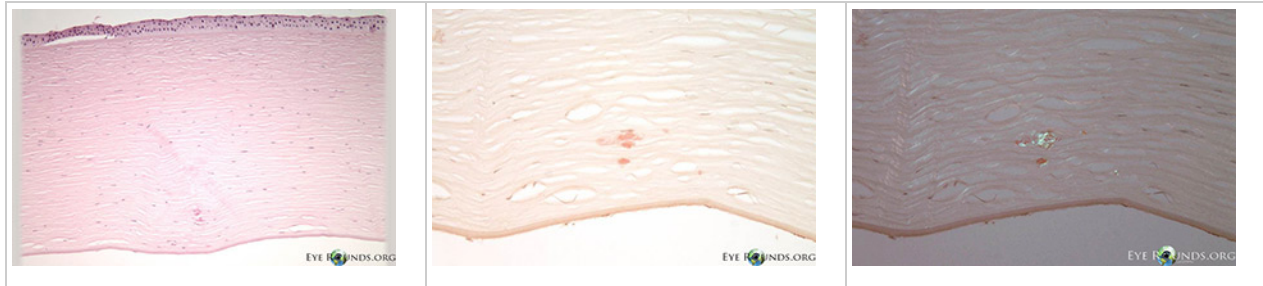
### Course

The patient continued yearly routine exams and her vision remained stable, with only small changes in refractive error. Her exam also remained stable with no change in the quantity or quality of the corneal opacities.

### Pathology

Polymorphic amyloid degeneration is not visually significant, and corneal transplantation is not indicated. However, when intrastromal amyloid is identified incidentally in corneal tissue obtained for other reasons, polymorphic amyloid degeneration is on the differential diagnosis. There are no histology slides from this patient's case because polymorphic amyloid degeneration does not cause decreased visual acuity. Figure 2 A,B,C shows the histopathology findings of polymorphic amyloid degeneration in a different patient who had a penetrating keratoplasty for pseudophakic corneal edema.

**Figure 2: Corneal histopathology.** Corneal tissue from an 84-year-old male who underwent penetrating keratoplasty for pseudophakic corneal edema. **A.** Microscopic examination shows occasional eosinophilic deposits within the deep stroma. There is also hydropic degeneration of the corneal epithelium, subepithelial bullae, loss of artifactitious clefting, and severely attenuated endothelium consistent with bullous keratopathy. H&E, 50x. **B.** The deposits are positive with Congo red. 100x. **C.** The deposits exhibit apple green birefringence on cross polarization. 100x. (click on image for higher resolution)



## Discussion

Polymorphic amyloid degeneration is a bilateral non-heritable condition of middle and old age characterized by non-progressive amyloid deposition within the mid and deep corneal stroma. The deposits form polymorphous and filamentous opacities in an axial distribution [1]. There is no associated inflammation, vascularization, or altered visual acuity [2].

There has been no identified genetic basis of inheritance of polymorphic amyloid degeneration [3,4]. Onset of disease is in people ages 50 years or older, and the amyloid deposits do not appear to progress [3]. Polymorphic amyloid degeneration is thought to be sporadic, with no clear sex predominance, nor any consistent association with systemic or ocular disease, although it has been identified in case reports of unrelated diseases [1,5,6].


The diagnosis is made by slit lamp examination, which reveals gray-white axial deep stromal opacities of the cornea. Clear, refractile, stromal filamentous opacities are evident by retroillumination [7].

Histopathological diagnosis, which is not required and only found incidentally on patients that undergo corneal transplantation for other reasons, may be made with Congo red staining of the amyloid in the deep stroma, with dichromaticism under polarized light. Electron microscopy shows filaments and punctate lesions woven between normal stromal collagen [5].

The name polymorphic amyloid degeneration was suggested by Mannis et al in 1975. The previous name, polymorphous stromal dystrophy, was suggested by Thomsitt and Bron [2]. The reason this condition was renamed as a degeneration instead of a dystrophy was the lack of evidence of heritability, and its detectable presence only in people greater than 50 years of age.

Since the diagnosis of polymorphic amyloid degeneration is a clinical diagnosis, an additional example of polymorphic amyloid degeneration is displayed in Figure 3.

**Figure 3: Retroillumination of another patient with polymorphic amyloid degeneration.** (click on image for higher resolution)



For a summary of the key facts regarding polymorphic amyloid degeneration, see Table below.

**Table 1**

<p><b>Epidemiology</b></p> <ul style="list-style-type: none"> <li>• No genetic basis of inheritance [3,4]</li> <li>• Onset at 50 years or older [3]</li> <li>• No clear sex predominance [1]</li> <li>• Deposits do not progress [3]</li> <li>• No consistently associated systemic or ocular disease [1]</li> </ul>	<p><b>Signs</b></p> <ul style="list-style-type: none"> <li>• Bilateral gray or white polymorphous and/or filamentous opacities in the mid to deep corneal stroma, most commonly in a mid-peripheral annular distribution [1]. Retroillumination reveals clear, refractile stromal filamentous opacities [7].</li> <li>• No associated inflammation or vascularization [2]</li> </ul> <p><b>Diagnosis</b></p> <ul style="list-style-type: none"> <li>• Clinical: based on slit lamp exam</li> <li>• Histopathology: eosinophilic stromal deposits stain with Congo red and are dichromatic under polarized light. They are PAS negative, and with Masson's trichrome they stain red [1].</li> <li>• In one case report, confocal microscopy showed reflective punctate lesions within Descemet's membrane, deep stroma, and anterior corneal stroma [7].</li> </ul>
<p><b>Symptoms</b></p> <ul style="list-style-type: none"> <li>• Normal visual acuity [1] or</li> <li>• Visual acuity decreased by as much as one line [2]</li> </ul>	<p><b>Treatment</b></p> <ul style="list-style-type: none"> <li>• None</li> </ul>

**Conclusion**

Polymorphic amyloid degeneration is a condition characterized by stromal gray-white opacities that do not progress or impair visual acuity after presentation in the sixth decade of life. The diagnosis is based on clinical examination. Any change in vision should prompt a search for other causes or reconsideration of the diagnosis of polymorphic amyloid degeneration.

**Differential diagnosis**

- Lattice corneal dystrophy Type 1 (TFGBI type)
- Granular corneal dystrophy Type 2 (Granular-lattice dystrophy)
- Fleck dystrophy
- Schnyder crystalline corneal dystrophy
- Cornea farinata

## References

1. Mannis MJ, Krachmer JH, Rodrigues MM, Pardos GJ. Polymorphic amyloid degeneration of the cornea. A clinical and histopathologic study. *Arch Ophthalmol*. 1981; 99:1217-1223. [PMID: 6973332]
2. Thomsitt L, Bron AJ. Polymorphic stromal dystrophy. *Br J Ophthalmol*. 1975;59:125-132. [PMID: 1079457]
3. Molia LM, Lanier JD, Font RL. Posterior polymorphous dystrophy associated with posterior amyloid degeneration of the cornea. *Am J Ophthalmol*. 1999 Jan;127(1):86-8. [PMID: 9933006]
4. Nirankari VS, Rodrigues MM, Rajagopalan S, Brown D. Polymorphic amyloid degeneration. *Arch Ophthalmol*. 1989 Apr;107(4):598. [PMID: 2705931]
5. Krachmer JH, Dubord PJ, Rodrigues MM, et al. Corneal posterior crocodile shagreen and polymorphic amyloid degeneration. *Arch Ophthalmol*. 1983; 101:54-59. [PMID: 6600392]
6. Waring GO 3rd, Malaty A, Grossniklaus H, Kaj H. Climatic proteoglycan stromal keratopathy, a new corneal degeneration. *Am J Ophthalmol*. 1995 Sep;120(3):330-41. [PMID: 7661205]
7. Woodward M, Randleman JB, Larson PM. In vivo confocal microscopy of polymorphic amyloid degeneration and posterior crocodile shagreen. *Cornea*. 2007 Jan;26(1):98-101. [PMID: 17198022]
8. Karp CL, Scott IU, Green WR, Chang TS, Culbertson WW. Central cloudy corneal dystrophy of Francois. A clinicopathologic study. *Arch Ophthalmol*. 1997 Aug;115(8):1058-62. [PMID: 9258229]

## Suggested citation format

Carroll JN, Maltry AC, Kitzmann AS. Polymorphic Amyloid Degeneration: 73-year-old asymptomatic patient with filamentous corneal opacities. *EyeRounds.org*. June 29, 2013; available from <http://EyeRounds.org/cases/173-Polymorphic-amyloid-degeneration.htm>