

Morning Glory Disc Anomaly

[Brandon S. Baksh, MD](#); [Joanna I.M. Silverman, MD](#); [Alina V. Dumitrescu, MD](#)

January 22, 2024



INITIAL PRESENTATION

Chief Complaint: Monocular esotropia

History of Present Illness (HPI): A 4-year-old girl was initially referred by her pediatrician to an outside ophthalmologist for decreased visual acuity and esotropia in the left eye. Her mother endorsed left eye crossing, poor balance, and speech delay, but the patient was otherwise meeting appropriate developmental milestones and was asymptomatic from an ocular standpoint. Initial exam by the outside ophthalmologist revealed an anomalous, funnel-shaped left optic nerve. The patient was ultimately referred to the University of Iowa for further evaluation.

Past Ocular History

- None

Past Medical History

- Normal gestational age at birth, normal weight at birth

Medications

- None

Allergies

- No known allergies

Family History

- Older sister with Dandy-Walker malformation
- Maternal aunt with "low vision in one eye" since childhood

Social History

- Unremarkable

Review of Systems

- Unremarkable other than as noted in history of present illness

OCULAR EXAMINATION

- **Visual Acuity without correction by LEA symbols**
 - Right eye (OD): 20/30
 - Left eye (OS): Count fingers at 4 feet eccentrically
- **Intraocular Pressure (IOP, by Tonopen)**
 - OD: 13 mmHg
 - OS: 11 mmHg

- **Pupils**
 - OD: no afferent pupillary defect
 - OS: trace afferent pupillary defect
- **Confrontation visual fields**
 - OD: Full
 - OS: Unable to perform
- **Ocular Motility/Alignment by Modified Krimsky method, without correction**
 - OD: orthotropic, full motility
 - OS: esotropia measuring 20 prism diopters at distance and 12 prism diopters at near, full motility
- **Cycloplegic refraction**
 - OD: +1.75 +0.50 100°
 - OS: +1.25 sphere
- **External**
 - Normal, both eyes

- **Slit lamp exam**

| | OD | OS |
|-------------------|---------------------|---------------------|
| Lids/Lashes | Normal | Normal |
| Conunctiva/Sclera | Clear and quiet | Clear and quiet |
| Cornea | Clear | Clear |
| Anterior Chamber | Deep and quiet | Deep and quiet |
| Iris | Normal architecture | Normal architecture |
| Lens | Clear | Clear |
| Anterior Vitreous | Normal | Normal |

- **Dilated fundus examination (DFE)**

| | OD | OS |
|-----------|--------|--|
| Vitreous | Normal | Normal |
| Disc | Normal | Anomalous optic nerve, with enlargement and gliosis. Peripapillary elevation with white fibrosis |
| Macula | Normal | Foveal hypoplasia |
| Vessels | Normal | Normal |
| Periphery | Normal | Normal |

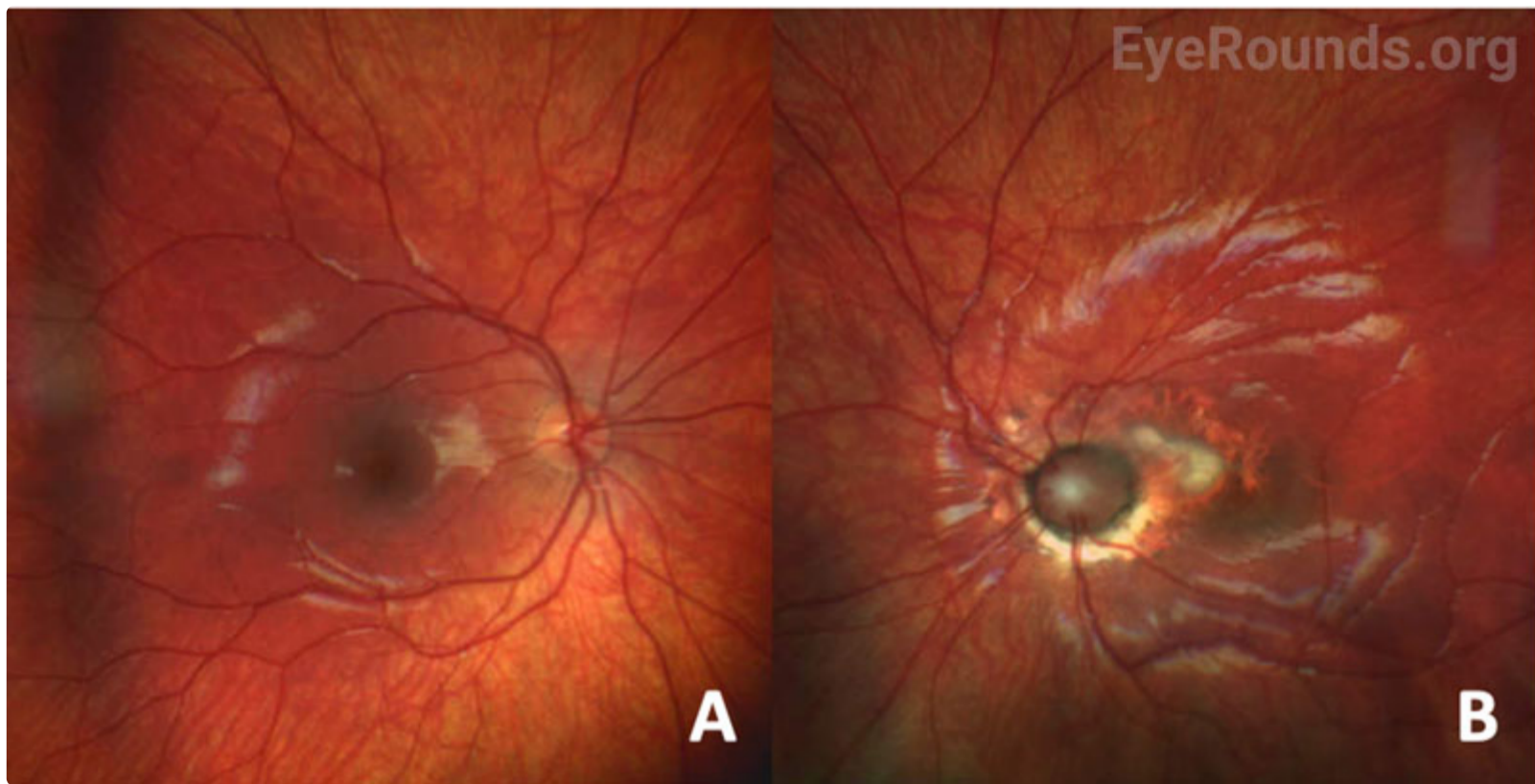


Figure 1. Color fundus photos of right and left eyes. **A.** Unremarkable appearance of the right eye optic nerve and retina. **B.** Anomalous optic nerve in the left eye with deep cup, peripapillary atrophy and gliosis, and straight radial peripapillary vessels. There is fibrosis of the superonasal macula with surrounding retinal atrophy.

[Enlarge](#) [Download](#)

• **Optical coherence tomography (OCT) of optic nerve head (Figure 2)**

- OD: no retinal nerve fiber layer or ganglion cell layer thinning, no disc edema, normal appearance of optic nerve head
- OS: anomalous optic nerve with enlarged disc area (2.64 mm²) and cup (cup:disc ratio 0.60) with peripapillary gliosis, no disc edema

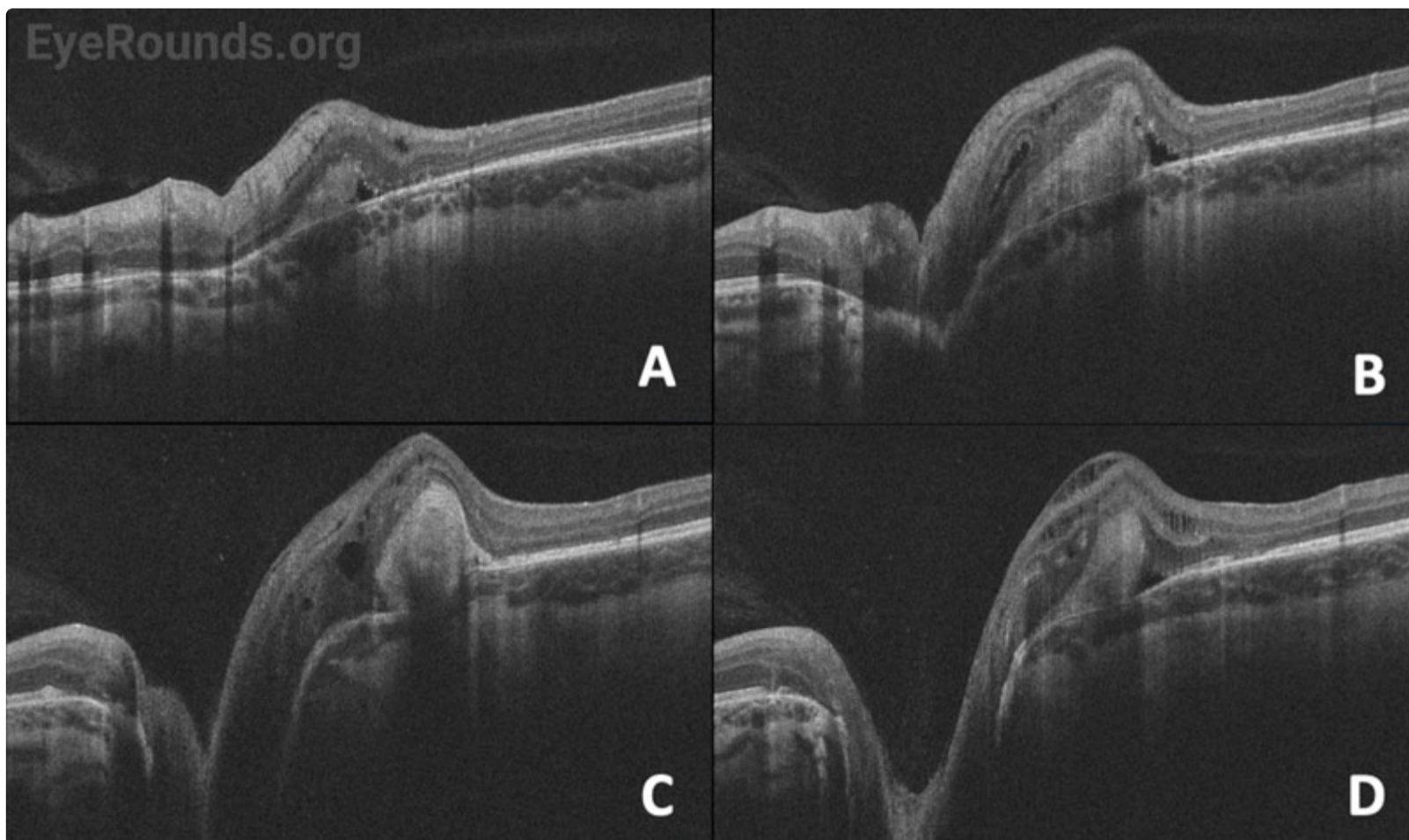


Figure 2. OCT of the optic nerve, left eye. OCT cross-sections of left optic and peripapillary area superiorly (A,B) and inferiorly (C,D). The optic disc is anomalous with temporal peripapillary subretinal gliosis and adjacent pockets of subretinal and intraretinal fluid.

[Enlarge](#) [Download](#)

Differential Diagnosis

- [Optic nerve head coloboma](#)
- [Optic nerve pit](#)

- [Peripapillary staphyloma](#)
- Advanced glaucomatous optic neuropathy

DIAGNOSIS: Morning Glory Disc Anomaly

CLINICAL COURSE

The patient's exam findings were consistent with morning glory disc anomaly (MGDA) of the left eye. Magnetic resonance imaging (MRI) with angiography (MRA) was overall unremarkable without evidence of basal encephalocele, cerebral vascular malformation, or cranial midline/chiasmal abnormalities. Genetic testing via chromosomal microarray did not demonstrate any causative genetic variant.

DISCUSSION

Etiology/Epidemiology

Morning glory disc anomaly (MGDA) is a congenital malformation of the optic nerve head, first reported by Dr. Peter Kindler in 1970. He described a congenital, funnel-shaped, excavated, enlarged optic disc with central white-colored fibrous tissue, peripapillary pigmentary changes, and straight branches of retinal vessels emanating radially from the optic disc edge [1]. It is named due to its resemblance to the morning glory flower. Literature on the prevalence of MGDA is sparse. However, most reported cases are observed to be unilateral and sporadic [2]. Approximately 16% of cases are bilateral [3]. A 2015 cross-sectional study by Ceynowa et al. reviewed a population of 2.1 million Swedish individuals, and reported an estimated prevalence of 2.6 cases per 100,000 individuals [2]. Median age of diagnosis in this study was 0.5 years old (range 0-4 years) [2].

Pathophysiology

While the pathophysiology of MGDA is not well understood, this optic head malformation is thought to be secondary to abnormal differentiation of mesodermal tissues. Specifically, incomplete closure of the posterior sclera and partial evolution of the lamina cribrosa have been largely implicated in these progressive optic nerve changes, allowing for anterior herniation of the disc and adjacent retina. Some element of neuroectodermal dysgenesis may contribute to the final phenotype of MGDA, as evidenced by the hallmark central gliosis and abnormal vascular pattern [4].

Histopathologic studies have provided additional insight into the underlying pathogenesis with reports of abnormalities of posterior pole structures, including peripapillary scleral ectasia (staphyloma), absence of lamina cribrosa, absence of choroid, reduced number of ganglion cells and reduced retinal nerve fiber layer, absence of photoreceptors, glial tuft with psammoma bodies/glial cells/fibroblasts, attenuation of vessels, and hyperplastic persistent primary vitreous [5-6].

MGDA is usually sporadic. However, pathogenic variants in PAX6 gene have been identified in some families (7-8). Additionally, cavitory optic disc anomalies (CODA) – a disease spectrum including MGDA, megalopapilla, optic disc coloboma, and optic disc pit – are known to be inherited in an autosomal dominant fashion through mutations in the MMP19 gene [9].

Signs/Symptoms

Presenting signs include decreased vision, strabismus, nystagmus, and/or leukocoria. Visual acuity in the MGDA eye is usually poor. One study of 12 MGDA eyes found a median best-corrected visual acuity of 20/300 (range 20/30 - hand motion) [2]. Strabismus (eso- or exodeviation are most common) may be present in up to 70% of eyes affected by MGDA (10). Afferent pupil defects and visual field deficits are common.

Fundus examination reveals a large, funnel-shaped excavation of the optic nerve head and peripapillary retina, with surrounding annular pigmentary changes. A central glial tuft with straight, narrow branches of retinal vessels radiating from the optic disc edge in a straight fashion resembles the morning glory flower [1]. In some instances, the adjacent macula can be involved in the larger area of excavation, a phenomenon known as "macular capture." Other fundus findings may include subretinal fluid and retinal detachment.

Several case reports have described unilateral amaurotic episodes lasting 10-60 seconds in patients with known MGDA. Clinical dilated exams during these episodes describe temporary hyperemia, congestion of the normally excavated disc, and surrounding venous tortuosity. The proposed mechanism of heterotopic contractile tissue around the optic nerve and scleral canal explains these amaurotic episodes, as constriction of this tissue results in decreased venous flow and axonal block of the distal optic nerve [11]. Such symptoms are rare but should be investigated in the young patient presenting with frequent unilateral amaurosis.

Optic nerve coloboma may present similarly to MGDA and should be distinguished as they both have different systemic associations, described below. Fundus examination may also help distinguish MGDA and optic nerve coloboma, the latter of which tends to have an inferior white excavation extending into the choroid and retina while sparing the superior rim [12]. Optic nerve coloboma can be associated with CHARGE syndrome, which consists of coloboma of the eye, heart defects, choanal atresia, growth retardation, genitourinary and ear abnormalities.

Testing/Laboratory work-up

In addition to a thorough eye examination, including a fundus exam, additional ancillary testing may be helpful in determining a diagnosis of MGDA as well as assessing the extent of involvement. OCT is helpful in identifying the primary disc anomaly as well as associated findings, including intra/subretinal fluid, retinal holes, or peripapillary retinal detachments. B-scan echography can aid in further characterization of MGDA findings, including optic nerve excavation, central glial tuft, microphthalmos, and retinal tissue overhanging the posterior scleral staphyloma or “overhang sign” [13]. Furthermore, echography may help estimate the risk of retinal detachment. For example, in a retrospective review of 249 Chinese children, the ratio of cavitory depth to axial length greater than or equal to 0.25 was associated with an increased risk of retinal detachment (OR, 2.101; 95% CI 1.47-3.0) [14].

MRI/MRA should be obtained to evaluate for associated systemic vasculopathies (i.e. Moya-Moya) and midline central nervous system deformities, as outlined below.

Treatment/Management

In patients with MGDA, the first steps in management involve correcting refractive errors with glasses to improve acuity (as good as possible), address underlying amblyopia, and physically protect the better-seeing eye. Patching should be attempted to treat amblyopia but may be unsuccessful due to the underlying organic abnormality.

Several clinical associations commonly co-occur with MGDA, which require further evaluation. Retinal detachments are common in individuals with MGDA, with up to 14% of patients developing a detachment in 5 years of presentation and 33% in 10 years [15]. Successful retinal detachment repair has been reported with visual improvement for certain patients. Recurrence of retinal detachment is not unlikely [16]. Thus, patients with MGDA should have regular fundus examination to monitor for retinal detachments.

MGDA is also associated with midline facial and central nervous system abnormalities. These include cleft lip and palate, basal encephalocele (protrusion of neural tissue through a skull defect – trans-sphenoidal type), agenesis of corpus callosum, Chiari type 1 malformation, and pituitary gland dysgenesis [12]. As described above, these patients should undergo MRI to evaluate for presence of these defects. Subsequent endocrine workup may be indicated.

A potentially life-threatening association with MGDA is cerebrovascular abnormalities such as Moya-Moya disease, which is characterized by abnormally narrow cerebral vasculature resulting in ischemia, hemorrhage, seizure, intellectual impairment, or transient ischemic attacks. While the exact prevalence is unknown, Moya-Moya has been observed in up to 45% of patients with MGDA as reported in a small retrospective case series [17]. MRI/MRA or computed tomography angiography (CTA) is recommended as part of the work-up to evaluate for this cerebrovascular abnormality.

PHACE syndrome (posterior fossa malformation, large facial hemangioma, arterial anomalies, cardiac anomalies, eye anomalies) has also been reported in patients with MGDA [20].

| EPIDEMIOLOGY OR ETIOLOGY | DIAGNOSIS |
|---|--|
| <ul style="list-style-type: none"> • Abnormal development of posterior pole including sclera, choroid, and retina • Estimated prevalence of 2.6 cases per 100,000 individuals | <ul style="list-style-type: none"> • DFE/Exam under anesthesia • Optic nerve head OCT • Genetic testing |

| SYMPTOMS/SIGNS | TREATMENT/MANAGEMENT |
|--|--|
| <ul style="list-style-type: none"> Decreased vision, strabismus, nystagmus, and/or leukocoria, usually unilateral in young child Funnel-shaped excavation of the optic nerve head, peripapillary gliosis, and narrow, straight retinal vessels radiating from optic disc | <ul style="list-style-type: none"> Glasses/patching MRI/MRA for vascular and/or cerebral midline abnormalities Repair of retinal detachment, if present |

References

- Kindler P. Morning glory syndrome: unusual congenital optic disk anomaly. *Am J Ophthalmol.* 1970; 69: 376–384. PMID: 5418855.
- Ceynowa, D.J., Wickström, R., Olsson, M., Ek, U., Eriksson, U., Wiberg, M.K. and Fahnehjelm, K.T., Morning Glory Disc Anomaly in childhood – a population-based study. *Acta Ophthalmol*, 2015; 93: 626-634. PMID: 26173377.
- Cennamo G, de Crecchio G, Iacchino G & Forte R: Evaluation of morning glory syndrome with spectral optical coherence tomography and echography. 2010; *Ophthalmology* 117: 1269–1273. PMID: 20163868.
- Dempster AG, Lee WR, Forrester JV & McCreath GT: The ‘morning glory syndrome’ – a mesodermal defect? *Ophthalmologica Journal international d’ophtalmologie. International journal of ophthalmology* 1983; 187: 222–230. PMID: 6657186.
- Manschot W A. Morning glory syndrome: a histopathological study. *Br J Ophthalmol.* 1990; 74: 56–58. PMID: 2306447.
- Pedler C. Unusual coloboma of the optic nerve entrance. *Br J Ophthalmol.* 1961; 45: 803–807. PMID: 18170740.
- Azuma N, Yamaguchi Y, Handa H, et al. Mutations of the PAX6 gene detected in patients with a variety of optic-nerve malformations. *Am J Hum Genet.* 2003; 72: 1565–1570. PMID: 12721955.
- Graw J. Eye development. *Curr Top Dev Biol.* 2010;90:343-86. PMID: 20691855.
- Hazlewood RJ, Roos BR, Solivan-Timpe F, Honkanen RA, Jampol LM, Gieser SC, Meyer KJ, Mullins RF, Kuehn MH, Scheetz TE, Kwon YH, Alward WL, Stone EM, Fingert JH. Heterozygous triplication of upstream regulatory sequences leads to dysregulation of matrix metalloproteinase 19 in patients with cavitory optic disc anomaly. *Hum Mutat.* 2015 Mar;36(3):369-78. PMID: 25581579.
- Kim, M., Park, S. & Oh, S. Clinical Feature Analysis of Congenital Optic Nerve Abnormalities. *Jpn J Ophthalmol* 2006; 50, 250–255. PMID: 16767381.
- Brodsky MC. Contractile morning glory disc causing transient monocular blindness in a child. *Arch Ophthalmol.* 2006 Aug;124(8):1199-201. doi: 10.1001/archophth.124.8.1199. PMID: 16908828.
- Brian J. Lee & Elias I. Traboulsi Update on the Morning Glory Disc Anomaly, *Ophthalmic Genetics*, 2008; 29:2, 47-52. PMID: 18484308.
- Beyer W B, Quencer R M, Osher R H. Morning glory syndrome. A functional analysis including fluorescein angiography, ultrasonography, and computerized tomography. *Ophthalmology.* 1982; 89: 1362–1367. PMID: 7162781.
- Zou Y, She K, Hu Y, Ren J, Fei P, Xu Y, Peng J, Zhao P. Clinical and Echographic Features of Morning Glory Disc Anomaly in Children: A Retrospective Study of 249 Chinese Patients. *Front Med (Lausanne).* 2022 Jan 24;8:800623. PMID: 35141246.
- Haik BG, Greenstein SH, Smith ME, Abramson DH, Ellsworth RM. Retinal detachment in the morning glory anomaly. *Ophthalmology.* 1984 Dec;91(12):1638-47. PMID: 6441134.
- Sen P, Maitra P, Vaidya H, Bhende P, Das K. Outcomes of vitreoretinal surgery in retinal detachment associated with morning glory disc anomaly. *Indian J Ophthalmol.* 2021 Aug;69(8):2116-2121. PMID: 34304189.
- Lenhart P D, Lambert S R, Newman N J, et al. Intracranial vascular anomalies in patients with morning glory disk anomaly. *Am J Ophthalmol.* 2006; 142: 644–650. PMID: 17011858.
- Kniestedt C, Landau K, Brodsky M C, North P, Waner M. Infantile orofacial hemangioma with ipsilateral peripapillary excavation in girls: a variant of the PHACE syndrome. *Arch Ophthalmol* 2004; 122: 413–415.

Suggested citation format:

Baksh BS, Silverman JIM, Dumitrescu AV. **Morning Glory Disc Anomaly** . EyeRounds.org. Posted January 22, 2024; Available from <https://EyeRounds.org/cases/354-Morning-Glory-Disc-Anomaly.htm>

last updated: 01/22/2024

Image Permissions:



Ophthalmic Atlas Images by [EyeRounds.org](https://www.eyerounds.org), [The University of Iowa](https://www.theuniversityofiowa.edu) are licensed under a [Creative Commons Attribution-NonCommercial-NoDerivs 3.0 Unported License](https://creativecommons.org/licenses/by-nc-nd/3.0/).

University of Iowa
Roy J. and Lucille A. Carver College of Medicine
Department of Ophthalmology and Visual Sciences
200 Hawkins Drive
Iowa City, IA 52242

[Support Us](#)

Copyright © 2019 The University of Iowa. All Rights Reserved

[Report an issue with this page](#)

[Web Privacy Policy](#) | [Nondiscrimination Statement](#)

Follow



[Receive notification of new cases, sign up here](#)

[Contact Us](#)

[Submit a Suggestion](#)