

2022 AAO OPS Scientific Exhibit  
Photo Competition Winners

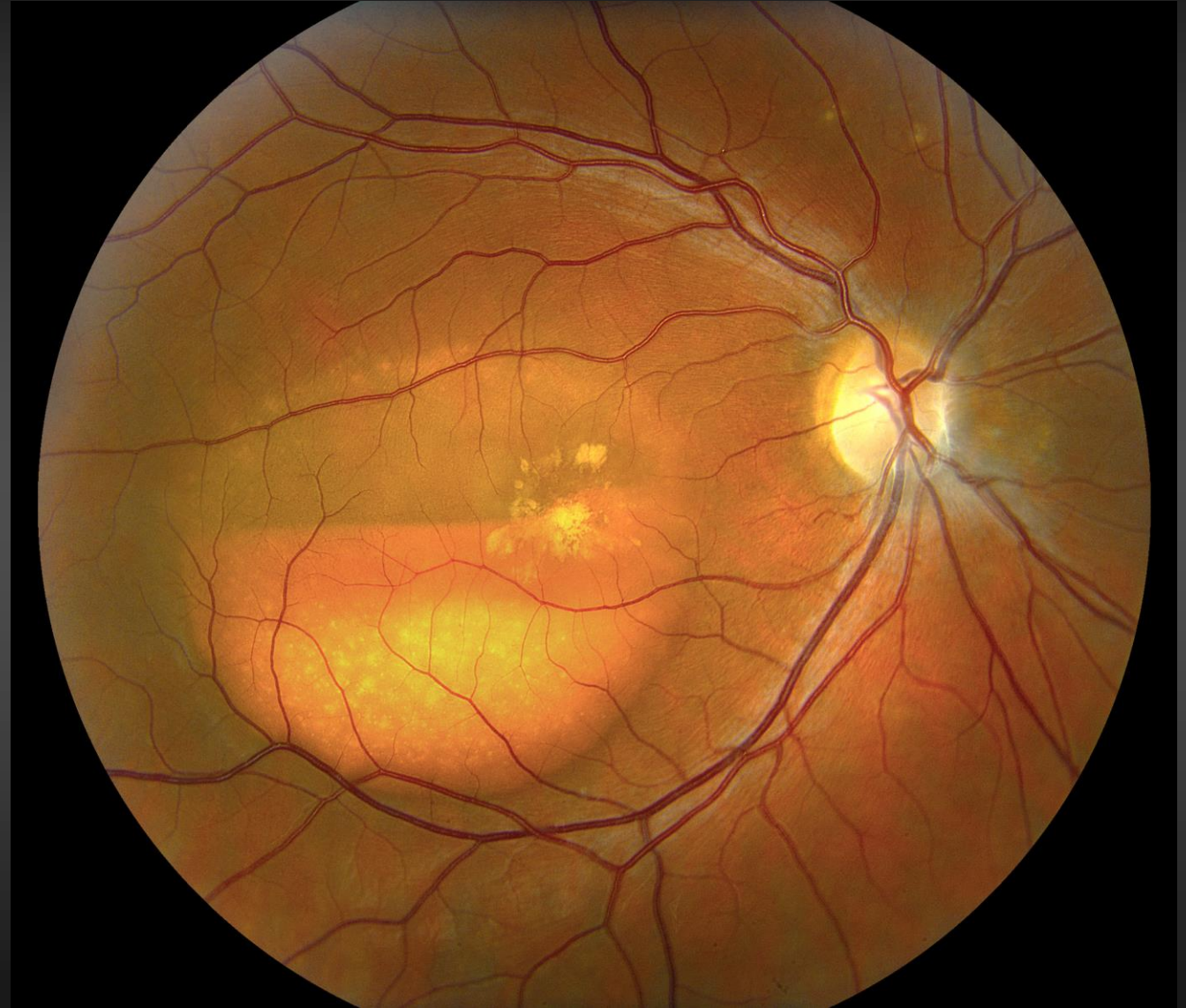
# Fundus Photography - Wide Angle

First Place

Sarah Skiles, CRA

Dr. Han

Pseudohypopyon in Best vitelliform macular dystrophy



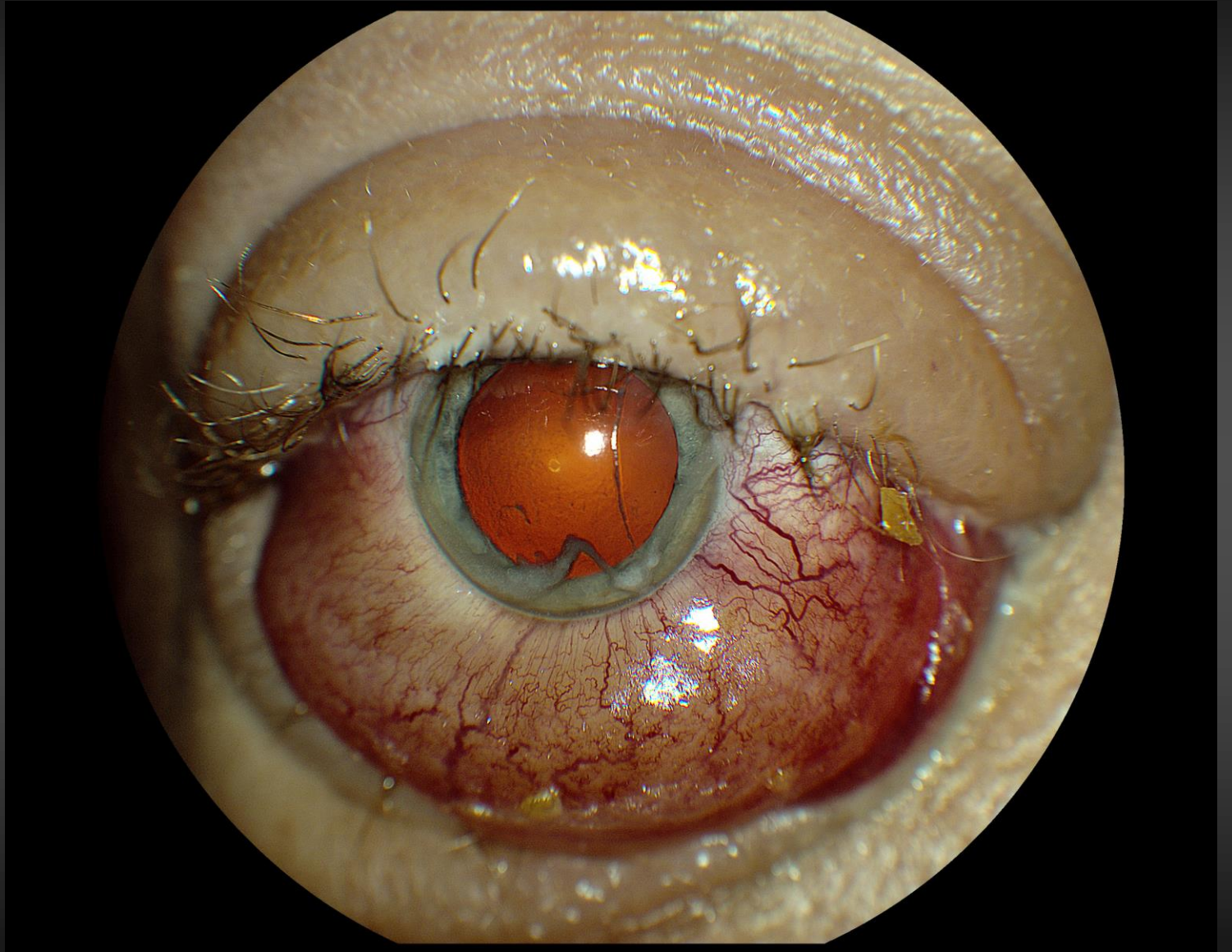
# External Photography

First Place

Sarah Skiles, CRA

Dr. Chung

Chemosis and arterialized conjunctival vessels in a patient with complete ophthalmoplegia



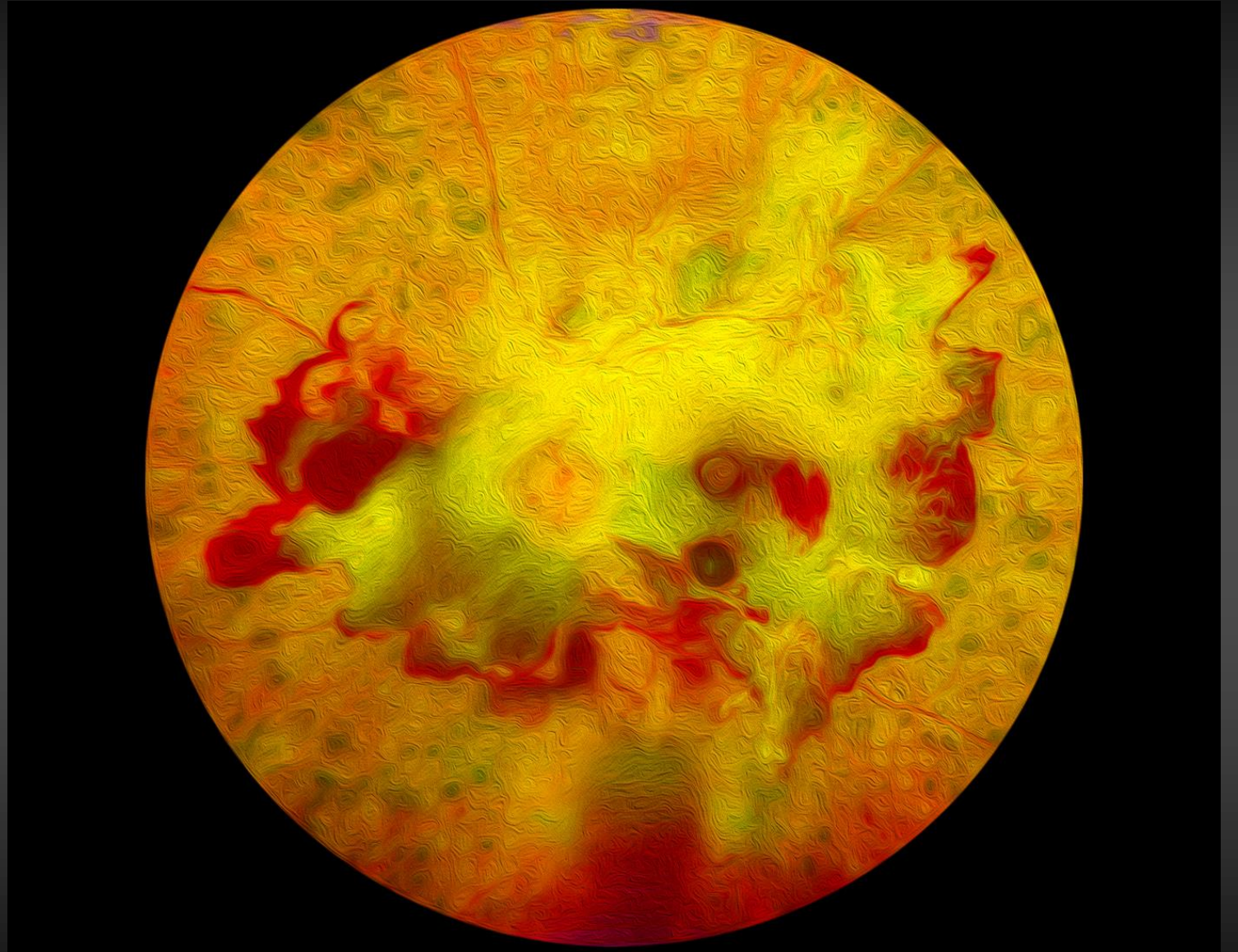
# The Eye as Art

First Place

Jody Troyer, CRA

Dr. Han

Proliferative Diabetic Retinopathy



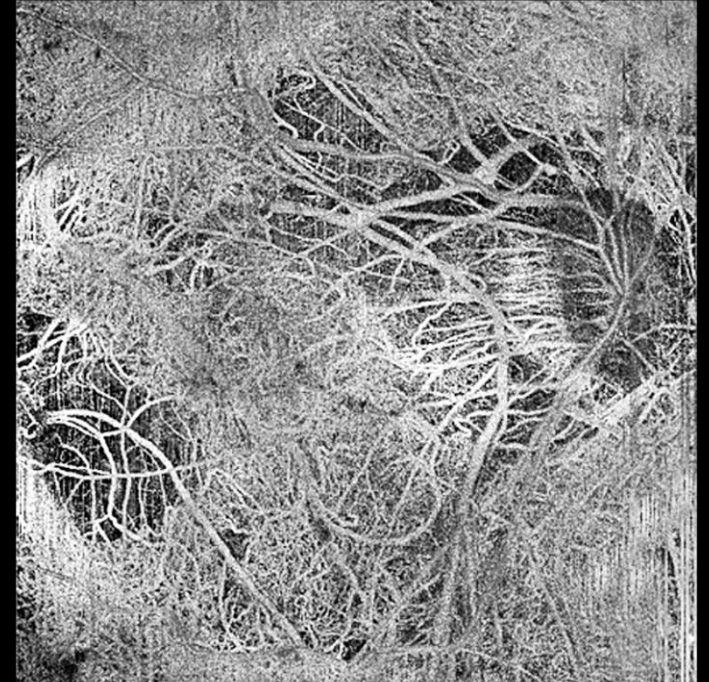
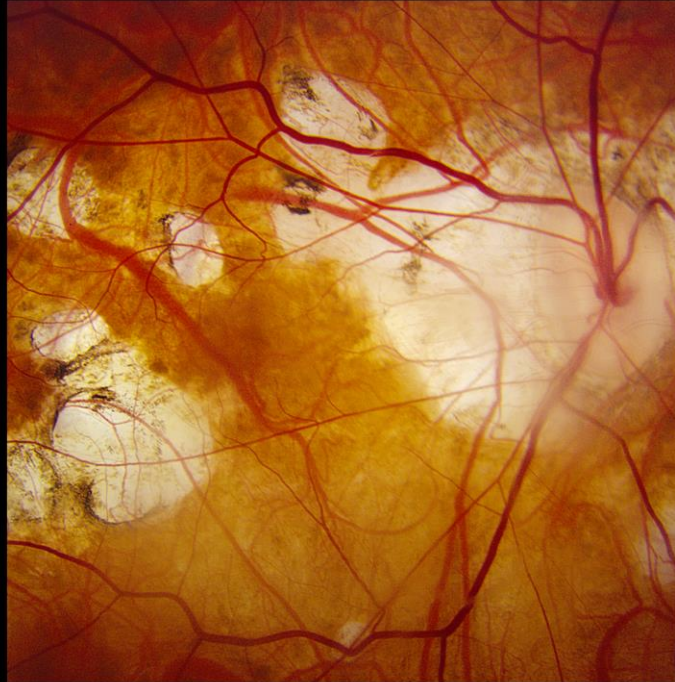
# Optical Coherence Tomography Angiography

First Place

Jody Troyer, CRA

Dr. Kardon

Myopic Degeneration with  
Choroidal Vascular Loss



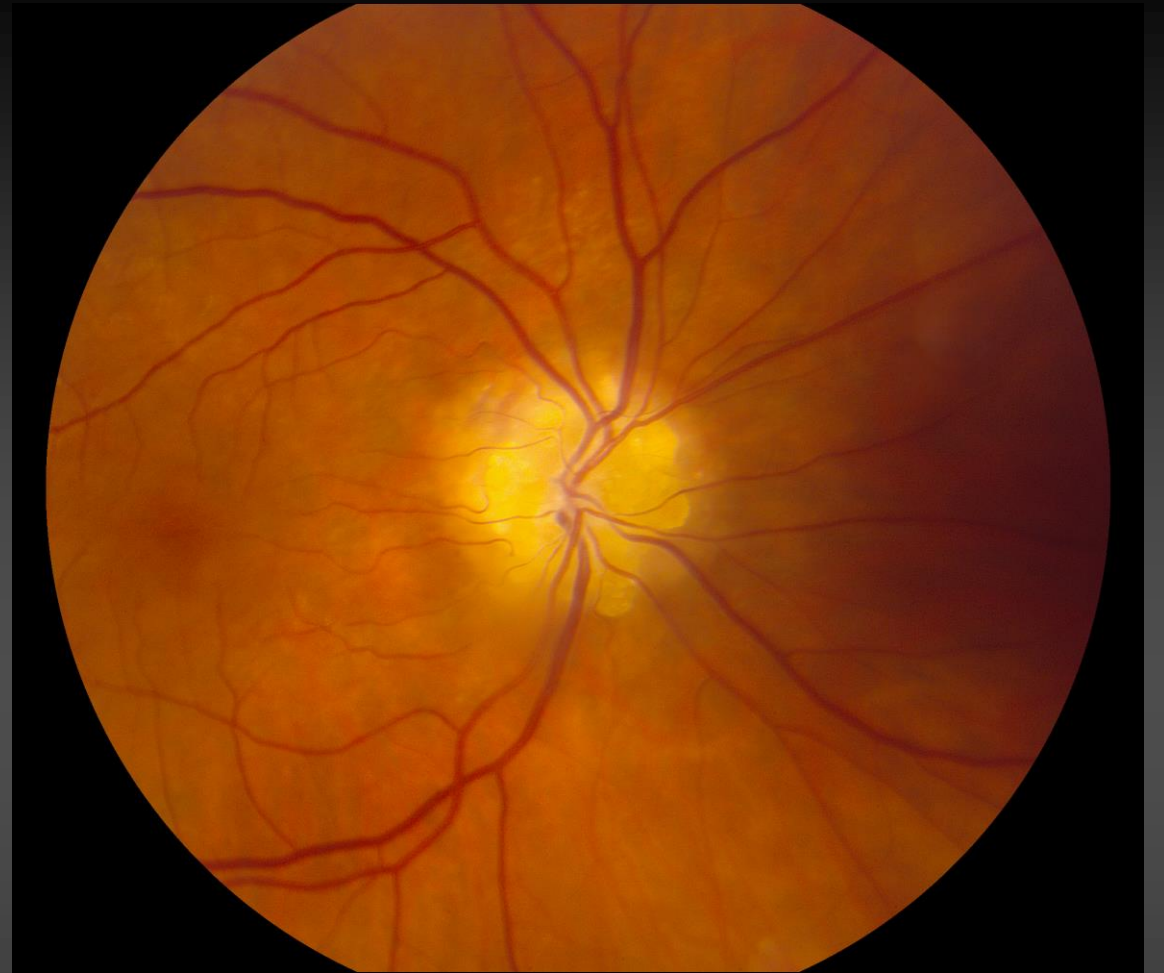
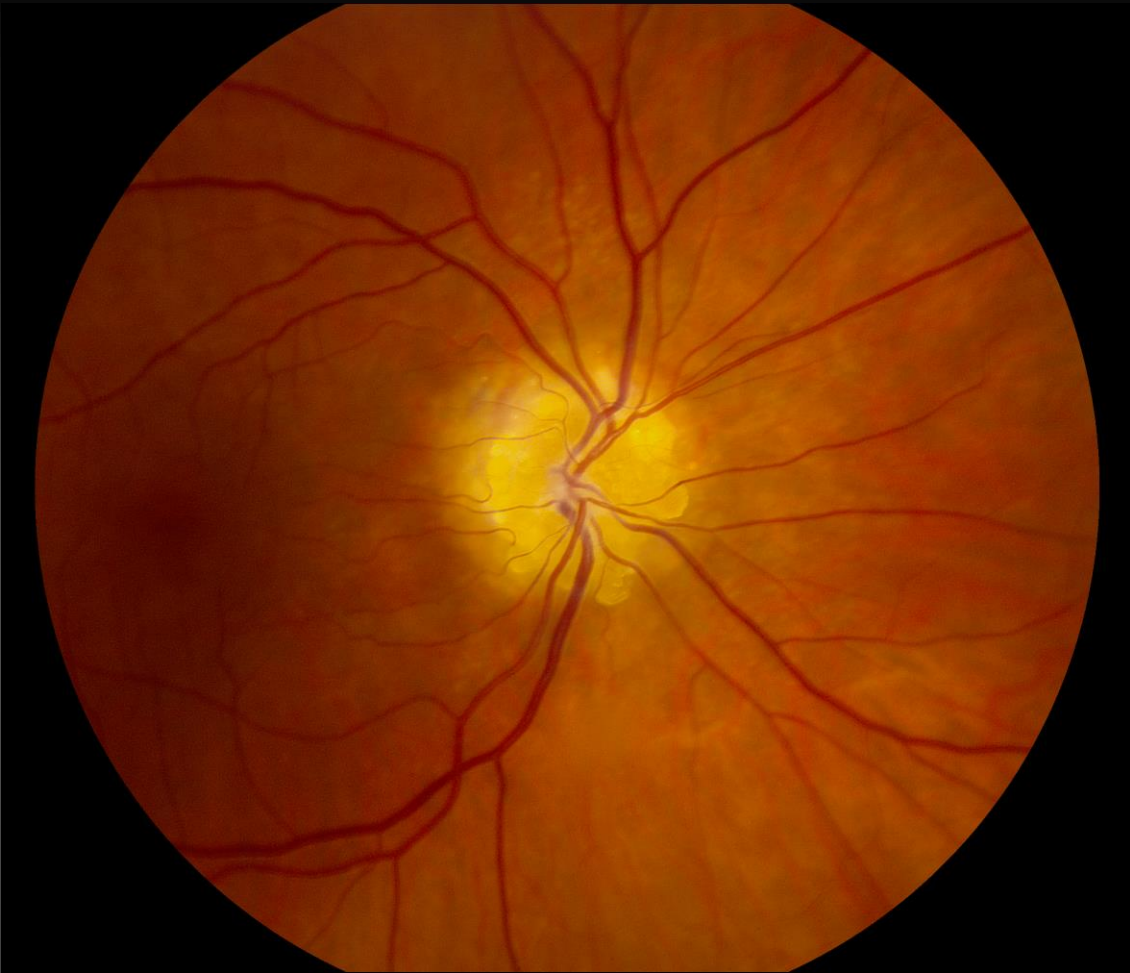
Stereo Instrumentation Photography – First Place

Sarah Skiles, CRA

Dr. Sindt

Unusual Contact Lens

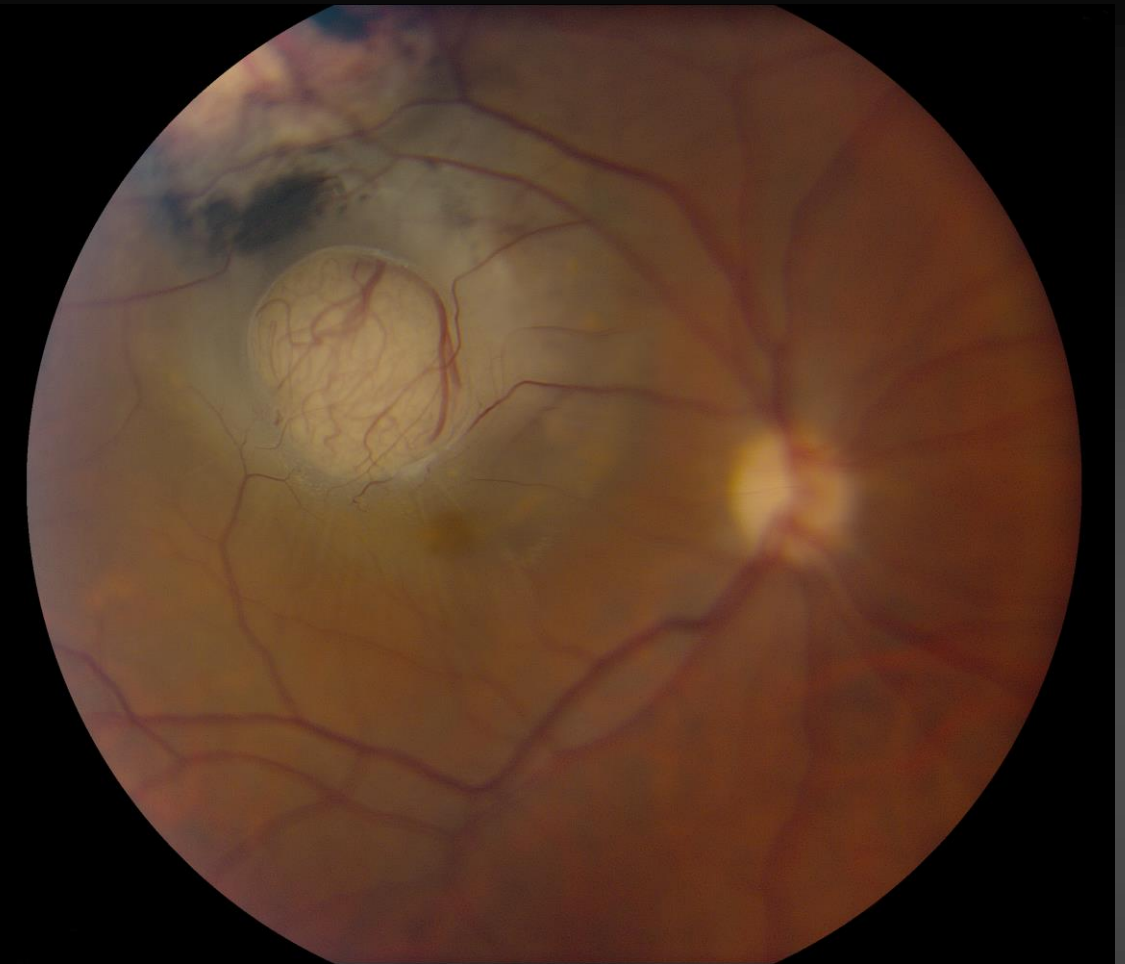
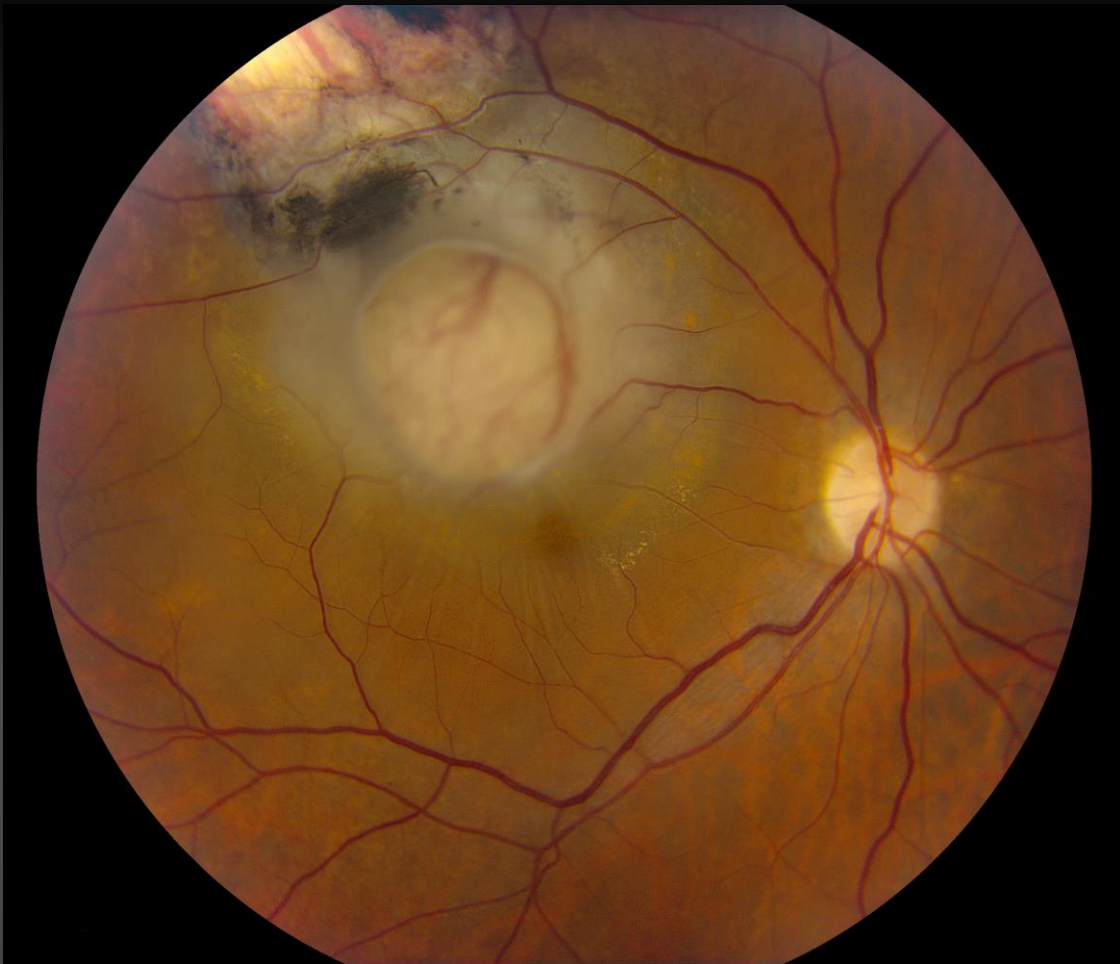
Stereo Fundus Photography Normal - First Place

Nicole Radunzel, CRA

Dr. Kardon

Optic Disc Drusen



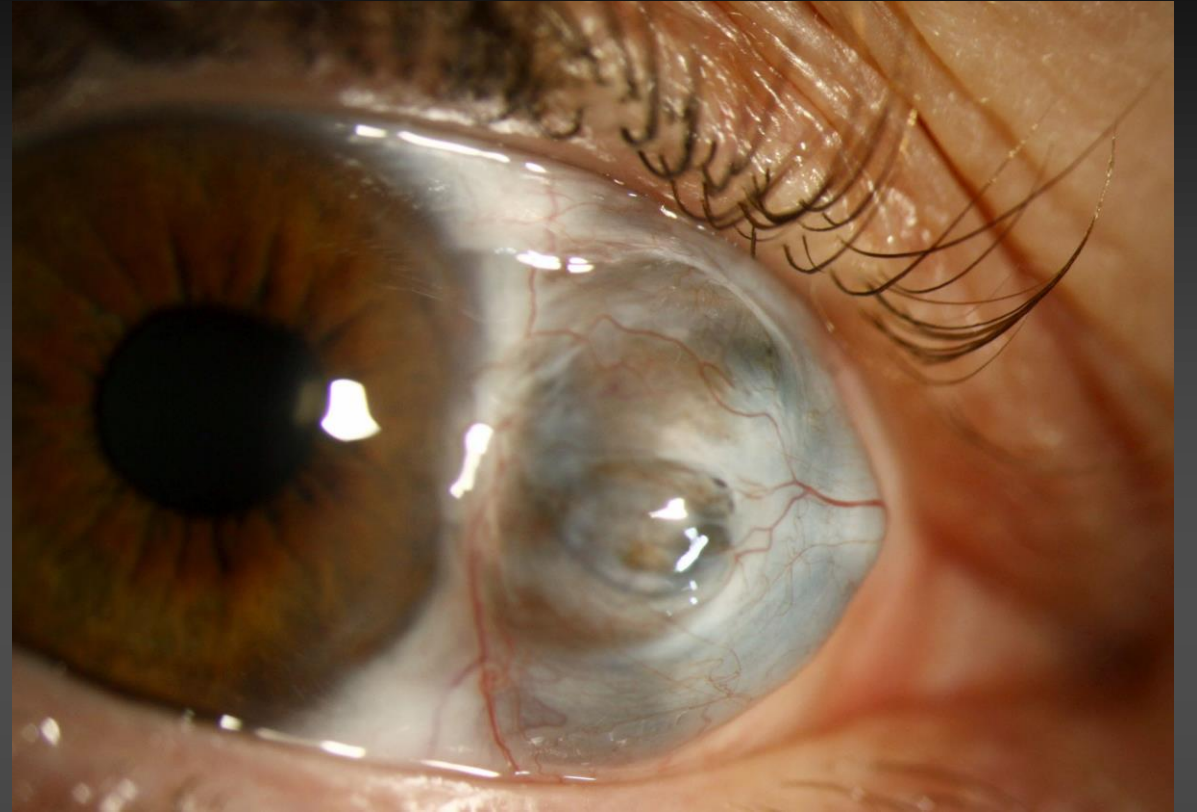
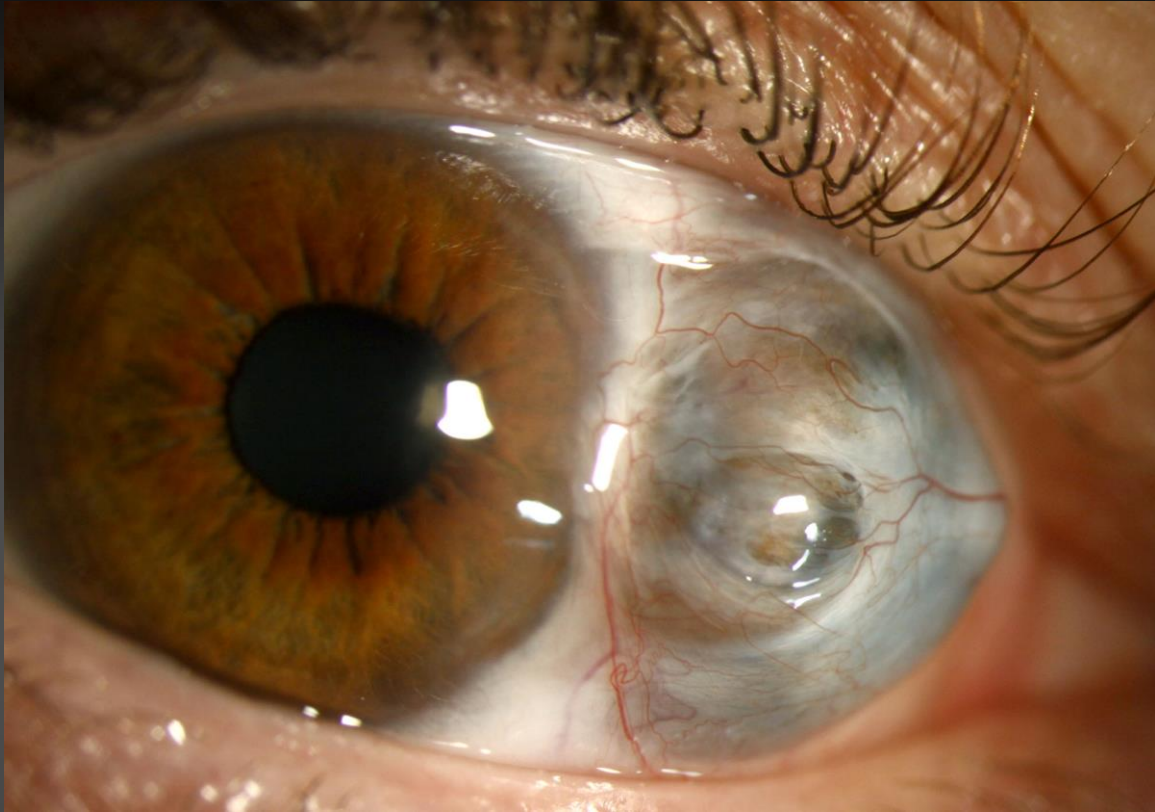
Stereo Fundus Photography Wide Angle - First Place

Nicole Radunzel, CRA

Dr. Boldt

Choroidal Melanoma with a Collar-Button Configuration





Stereo Slit Lamp Photography - First Place

Sarah Skiles, CRA

Dr. Greiner

Scleritis due to Granulomatosis

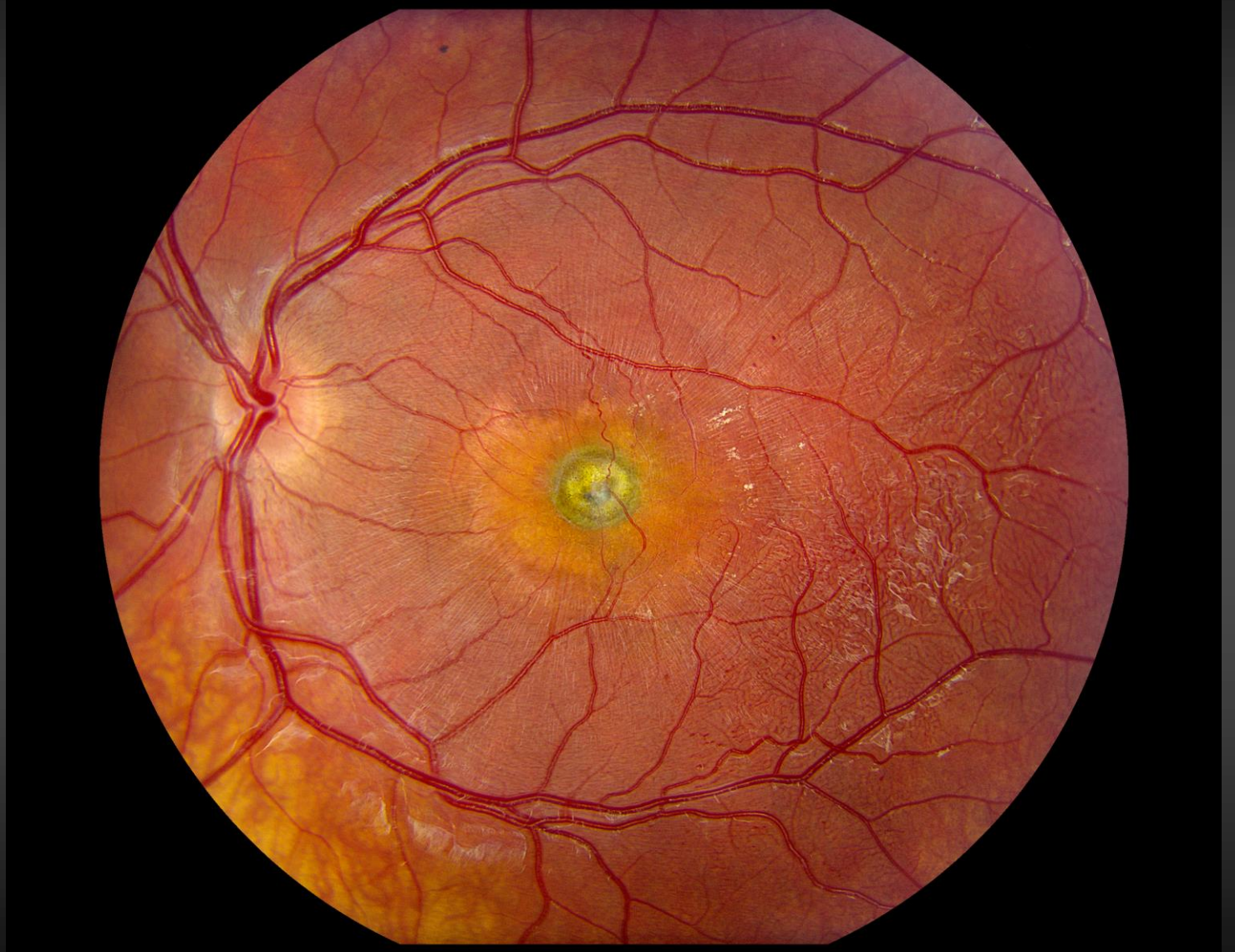
# Fundus Photography - Wide Angle

Second Place

Jody Troyer, CRA

Dr. Sohn

Choroidal Neovascular Membrane



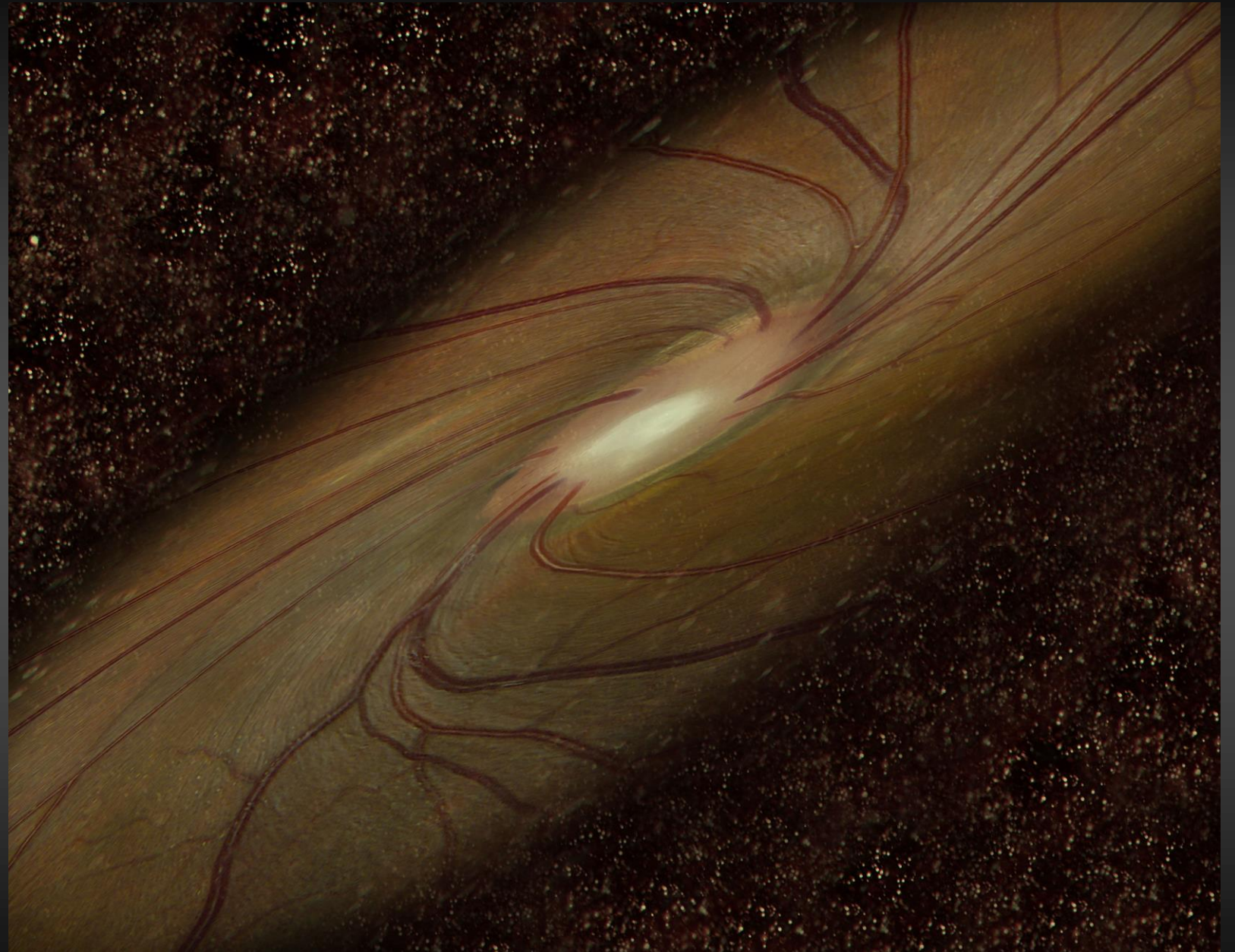
# The Eye as Art

Second Place

Meghan Menzel, CRA

Dr. Sindt

Galax (eye)




# The Eye as Art

Second Place

Nicole Radunzel, CRA

Dr. Haugsdal

Lisa Frank's IOL



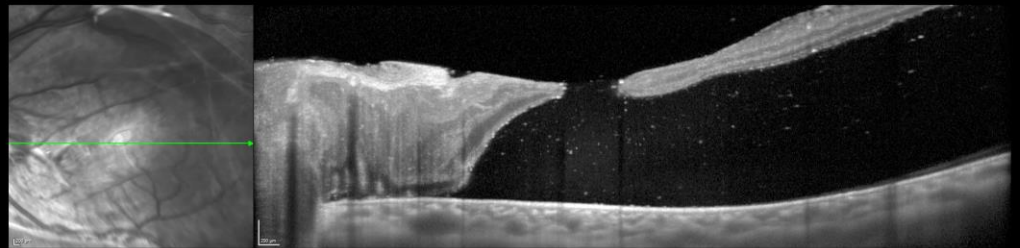
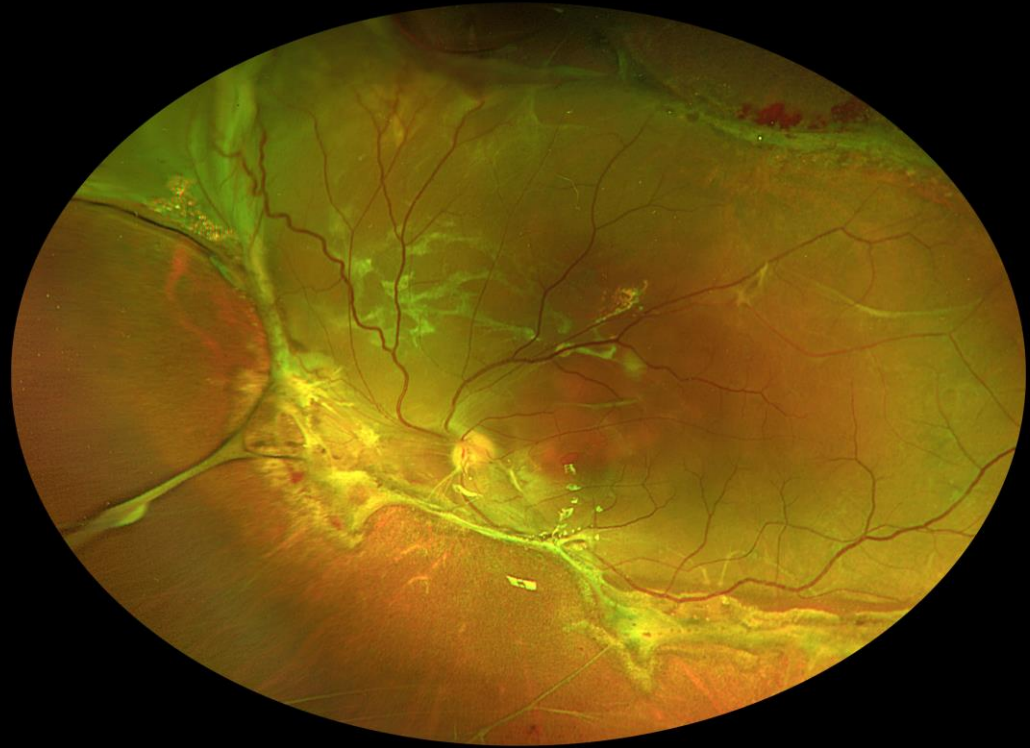
# Cross Categories

Second Place

Sarah Skiles, CRA

Dr. J. Russell

Small hole with recurrent retinal detachment



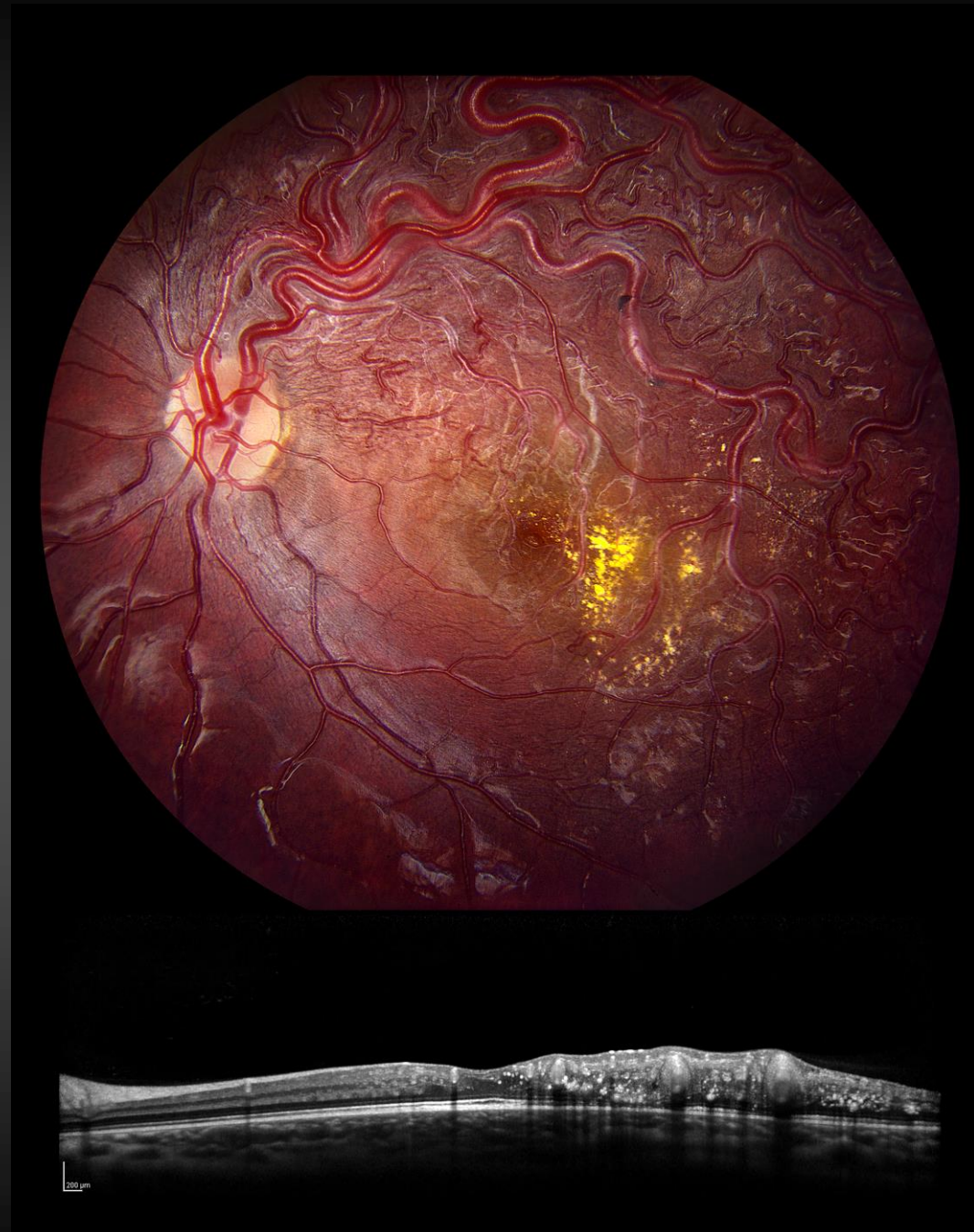
# Cross Categories

Second Place

Meghan Menzel, CRA

Dr. Dumitrescu

Wyburn Mason Syndrome





Stereo Gonioscopic Photography – Second Place

Jody Troyer, CRA

Dr. Sears

Melanoma Involving the Angle

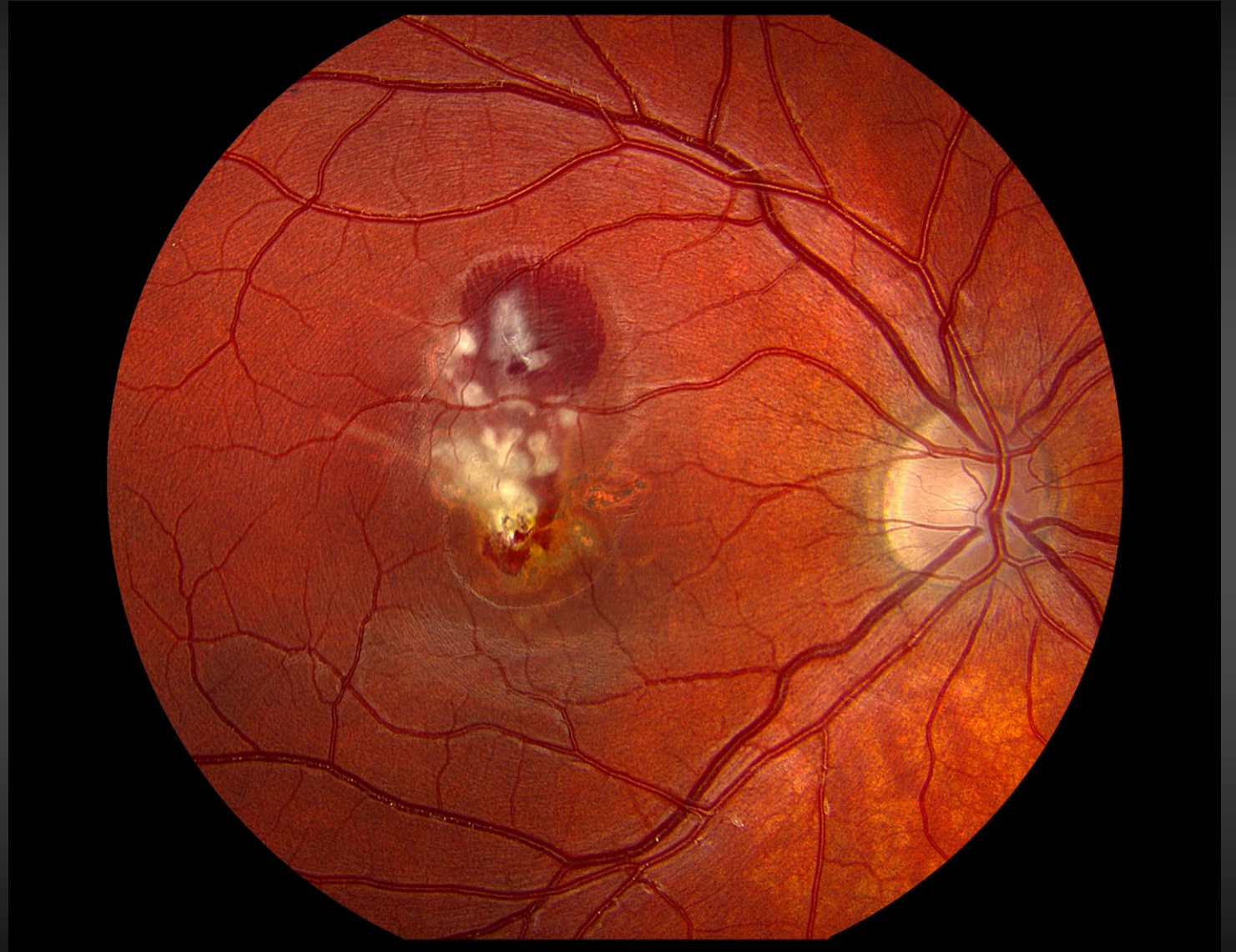
# Fundus Photography - Normal 30° - 40°

Third Place

Meghan Menzel, CRA

Dr. Boldt

Laser maculopathy with Henle  
fiber layer hemorrhage





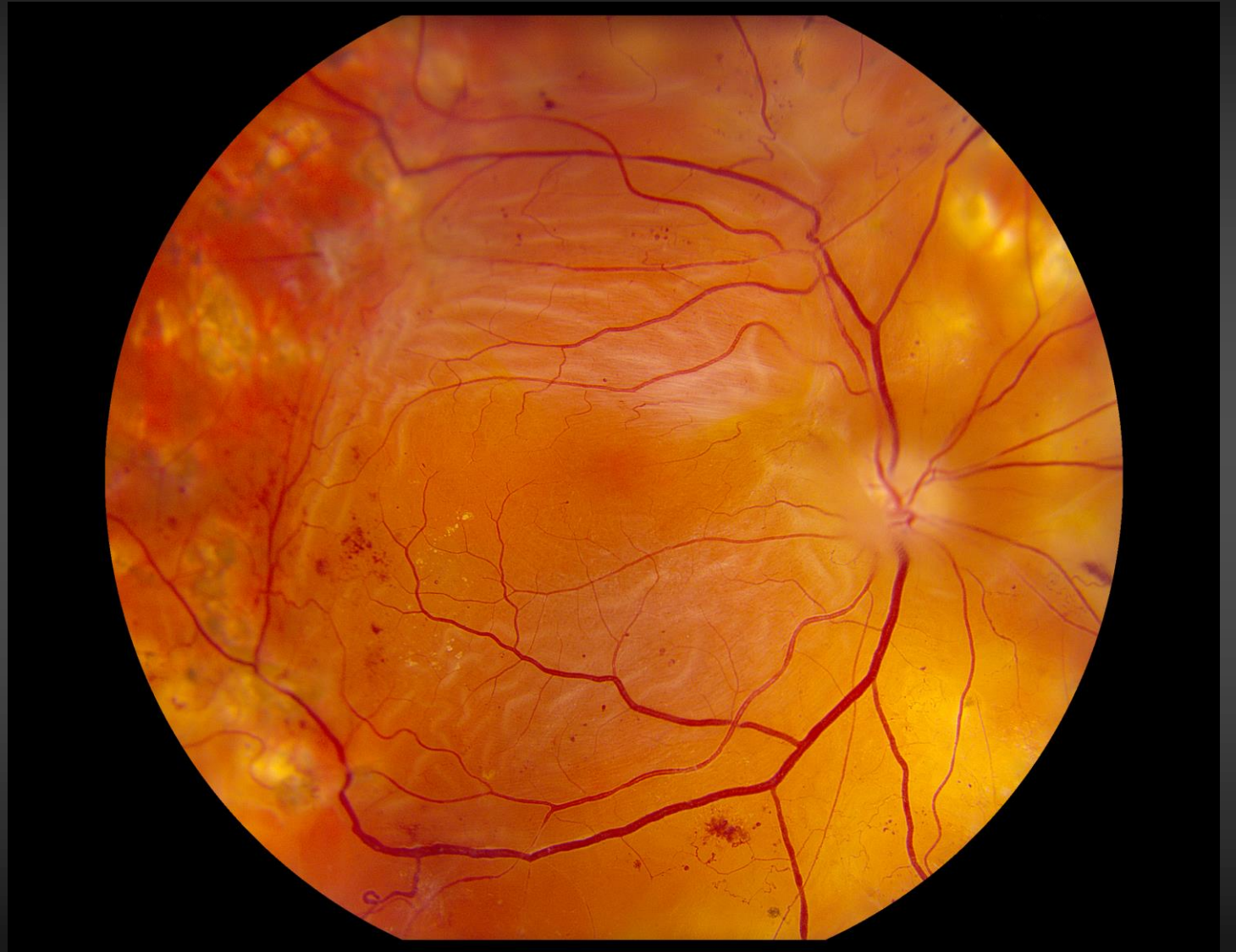# Fundus Photography - Wide Angle

Third Place

Jody Troyer, CRA

Dr. Sohn

Retinal detachment in proliferative  
diabetic retinopathy



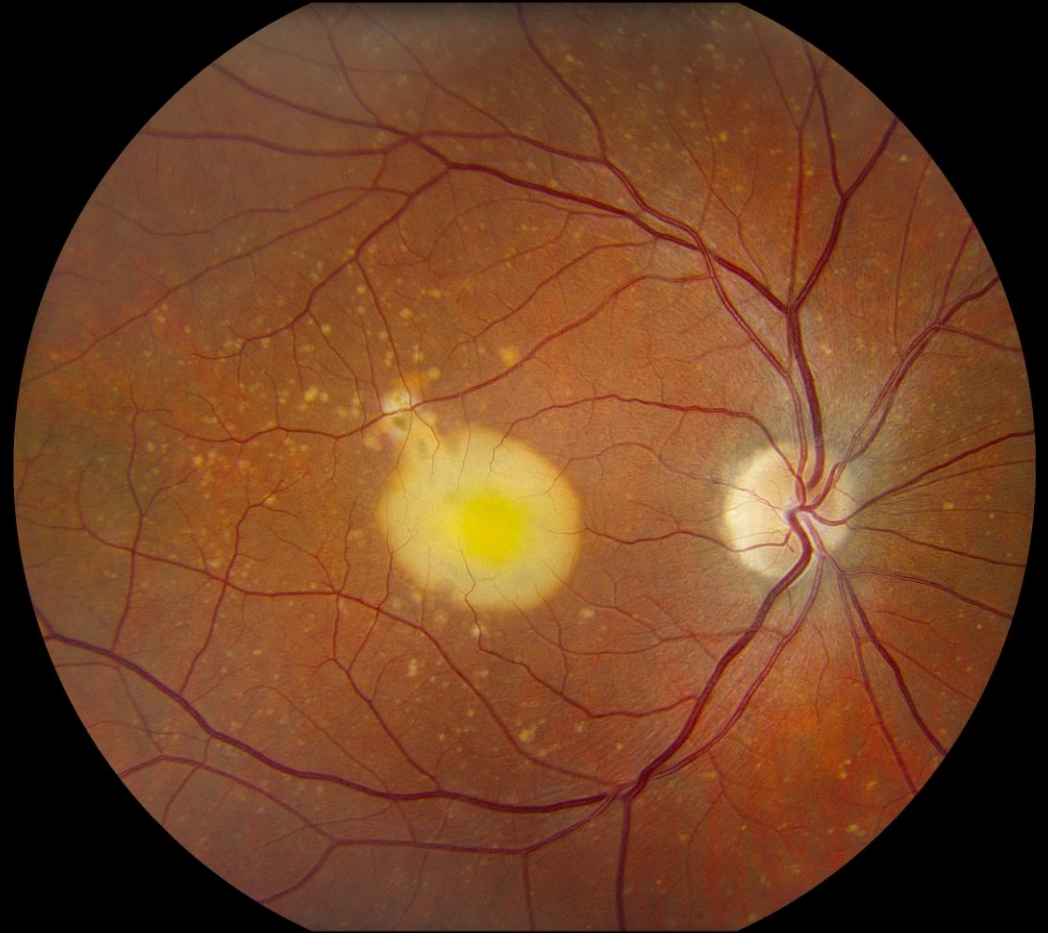
# Fundus Photography - Wide Angle

Third Place

Sarah Skiles, CRA

Dr. Han

Egg yolk in the retina: Adult Onset Vitelliform Dystrophy



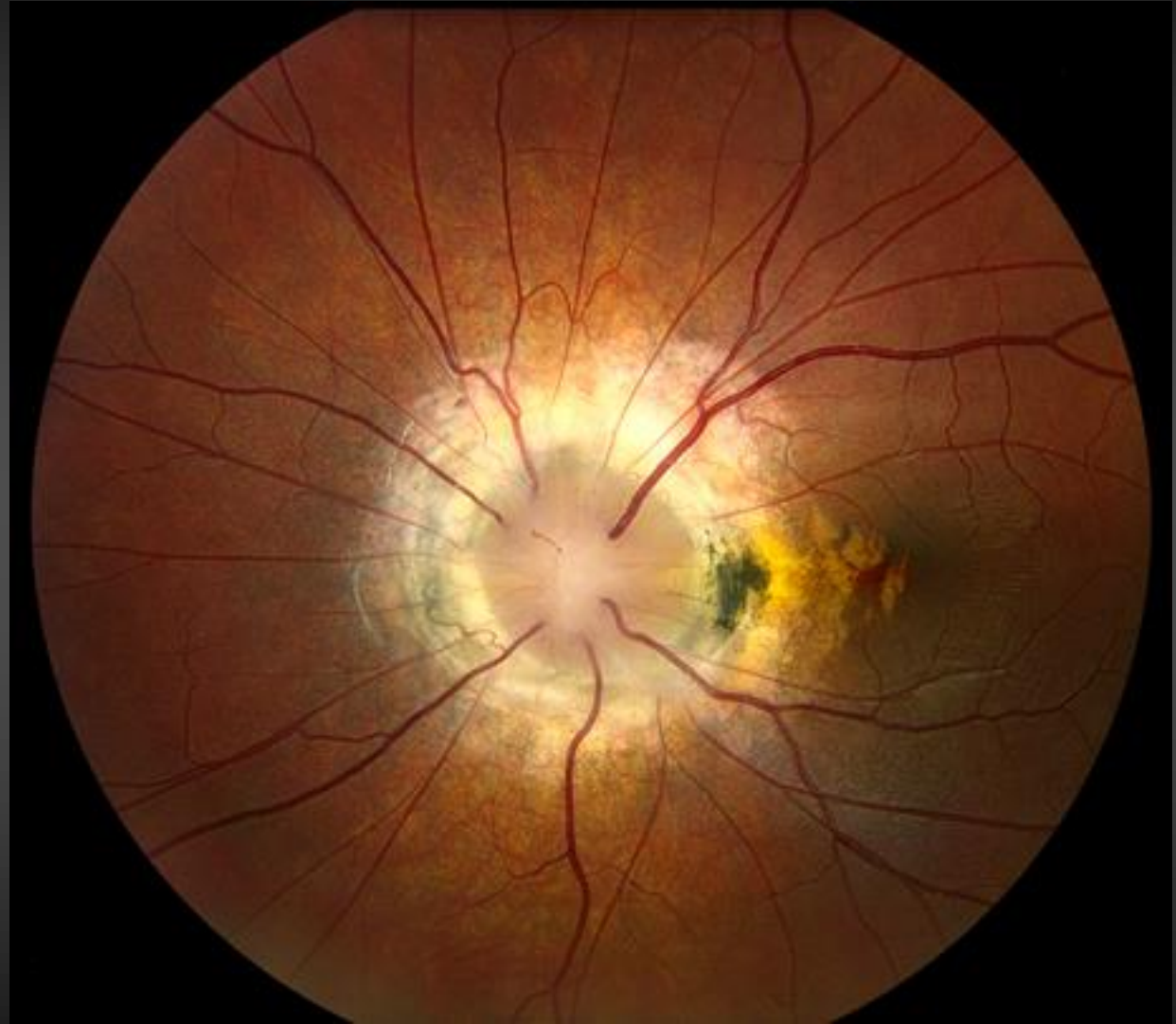
# Fundus Photography - Normal 30° - 40°

*Third Place*

Sarah Skiles, CRA

Dr. J. Russell

Congenital Anomaly of the Optic Nerve



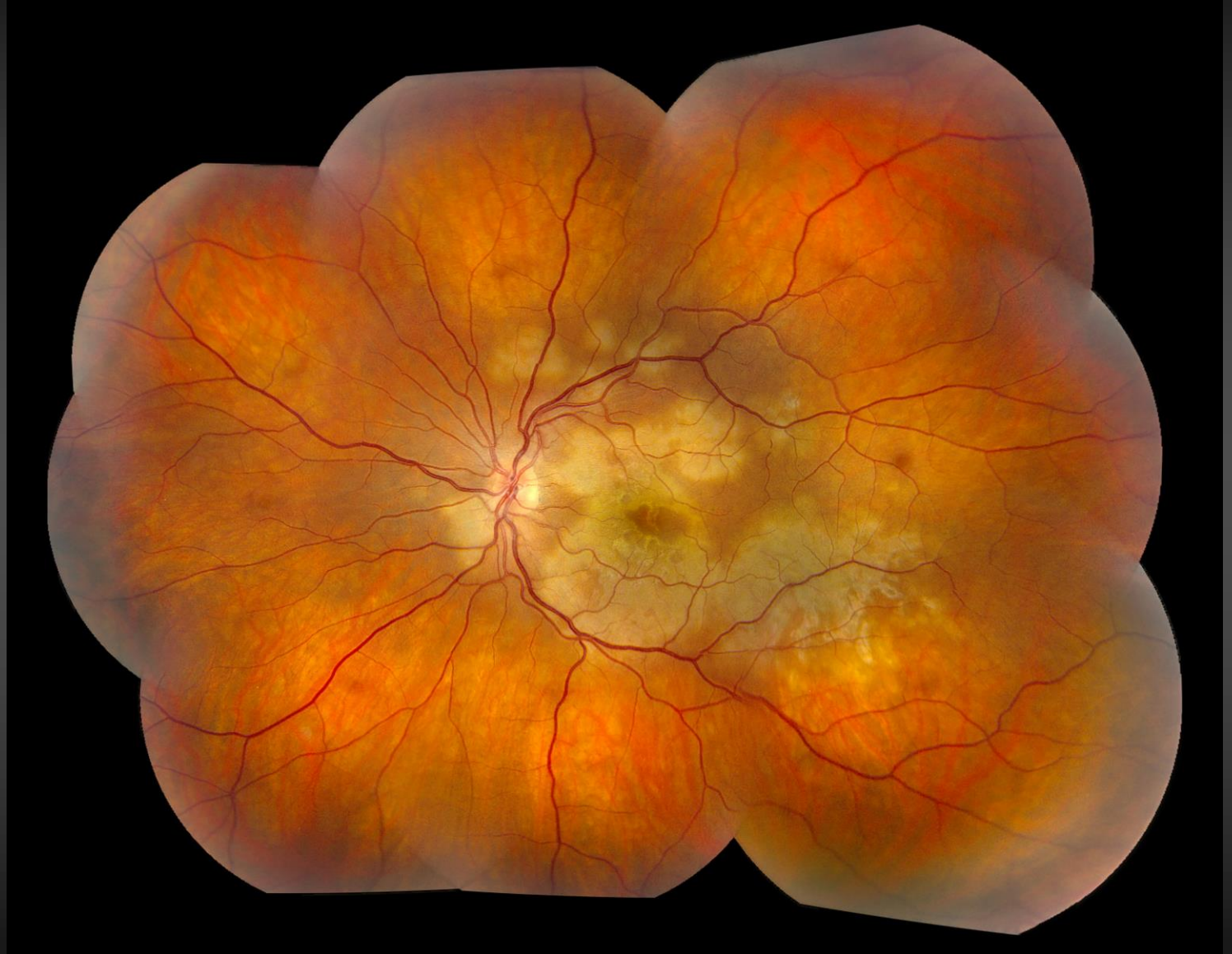# Composite Image

Third Place

Jody Troyer, CRA

Dr. Folk

APMPEE

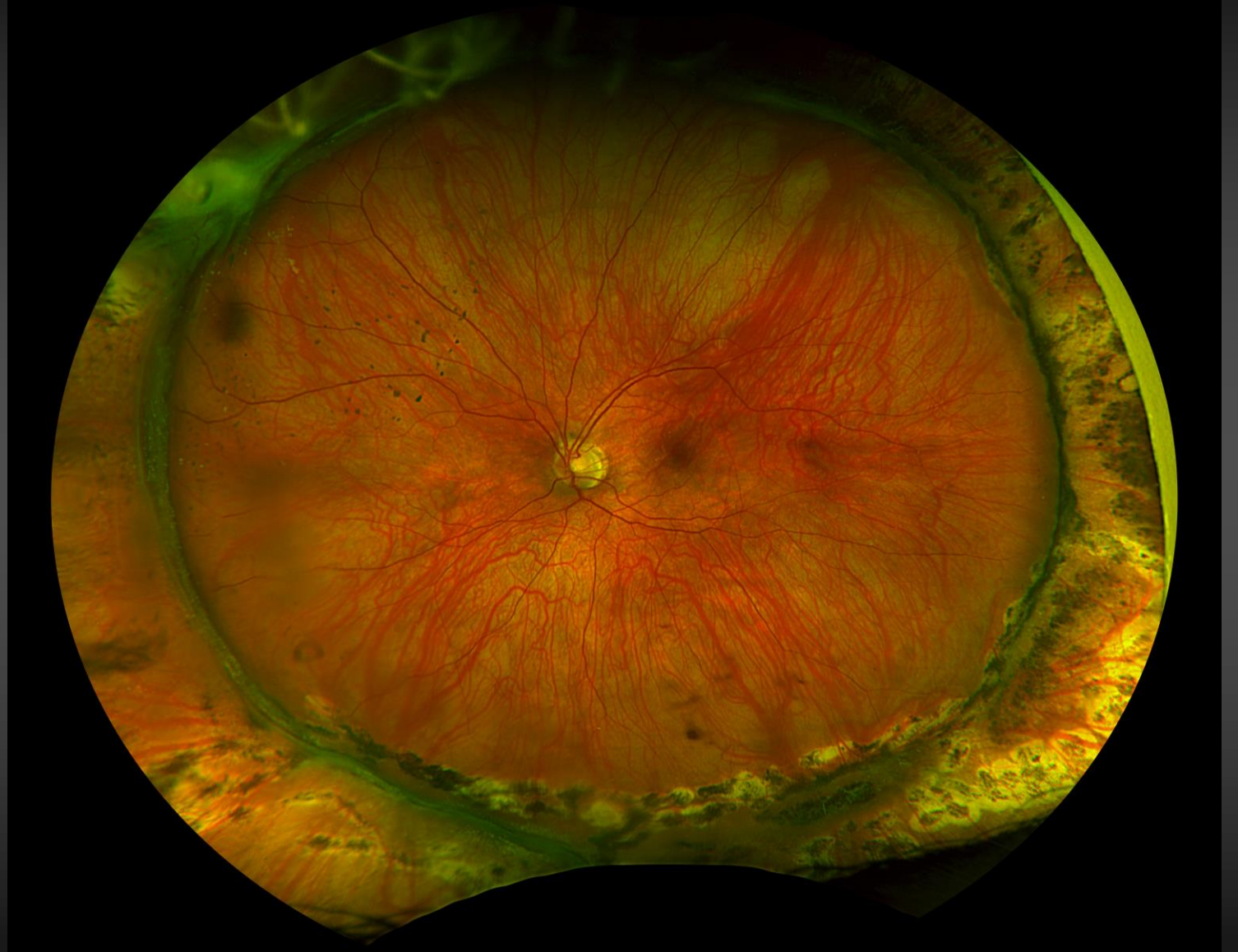

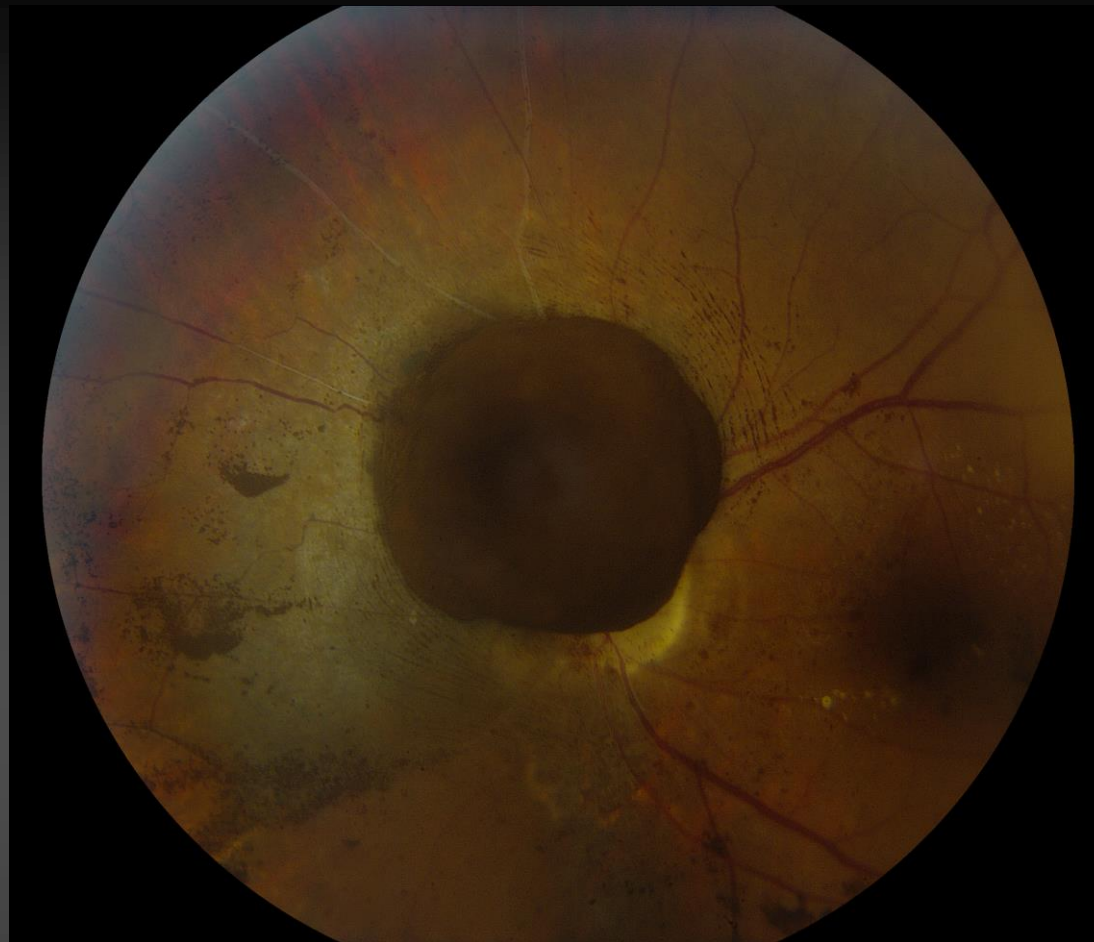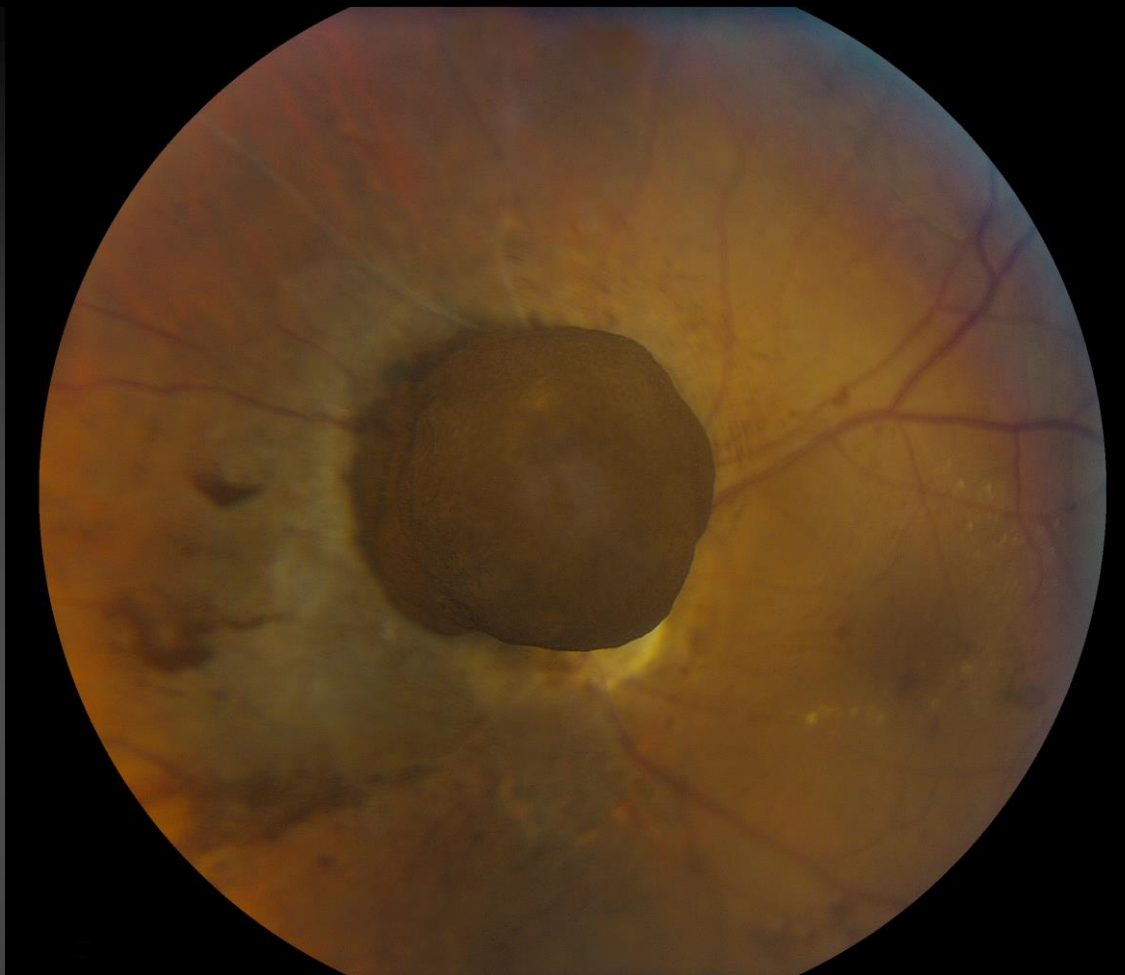
# Ultra-widefield Imaging

Third Place

Alexandra Copple

Dr. J. Russell  
Scleral Buckle



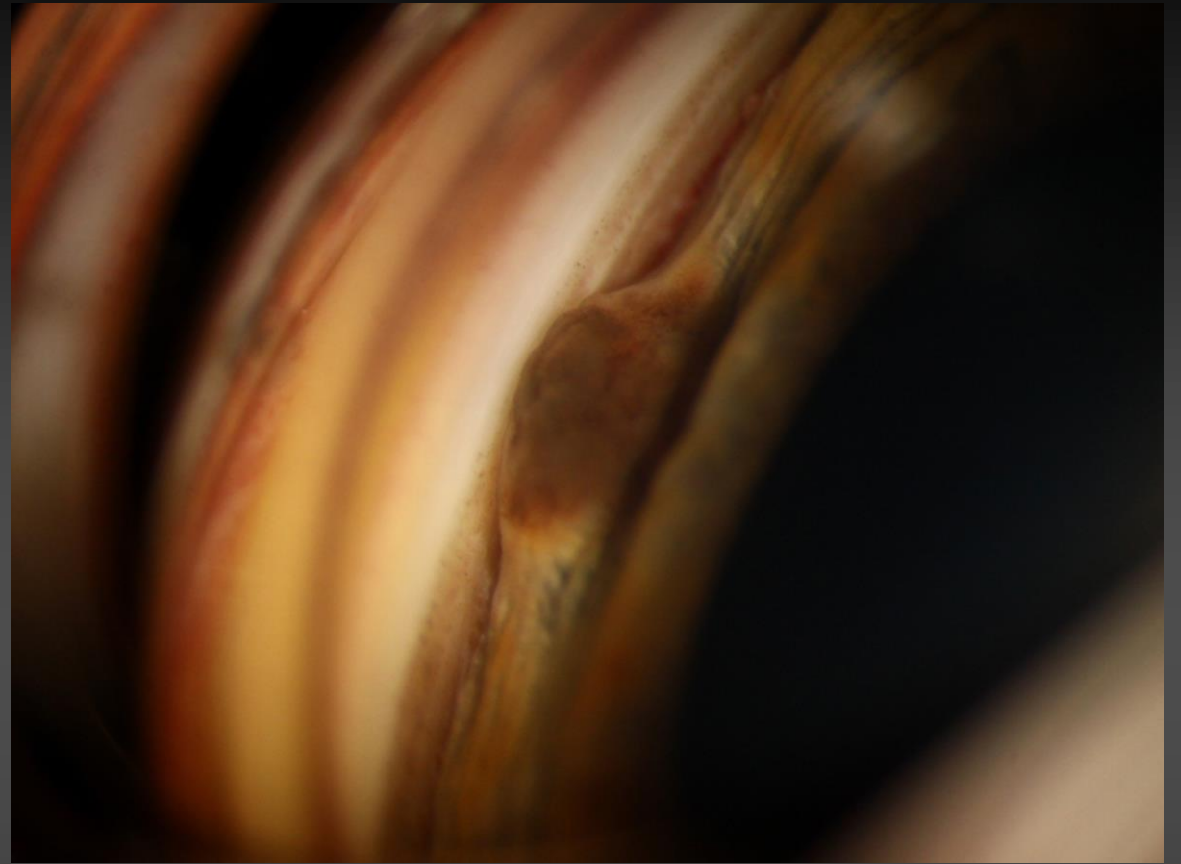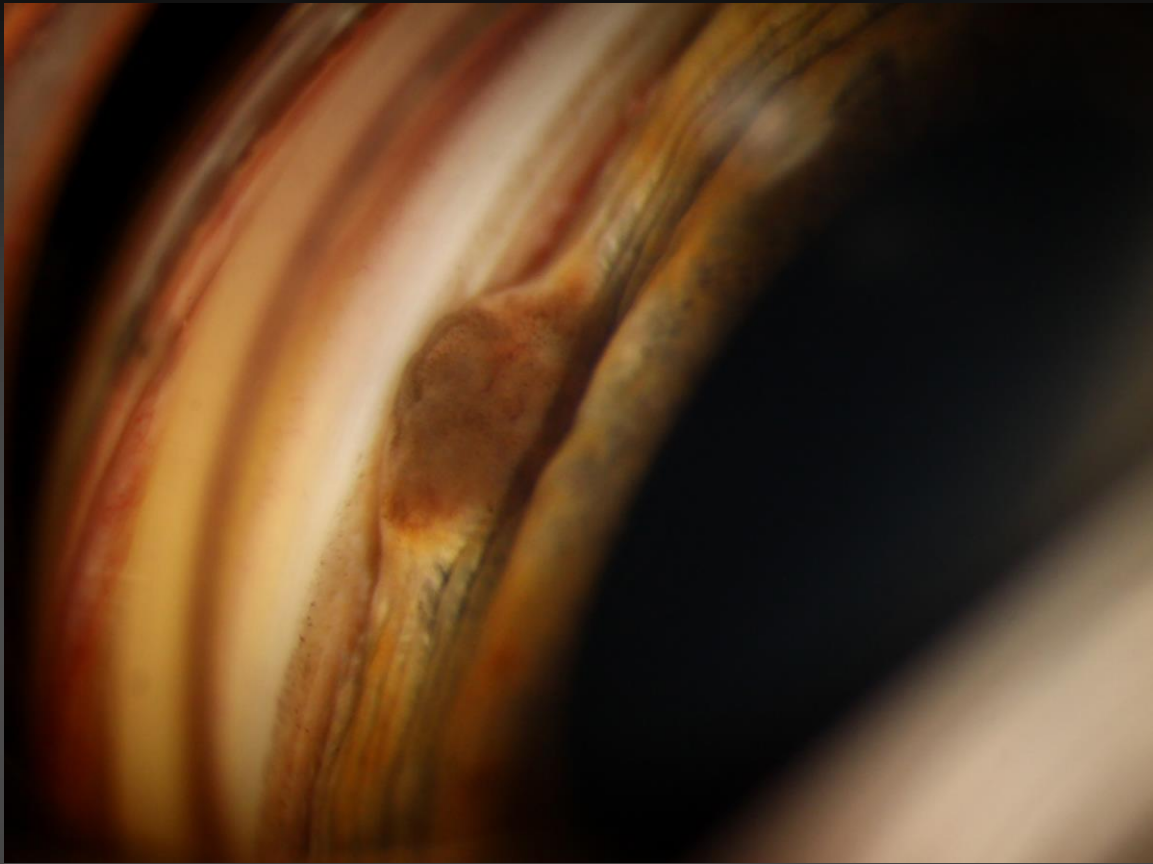


Stereo Fundus Photography Wide Angle – Third Place

Nicole Radunzel, CRA

Dr. Binkley

Juxtapapillary choroidal melanoma with vitreous invasion



## Stereo Gonioscopic Photography – Third Place

Jody Troyer, CRA

Dr. Sears

Iris lesion in the angle

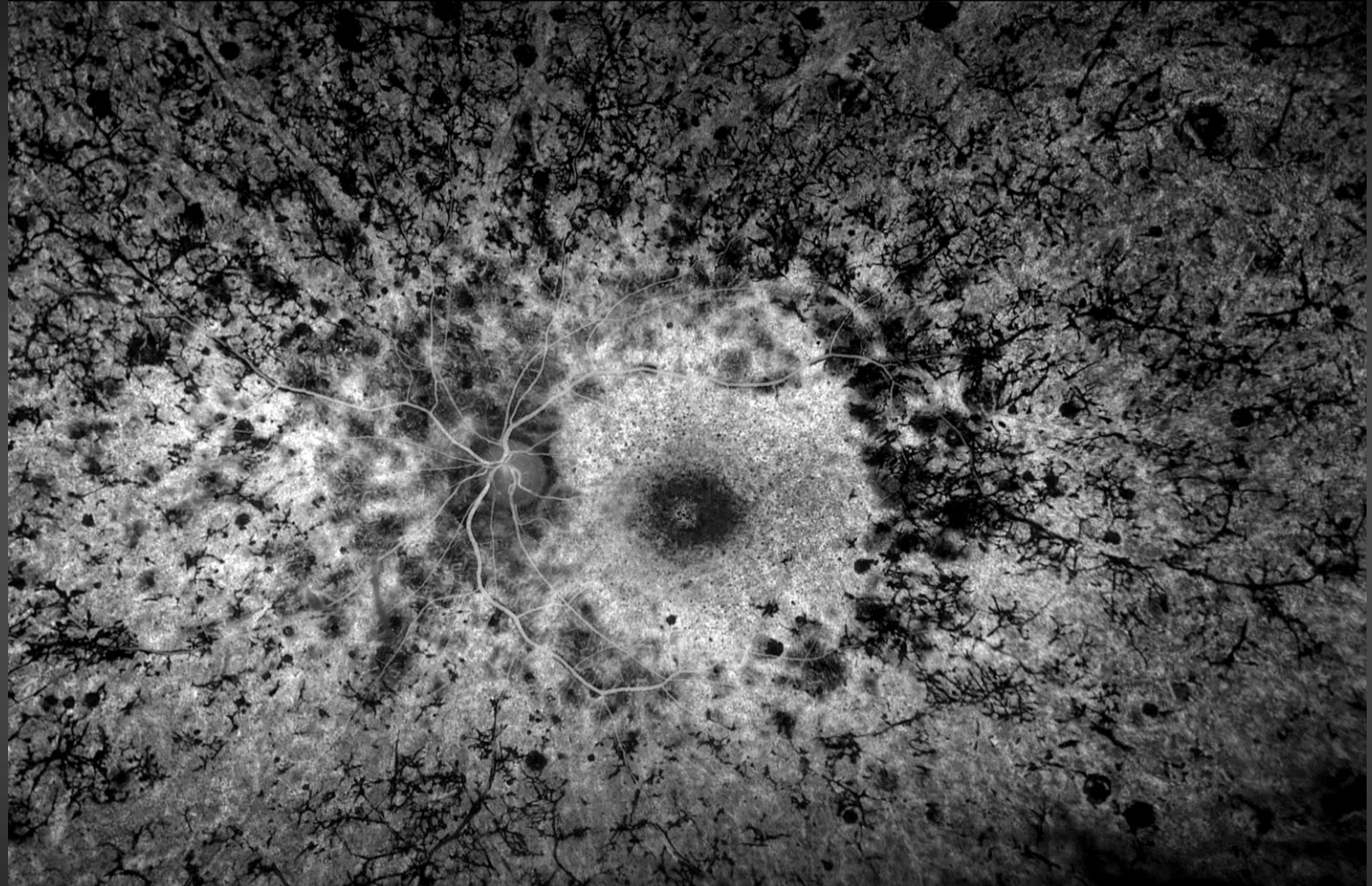
# Fluorescein Angiography

## Honorable Mention

Jody Troyer, CRA

Dr. J. Russell

Bone spicule-like pigmentation  
blocking fluorescence





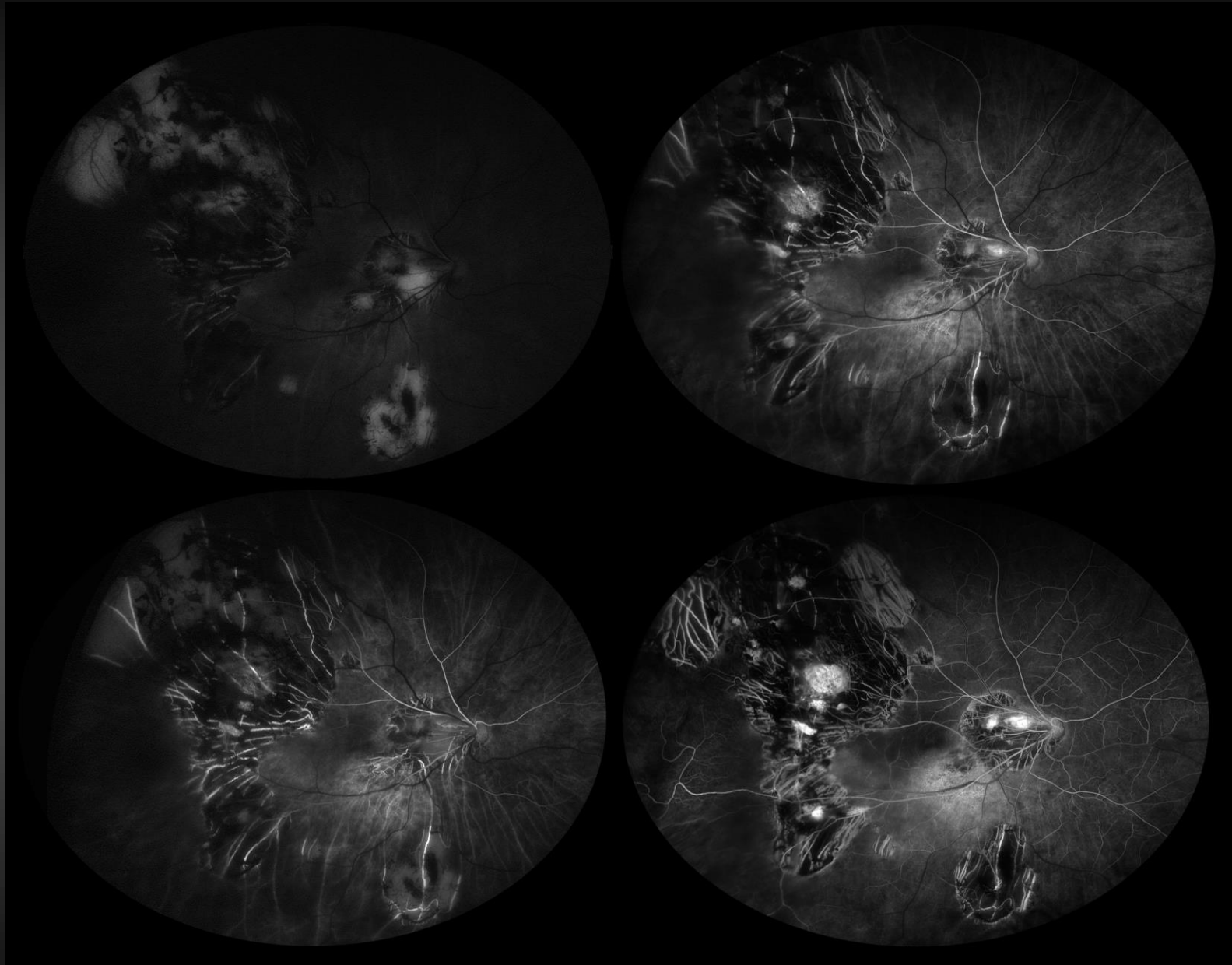
# Fluorescein Angiography

## Honorable Mention

Nicole Radunzel, CRA

Dr. Binkley

Chorioretinal scarring in laser-treated  
von Hippel Lindau syndrome



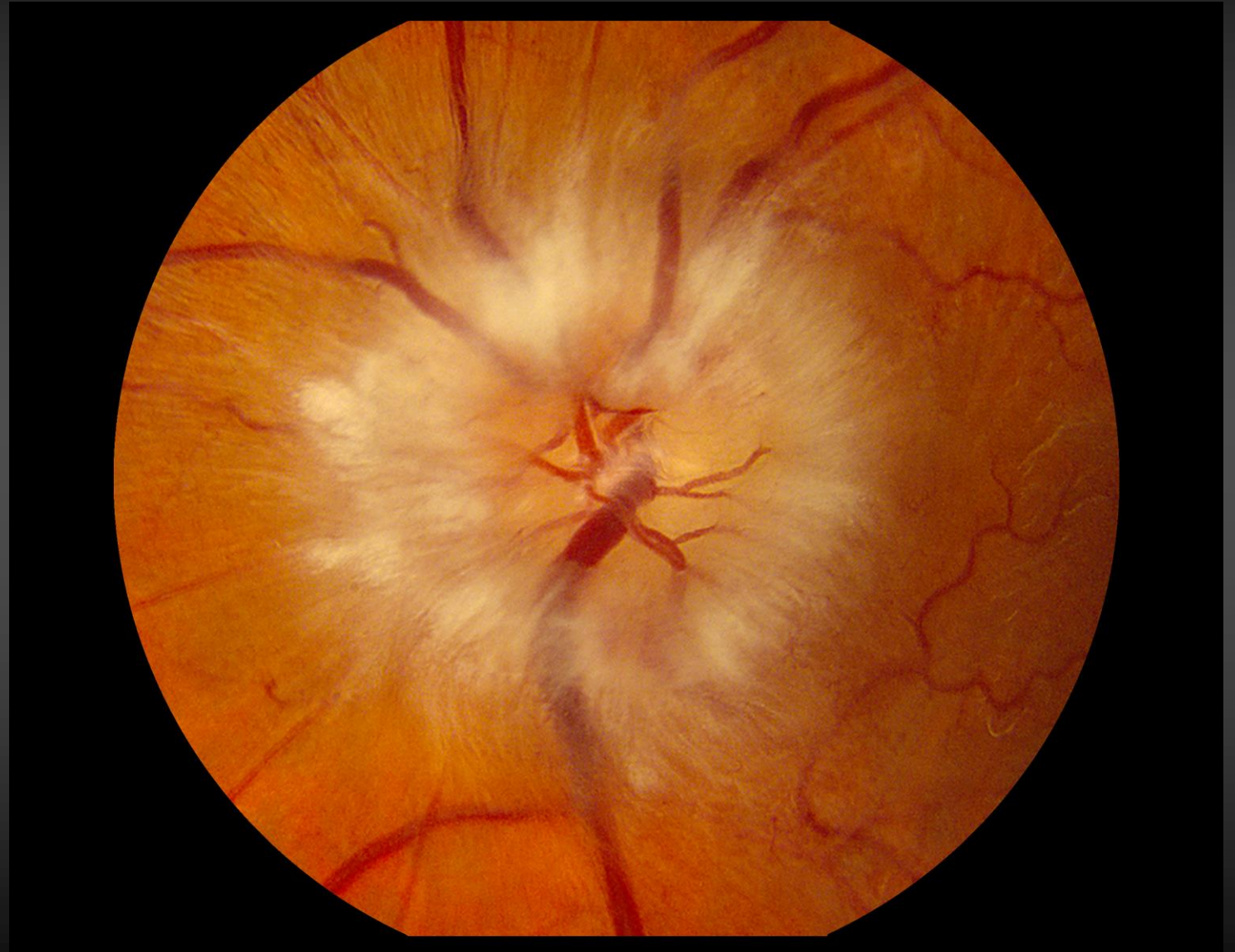
# Fundus Photography - High Magnification

Honorable Mention

Meghan Menzel, CRA

Dr. Chung

Disc Edema



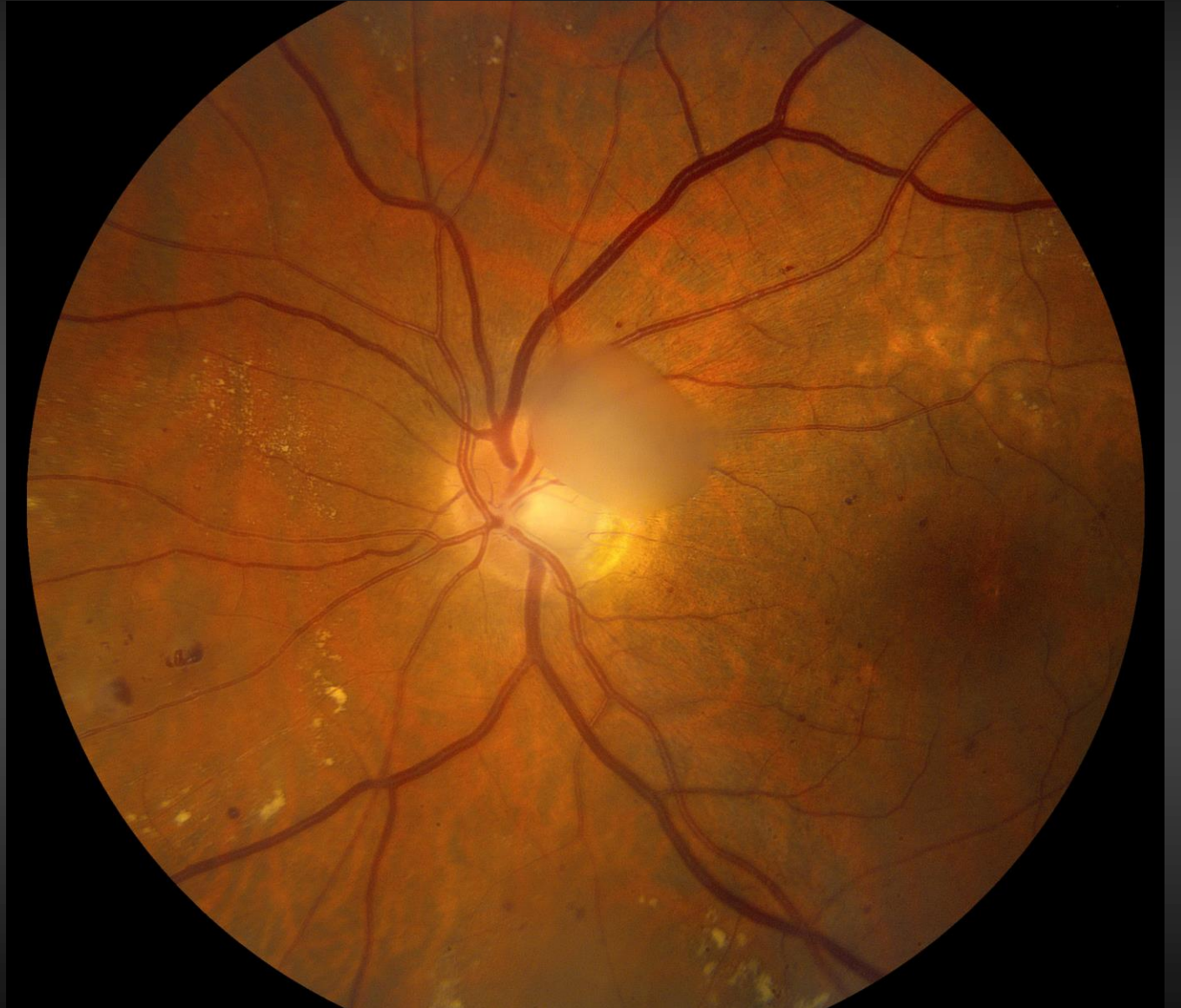# Fundus Photography - Normal 30° - 40°

Honorable Mention

Sarah Skiles, CRA

Dr. Binkley

Juxtapapillary Astrocytic Hamartoma



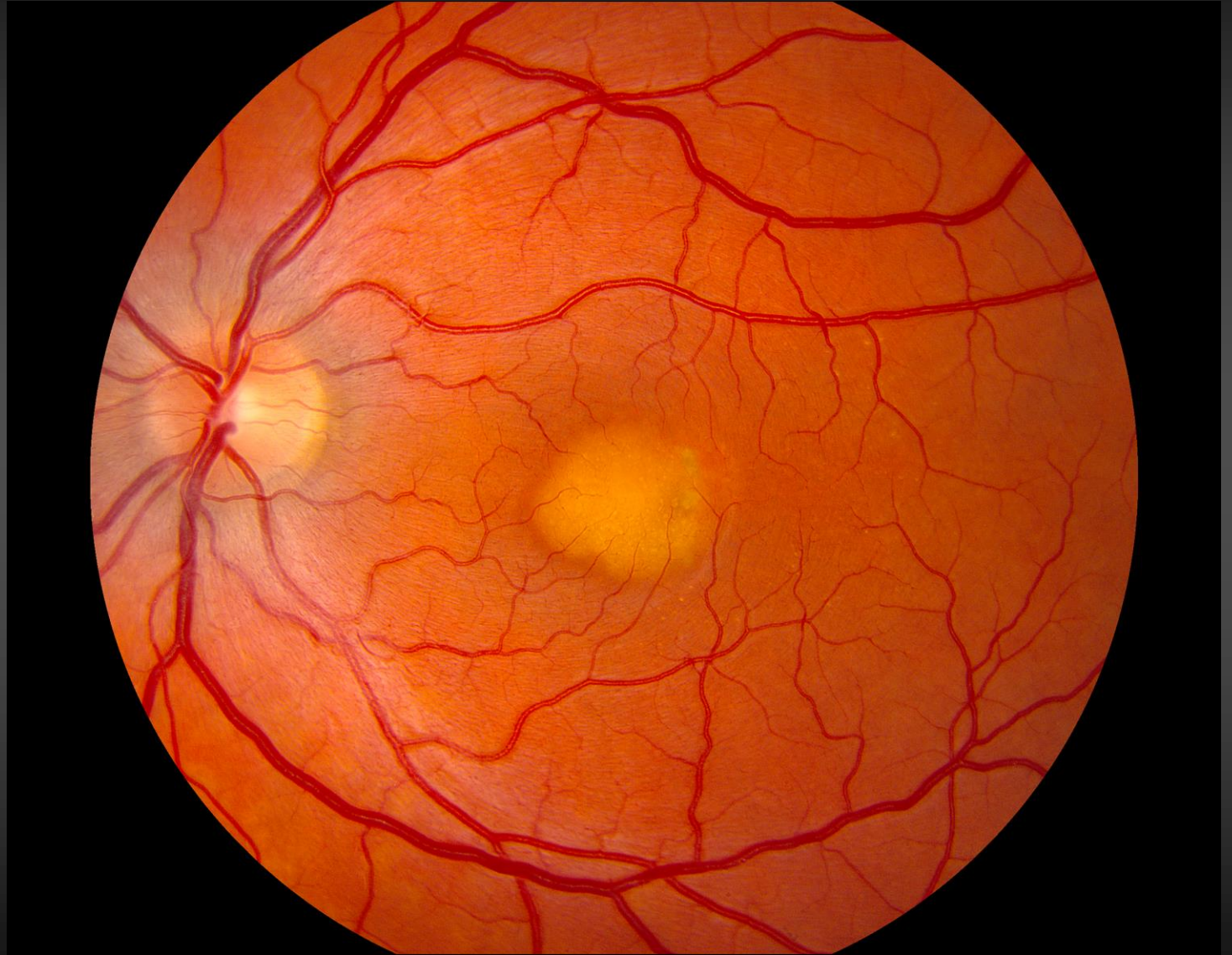
# Fundus Photography - Normal 30° - 40°

Honorable Mention

Meghan Menzel, CRA

Dr. Sohn

Best Disease



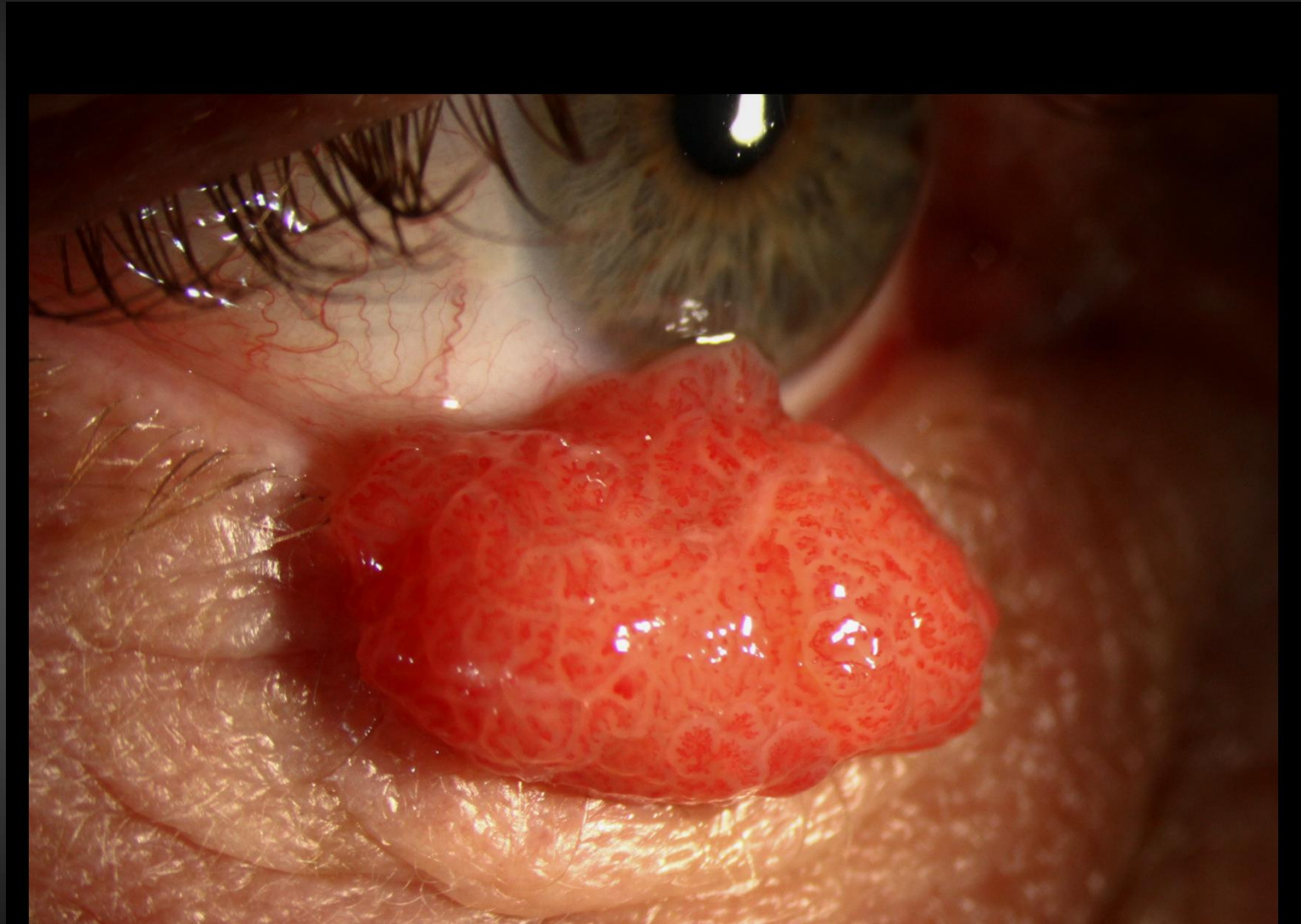
# External Photography

## Honorable Mention

Nicole Radunzel, CRA

Dr. Sales

Conjunctival Papilloma



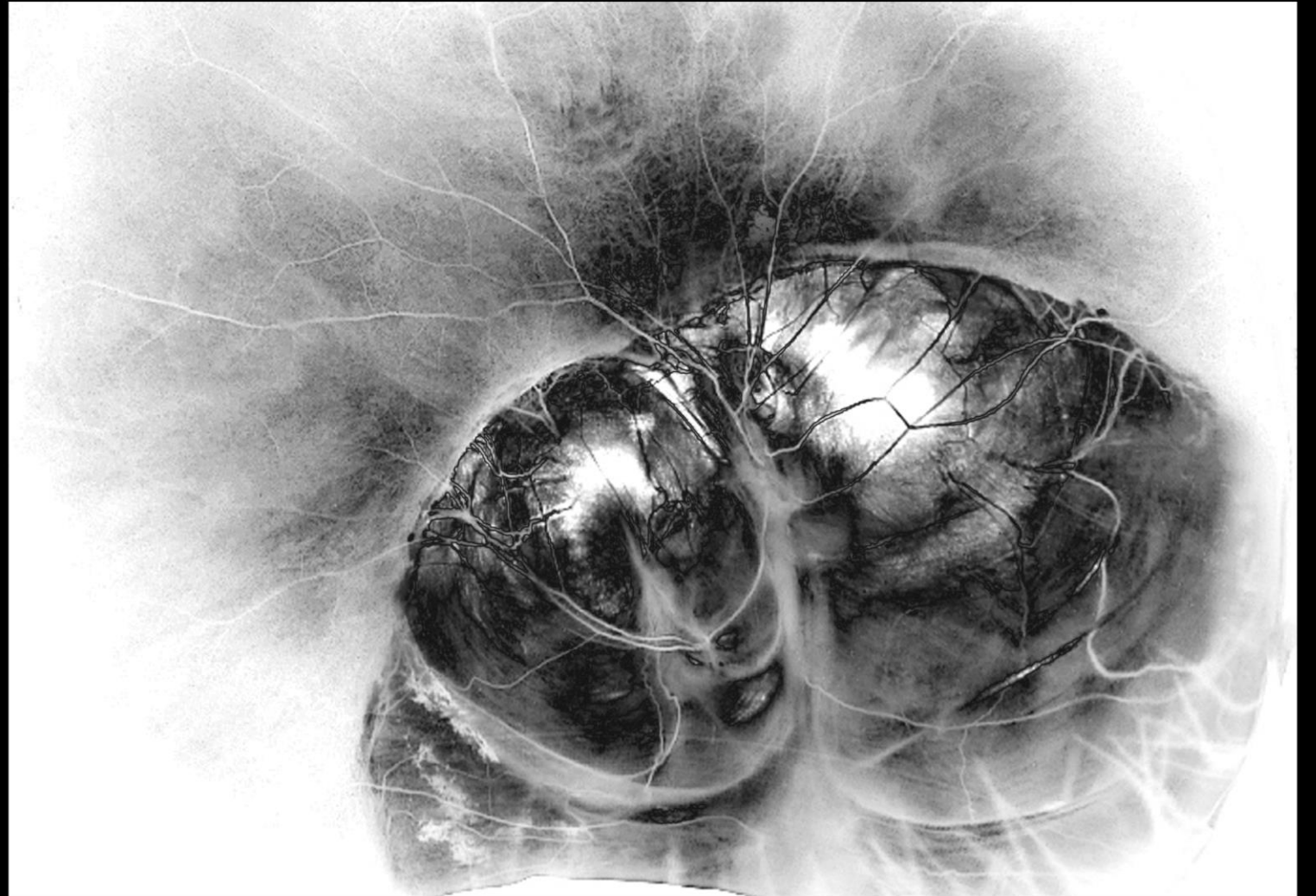
# The Eye as Art

Honorable Mention

Jody Troyer, CRA

Dr. Binkley

Coloboma



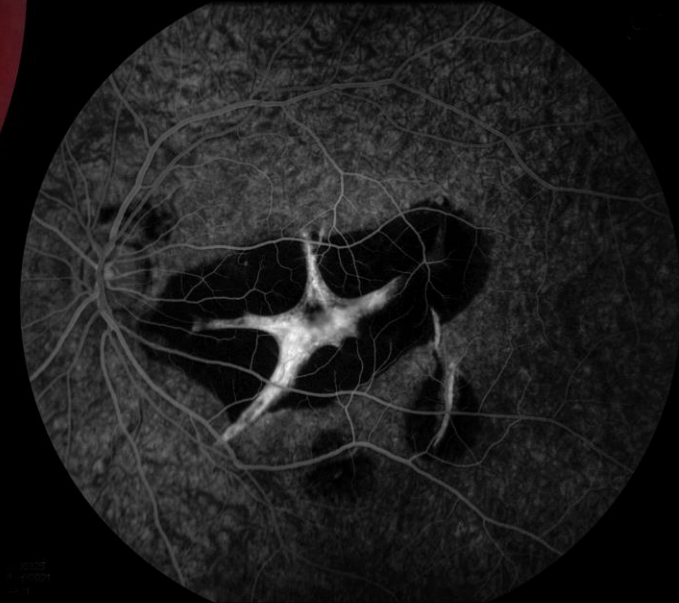
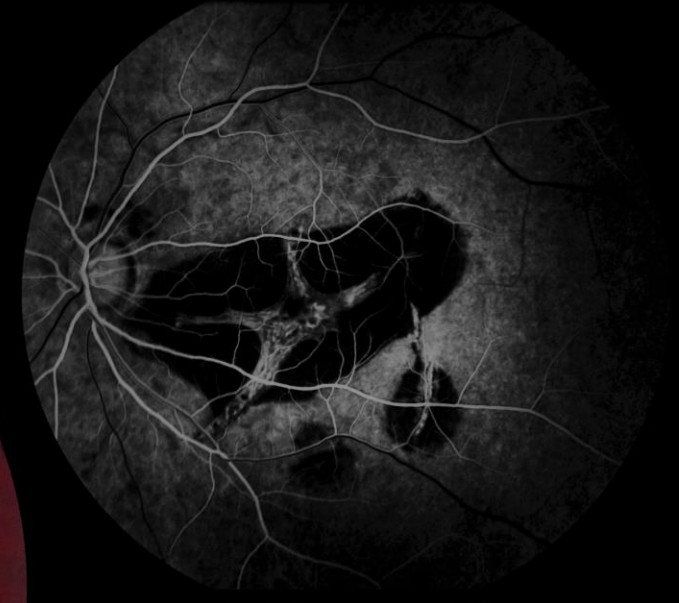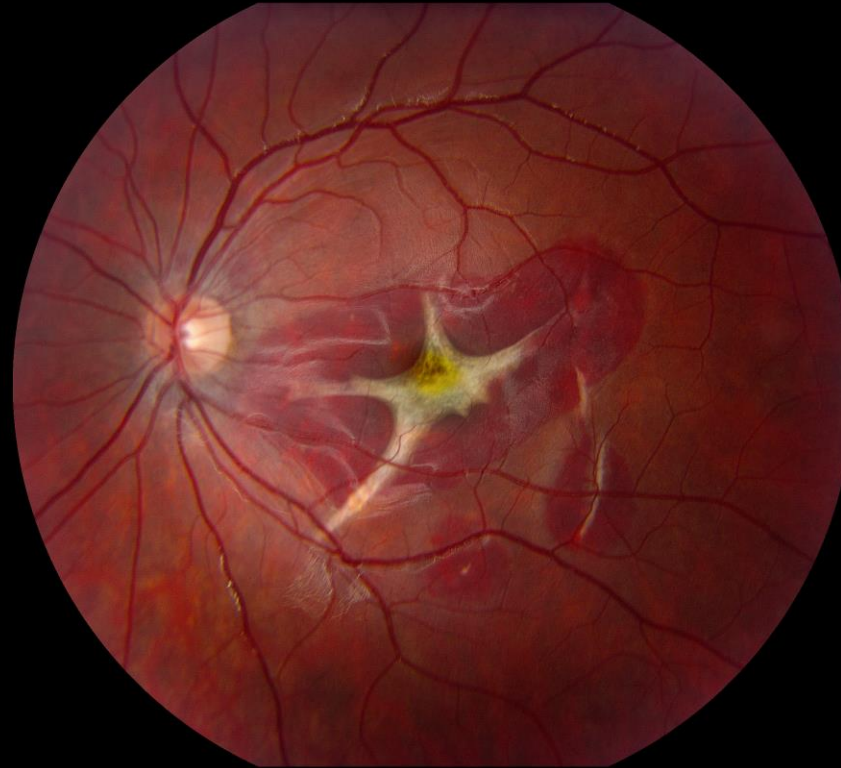
# Cross Categories

## Honorable Mention

Nicole Radunzel. CRA

Dr. Kemp

"Macular starfish": subretinal fibrosis  
and hemorrhage in choroidal rupture



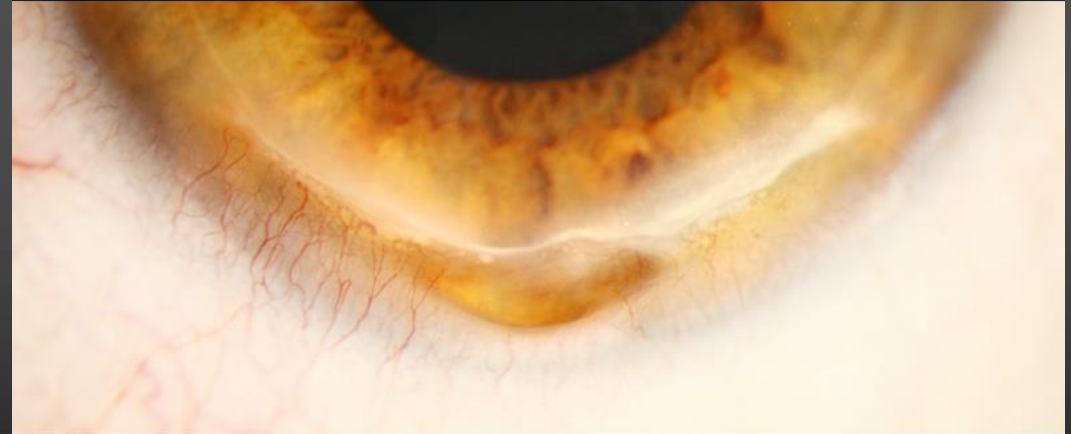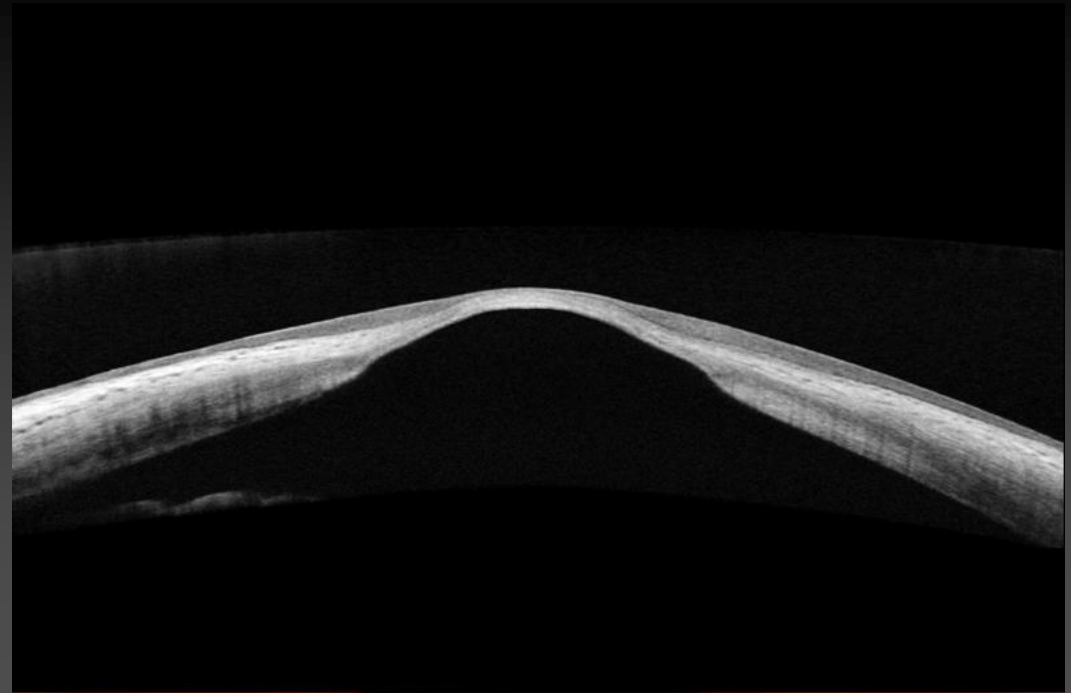
# Optical Coherence Tomography

Honorable Mention

Jody Troyer, CRA

Dr. Sales

Pellucid Marginal Degeneration of Cornea





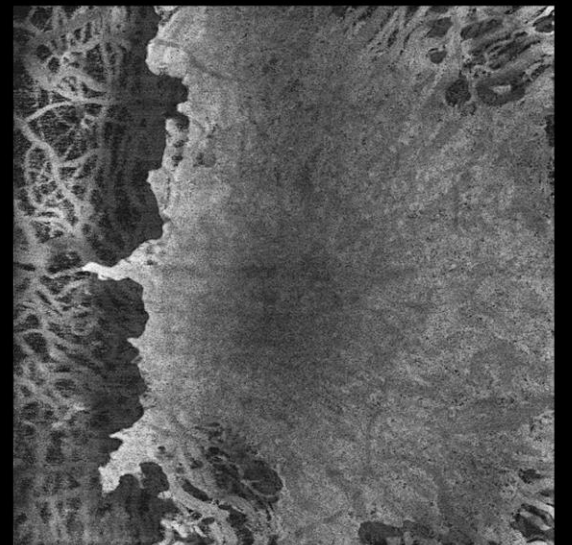
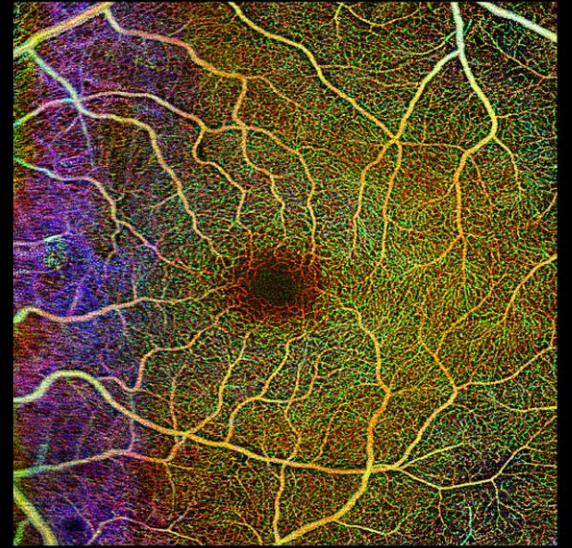
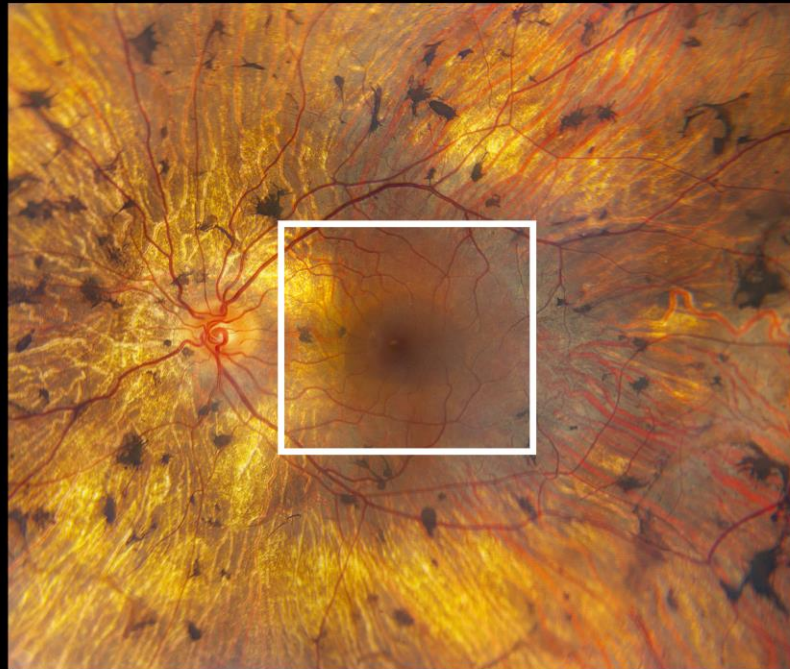
# Optical Coherence Tomography Angiography

Honorable Mention

Jody Troyer, CRA

Dr. Stone

Where the choroid ends: OCTA of  
choroideremia



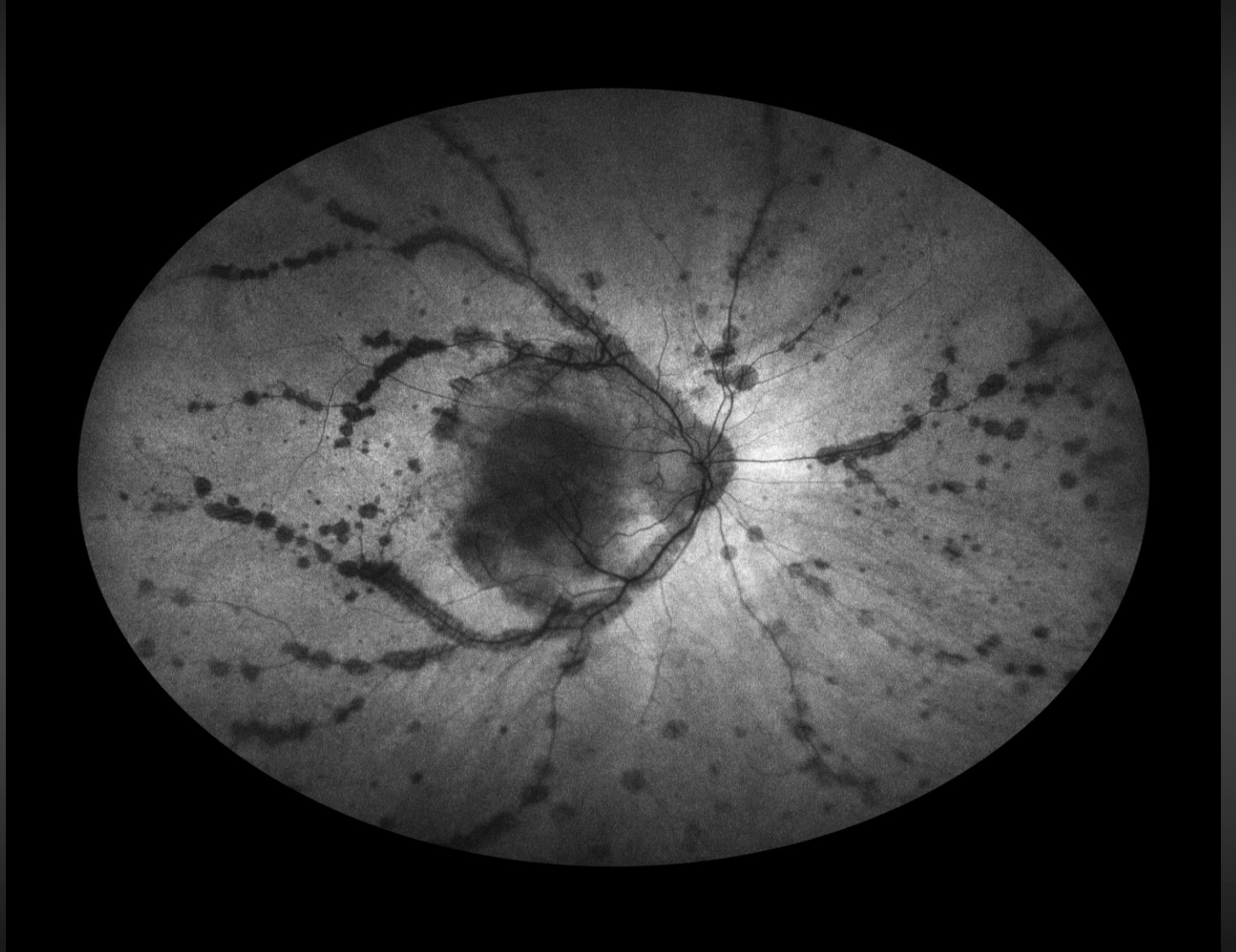
# Fundus Autofluorescence

## Honorable Mention

Sarah Skiles, CRA

Dr. Folk

Nummular perivascular hypofluorescence  
in multifocal choroiditis



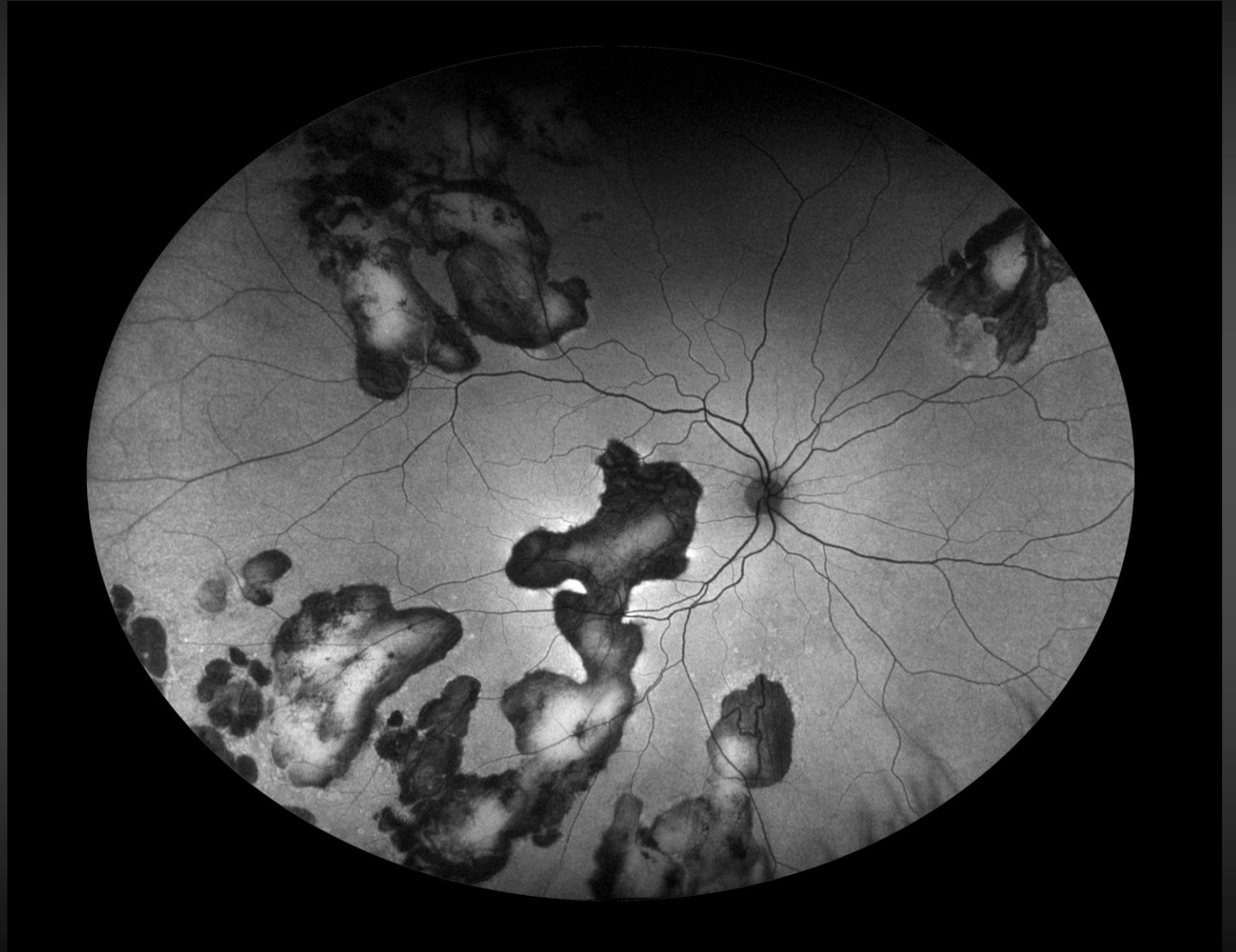
# Fundus Autofluorescence

## Honorable Mention

Sarah Skiles, CRA

Dr. Folk

"Inkblots" of scarring in serpiginous  
choroiditis



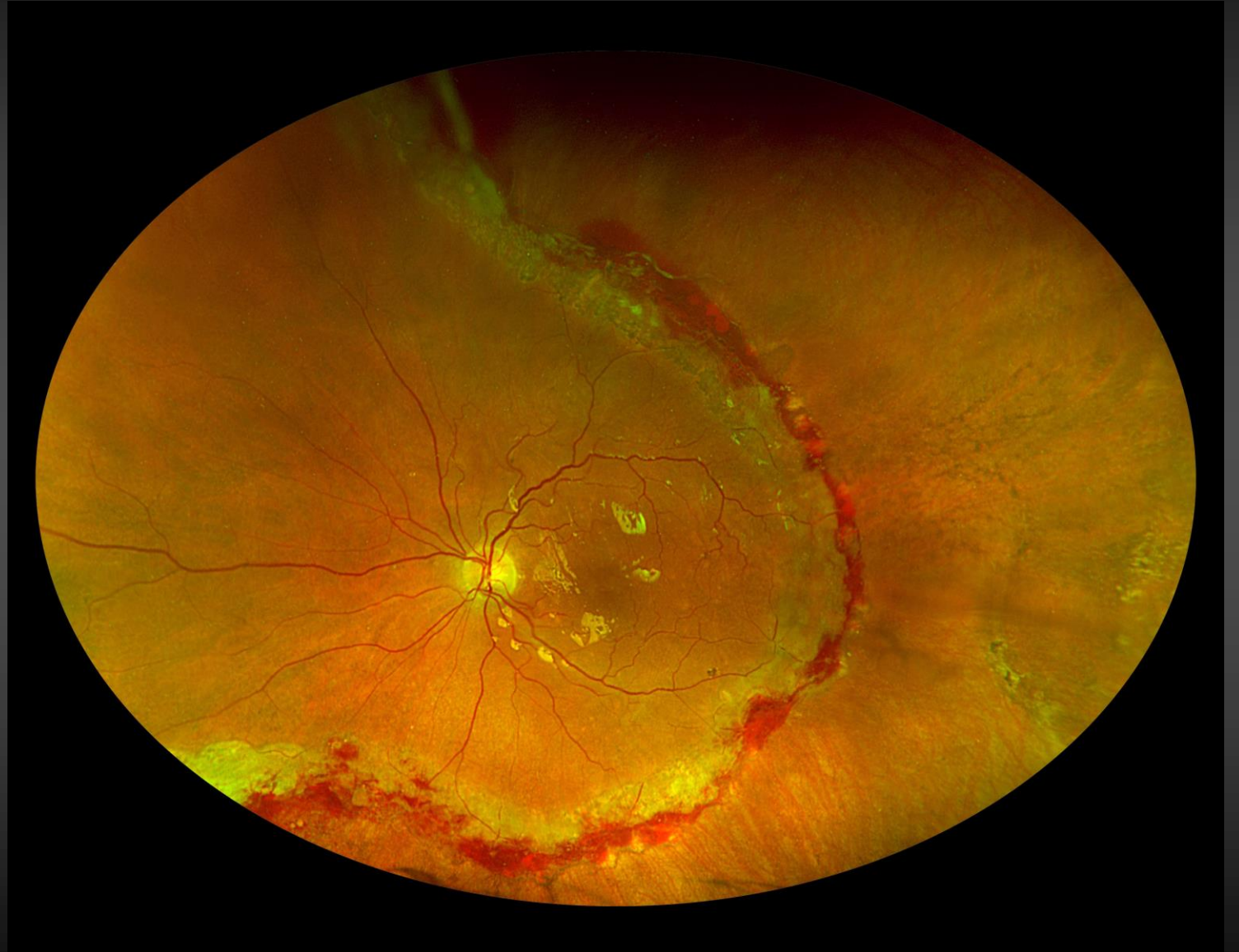# Ultra-widefield Imaging

## Honorable Mention

Sarah Skiles, CRA

Dr. J. Russell

Healing retinectomy edge after  
schisis-detachment repair



# Instrumentation

## Honorable Mention

Sarah Skiles, CRA

Dr. Sindt

Unusual Contact Lens



Video – Honorable Mention

Sarah Skiles, CRA

Dr. Sears  
Iris Lesion

